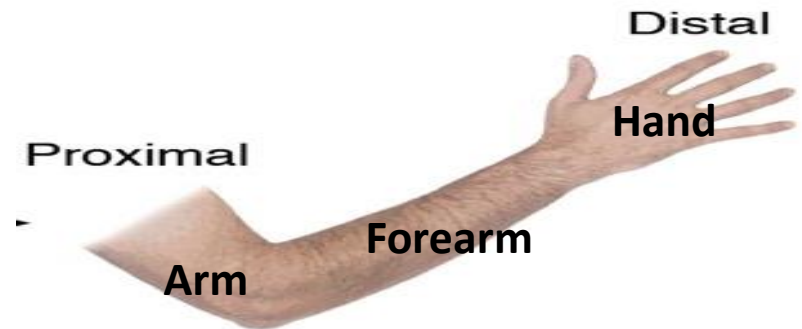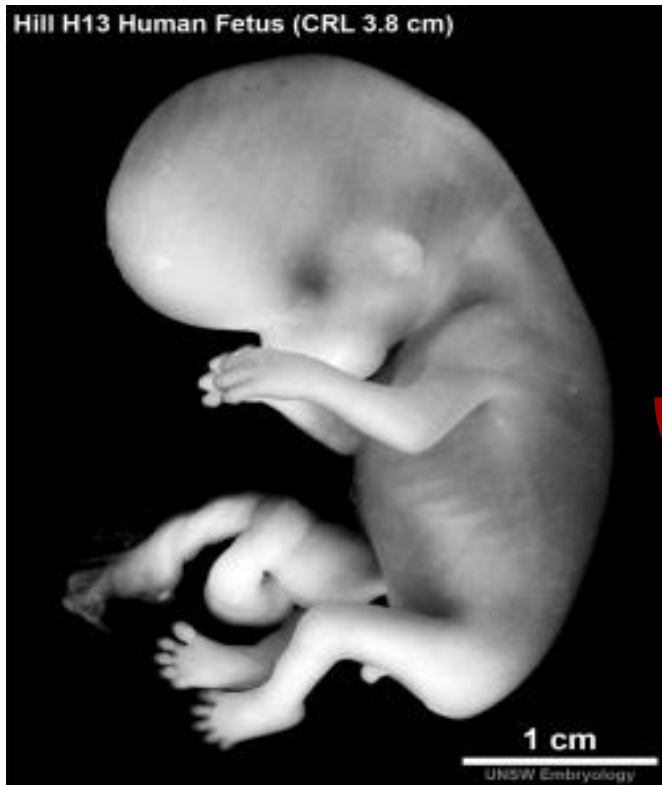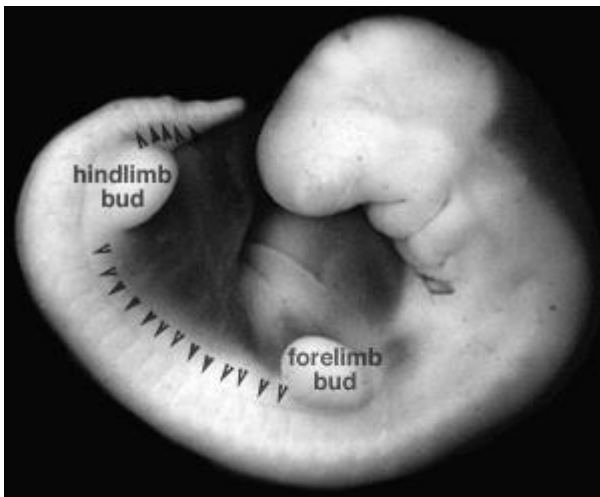
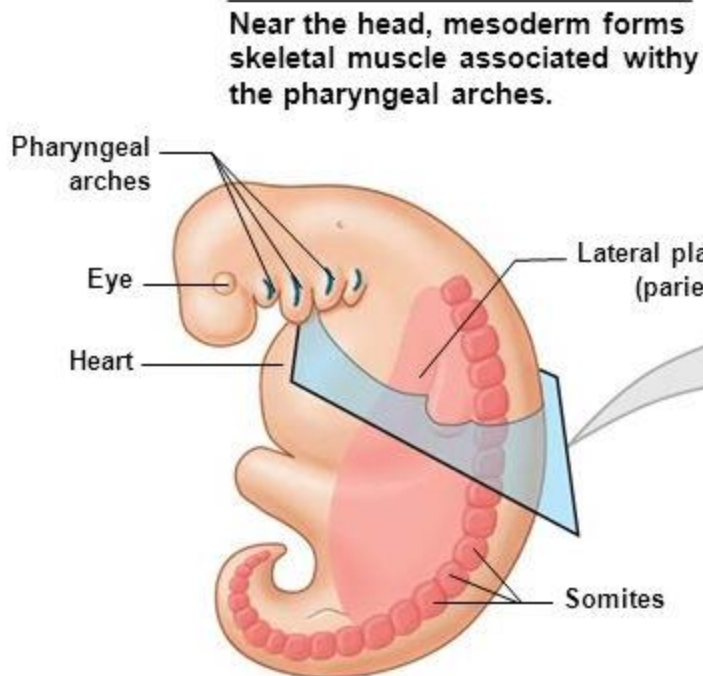
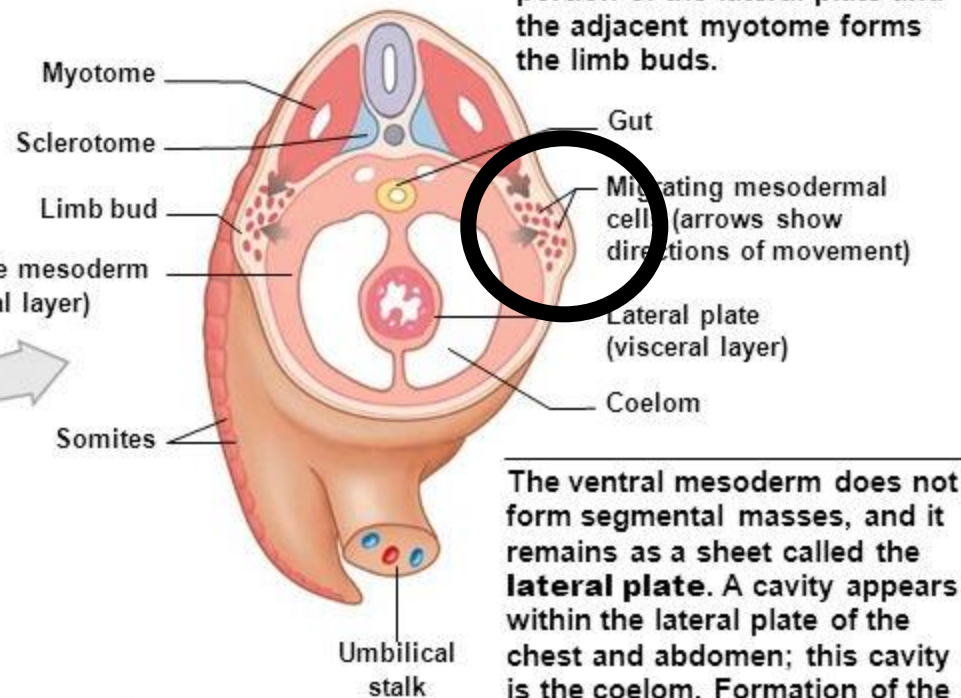


LECTURE [1] Limb Development



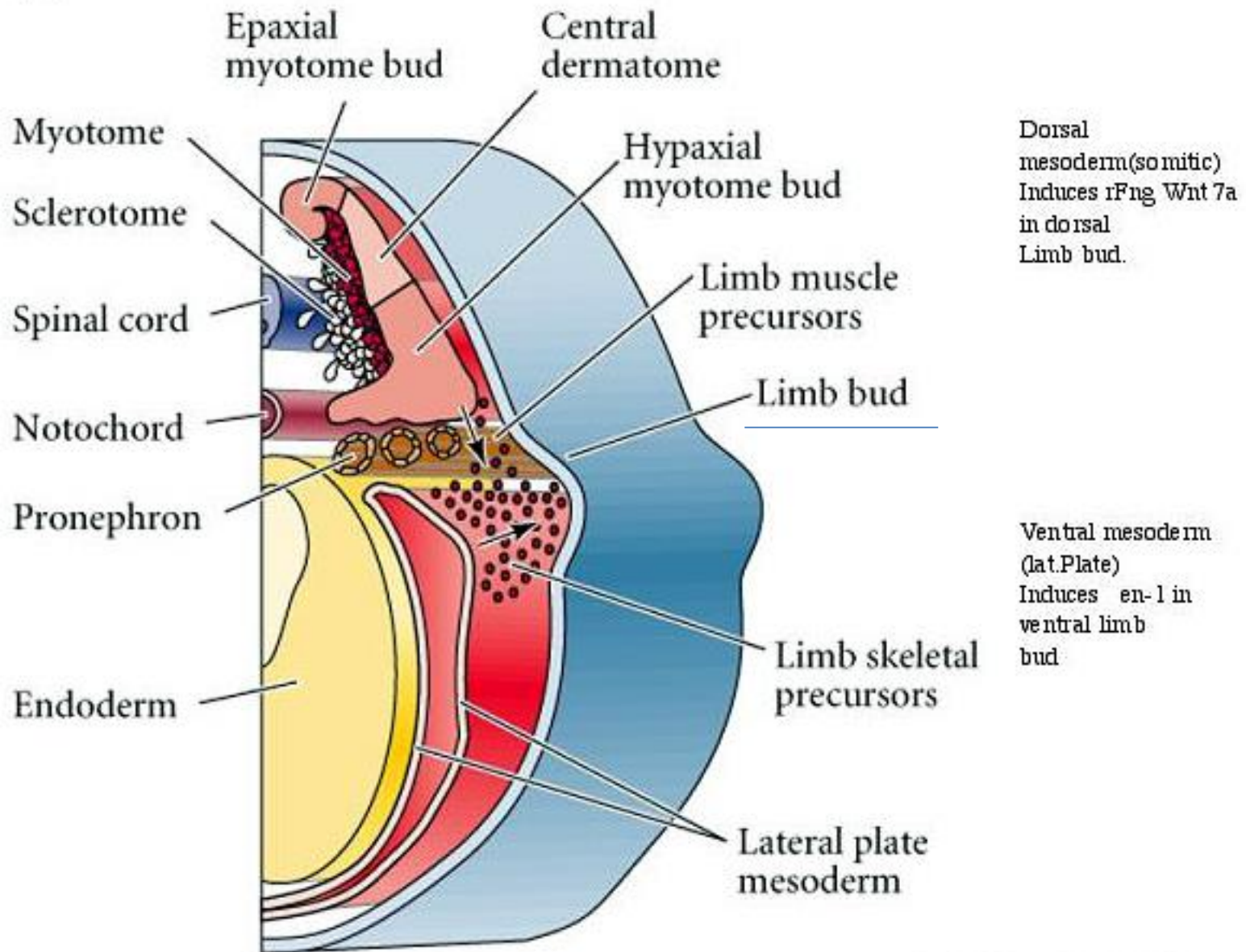


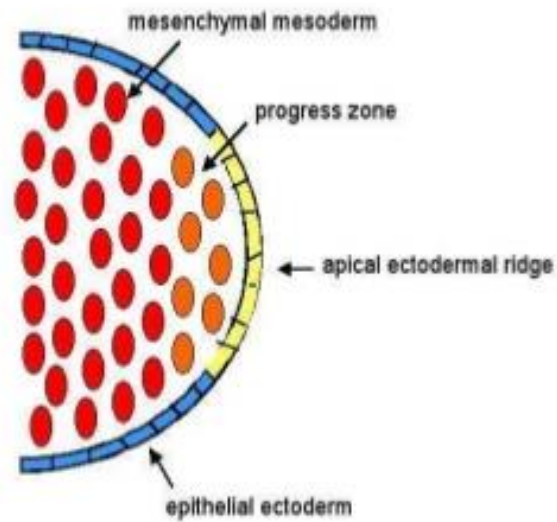
After 4 weeks of development, mesoderm on either side of the notochord has formed somites. The medial portion of each somite will form skeletal muscles; this region is called the **myotome**.



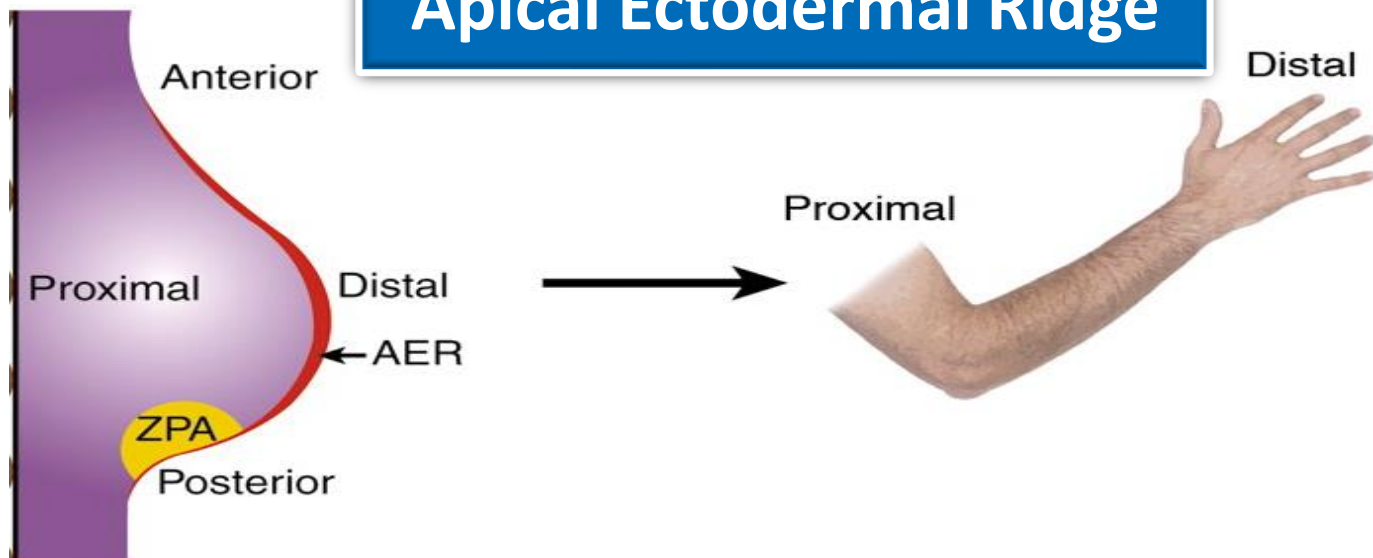
The ventral mesoderm does not form segmental masses, and it remains as a sheet called the **lateral plate**. A cavity appears within the lateral plate of the chest and abdomen; this cavity is the coelom. Formation of the coelom divides the lateral plate into an inner **visceral layer** and an outer **parietal layer**.

4 WEEKS



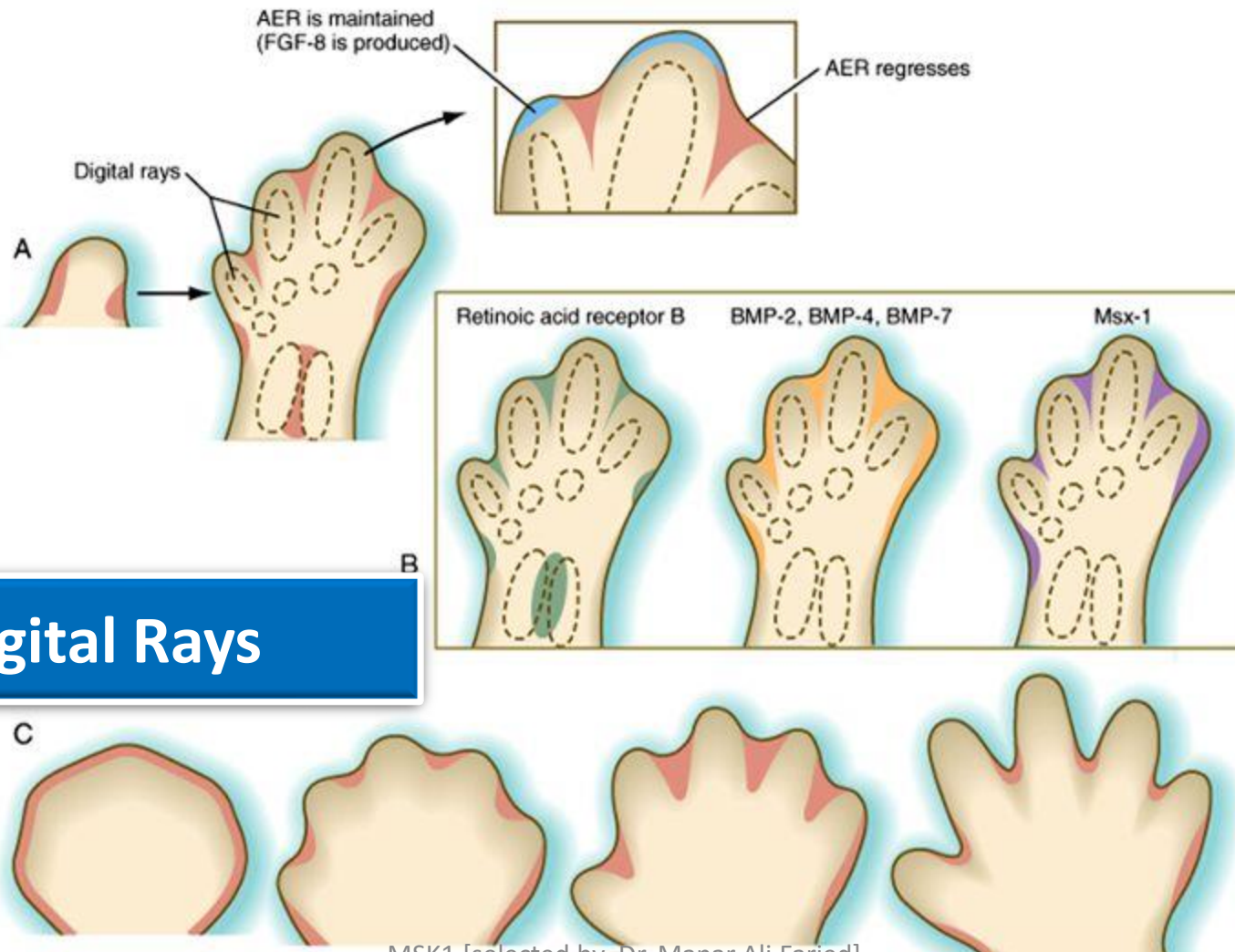


Apical Ectodermal Ridge



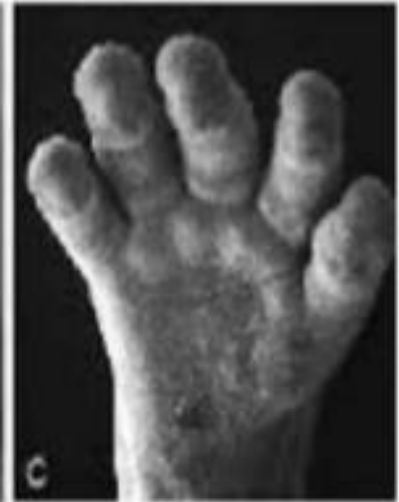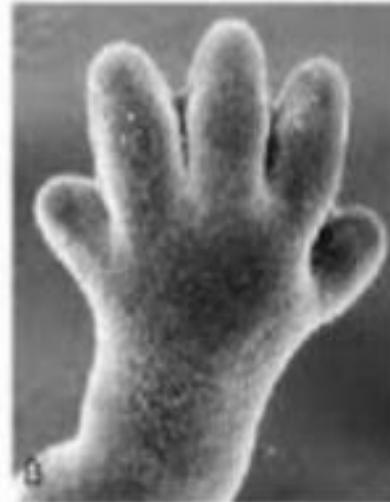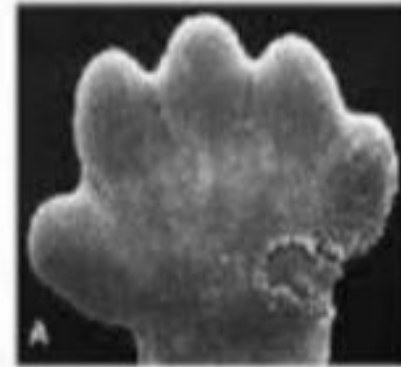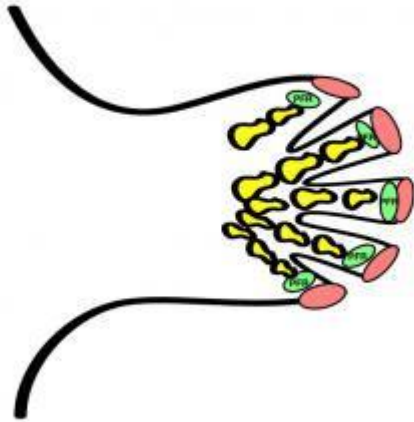
Formation of digits:

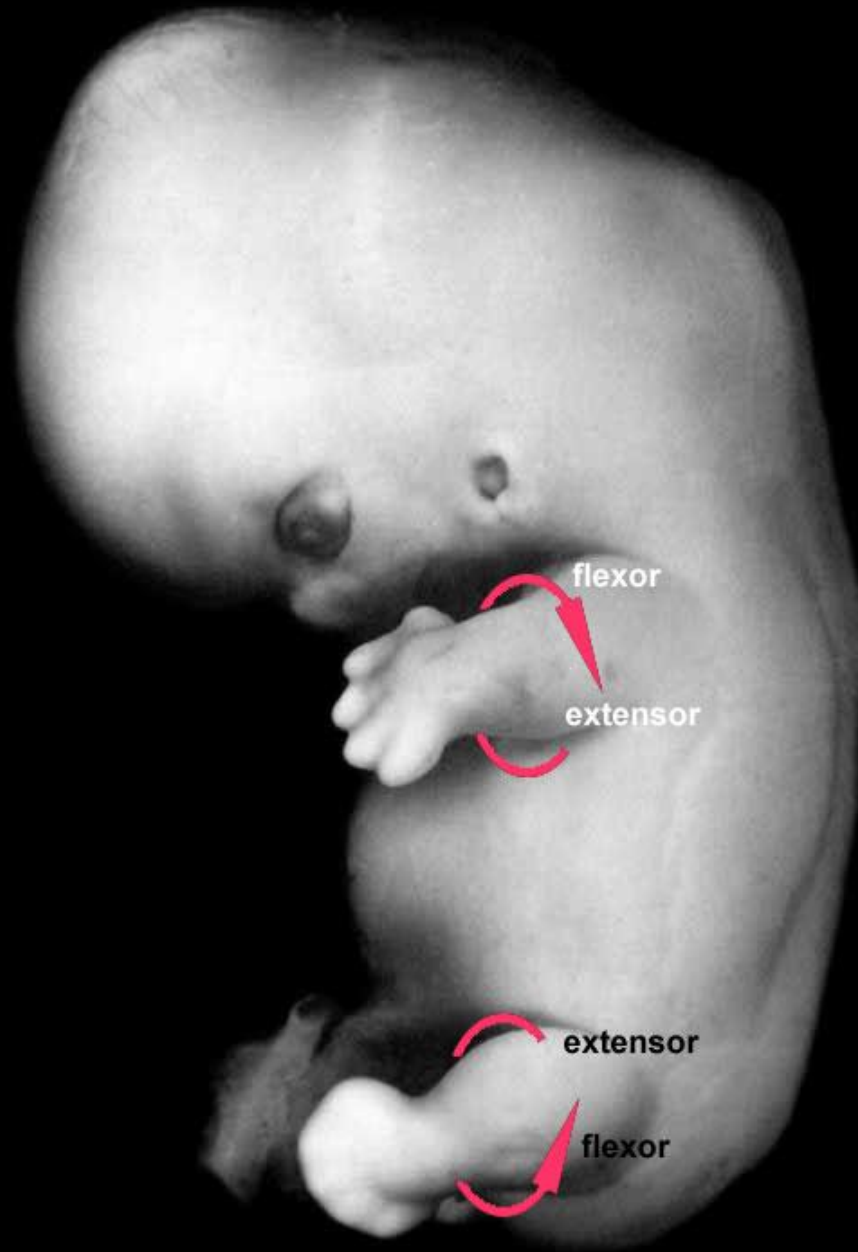
a balance between cell proliferation at AER maintained at digit tips versus cell death in interdigital regions where AER regresses.



Digital Rays

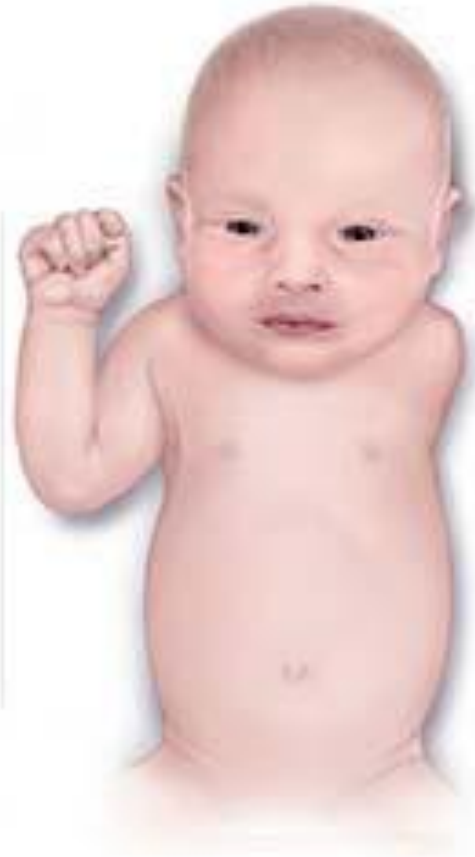Apoptosis



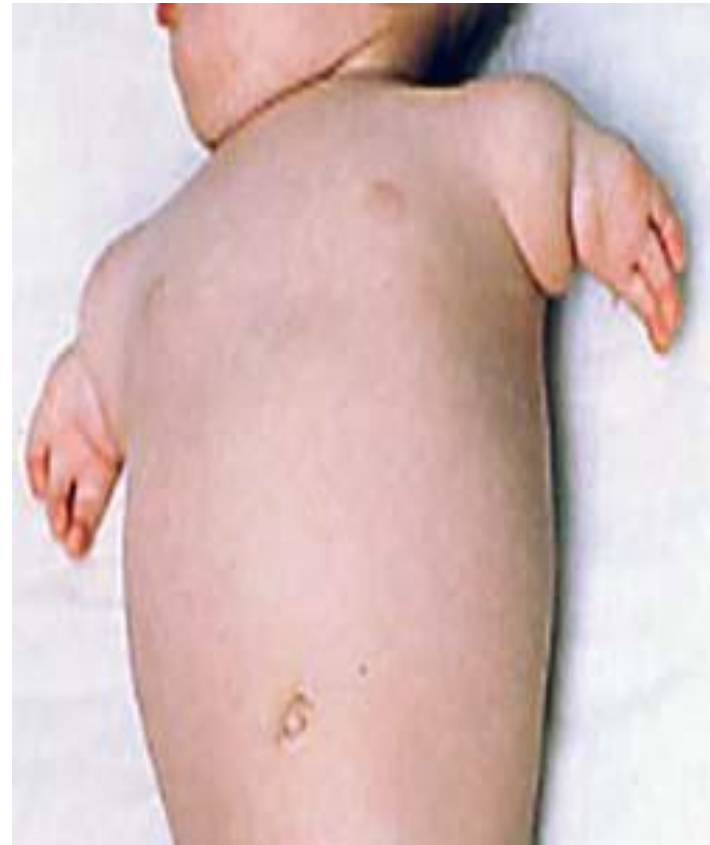

Timing

Rotation



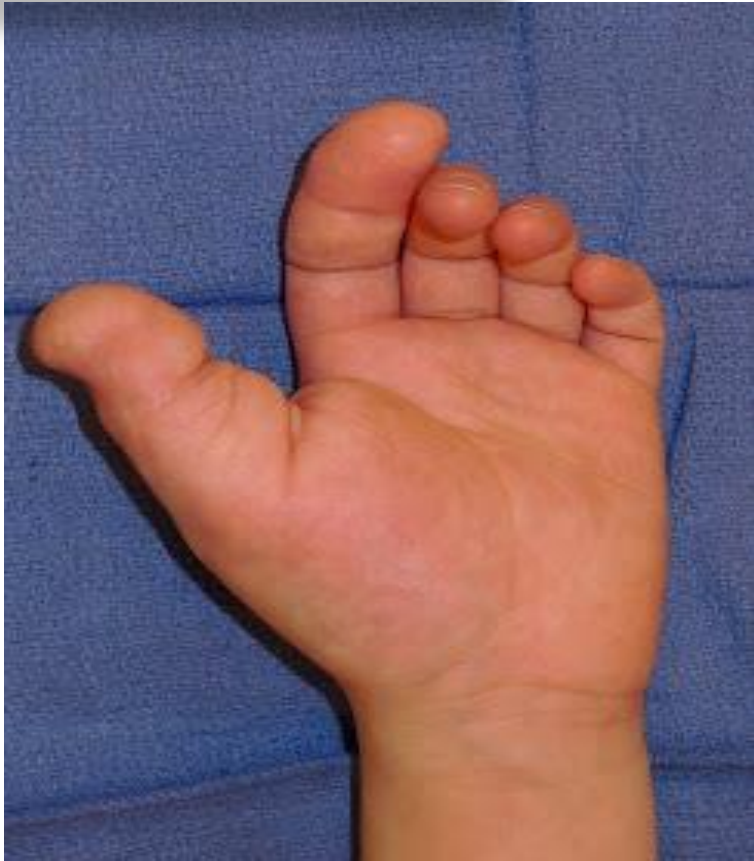Amelia



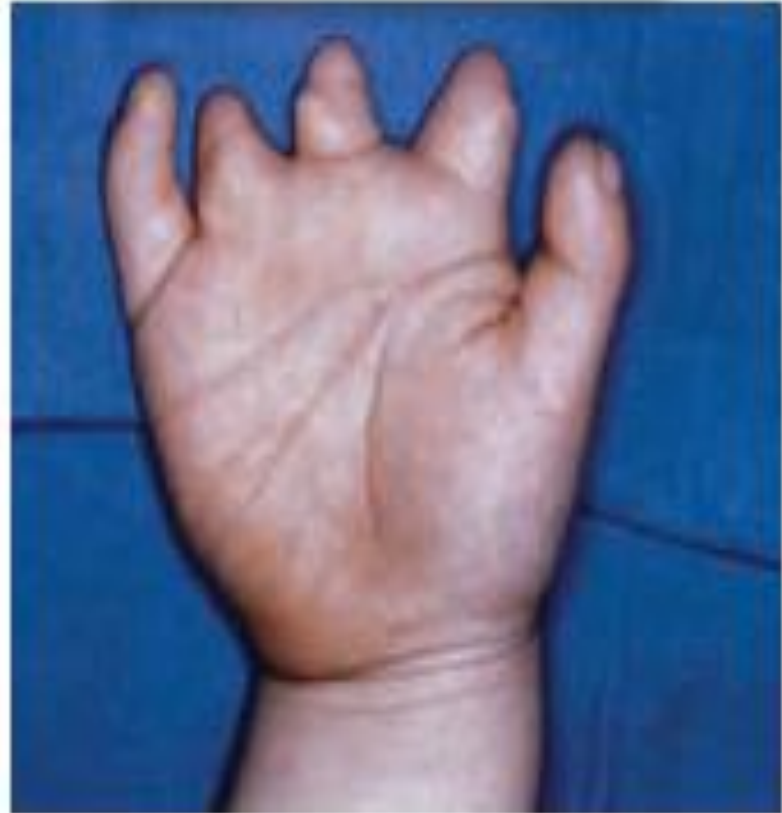Phocomelia

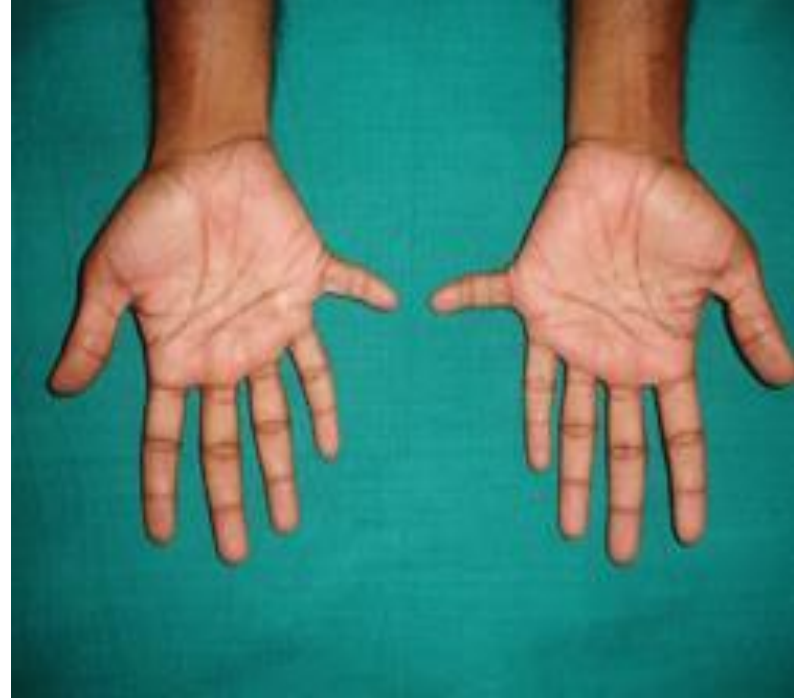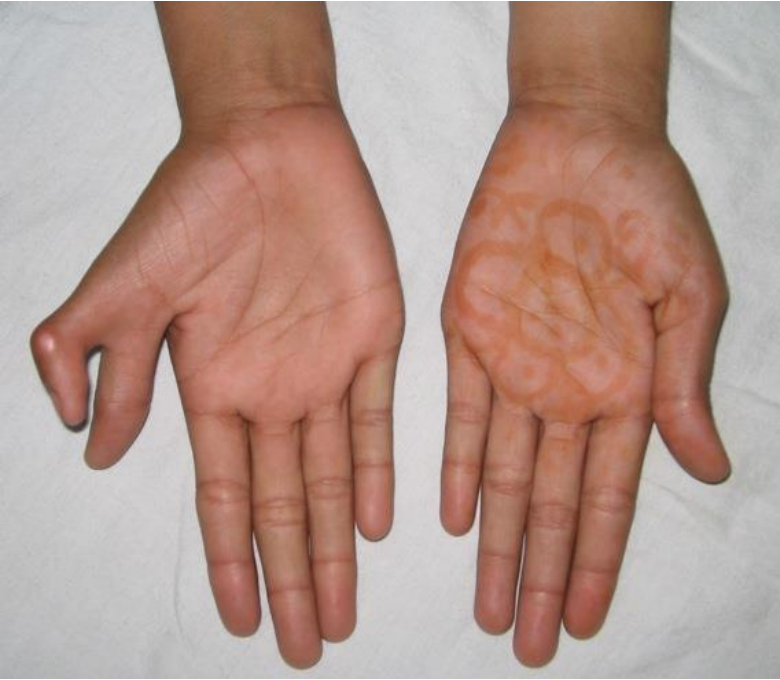Micromelia

Macroductyly



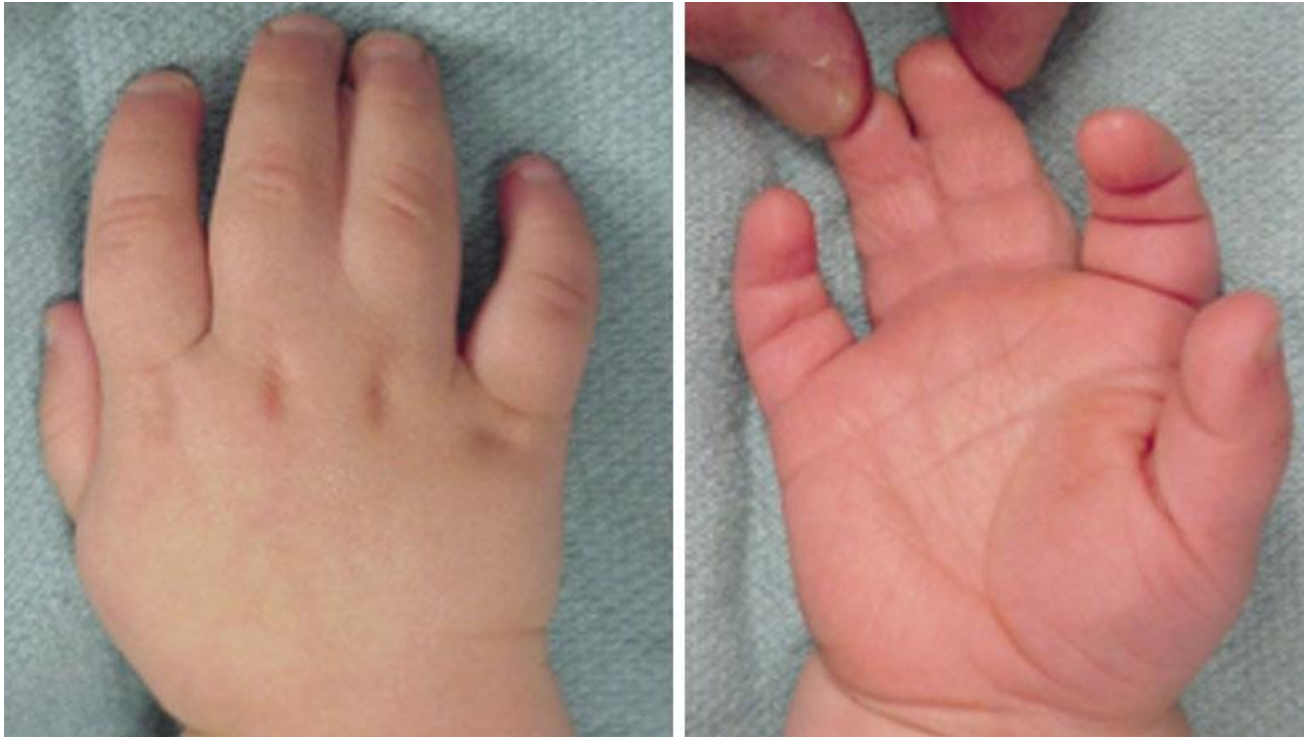Brachydactyly



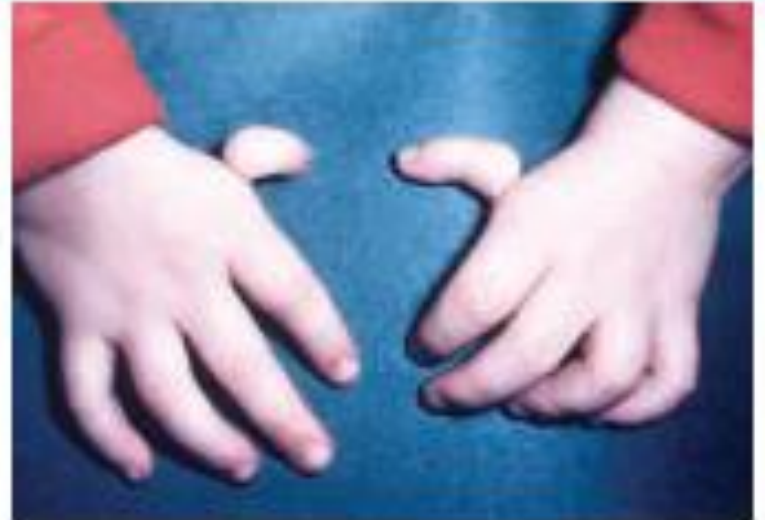
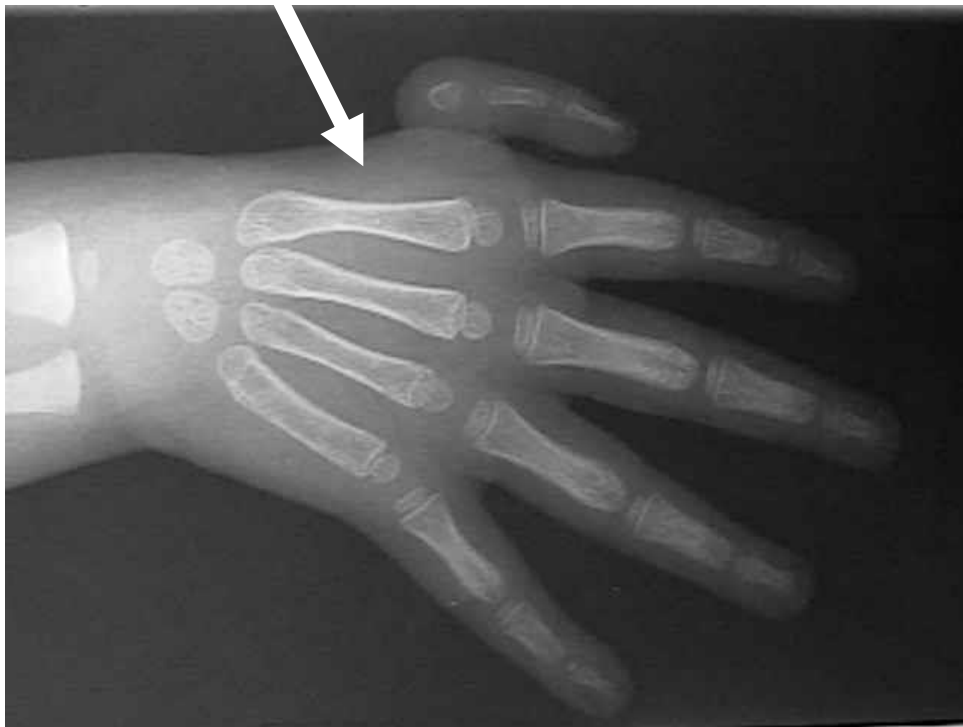
Polydactyly

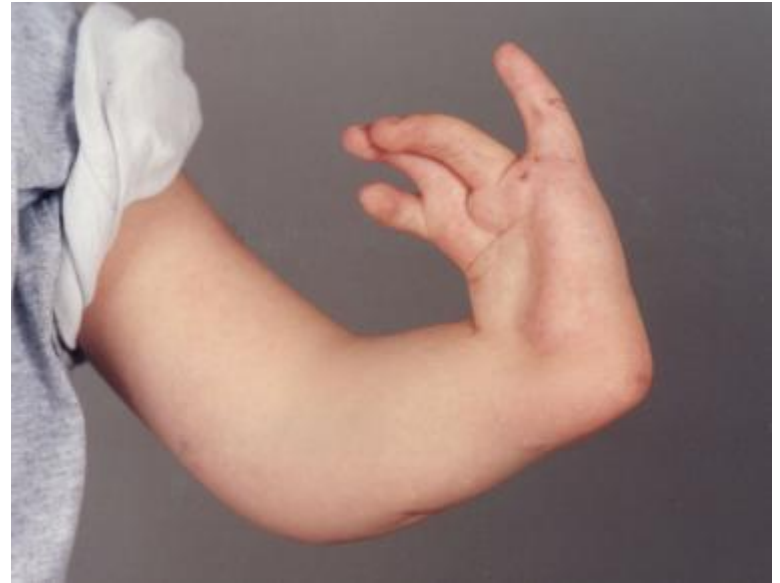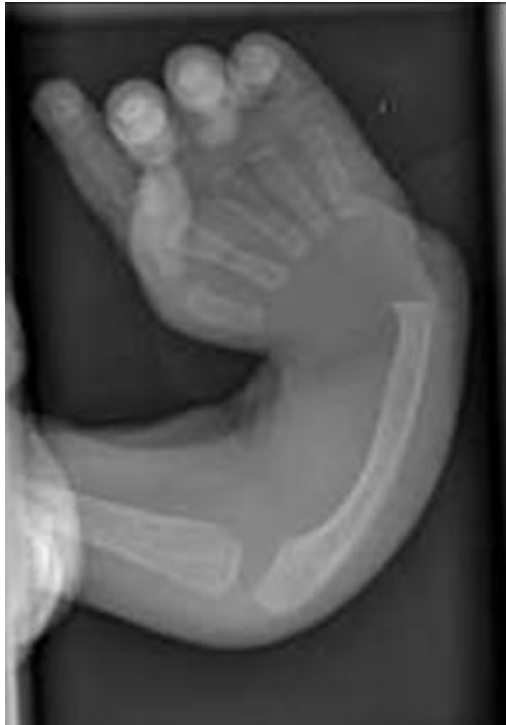Syndactyly



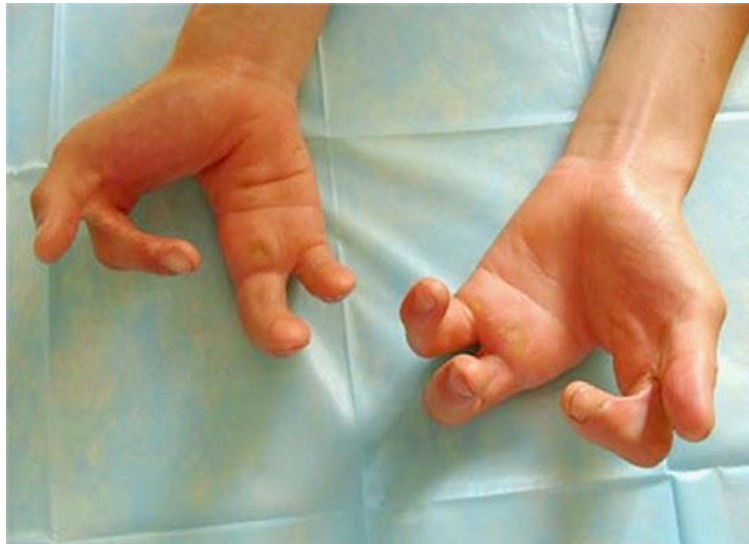Floating thumb



Congenital absent radius

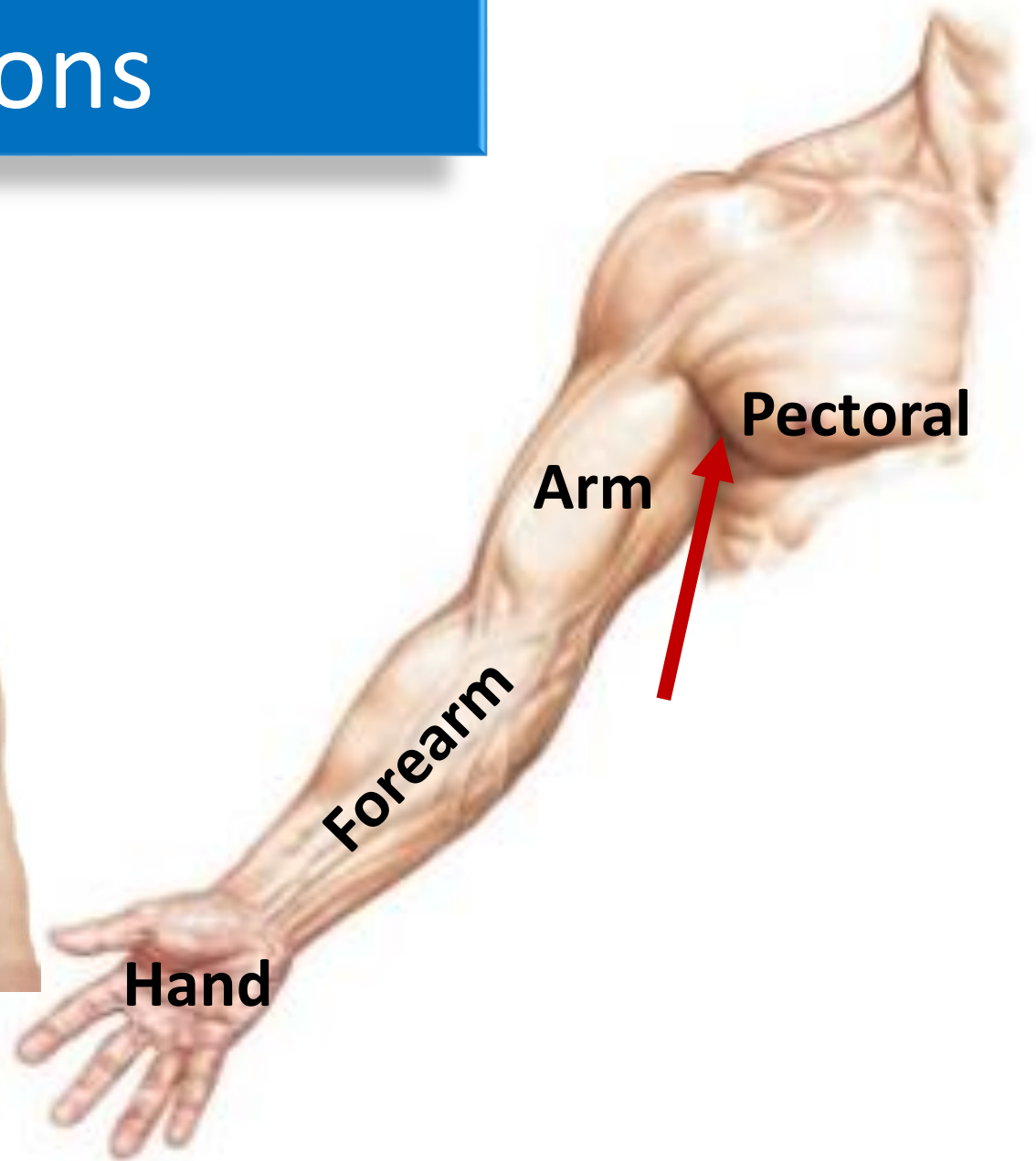
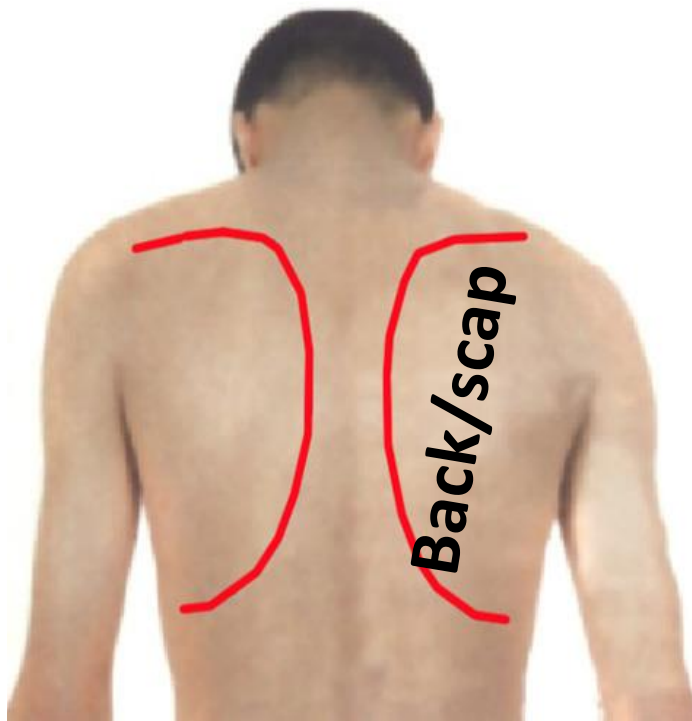

Lobster claw hand

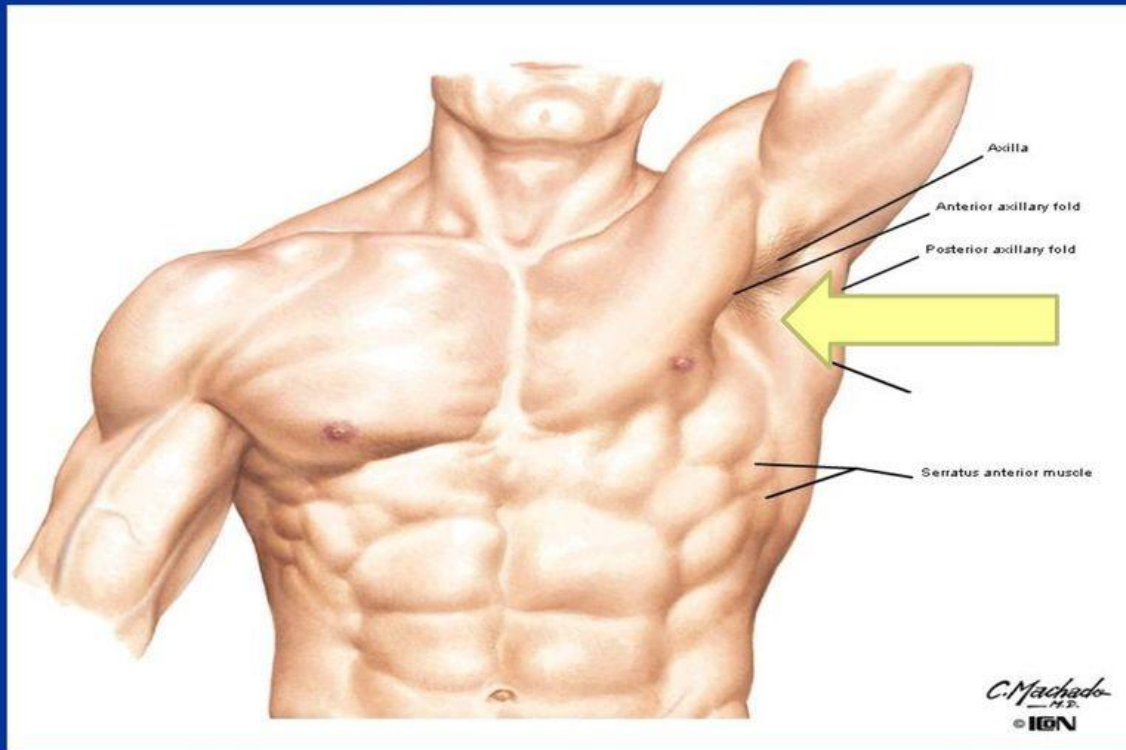


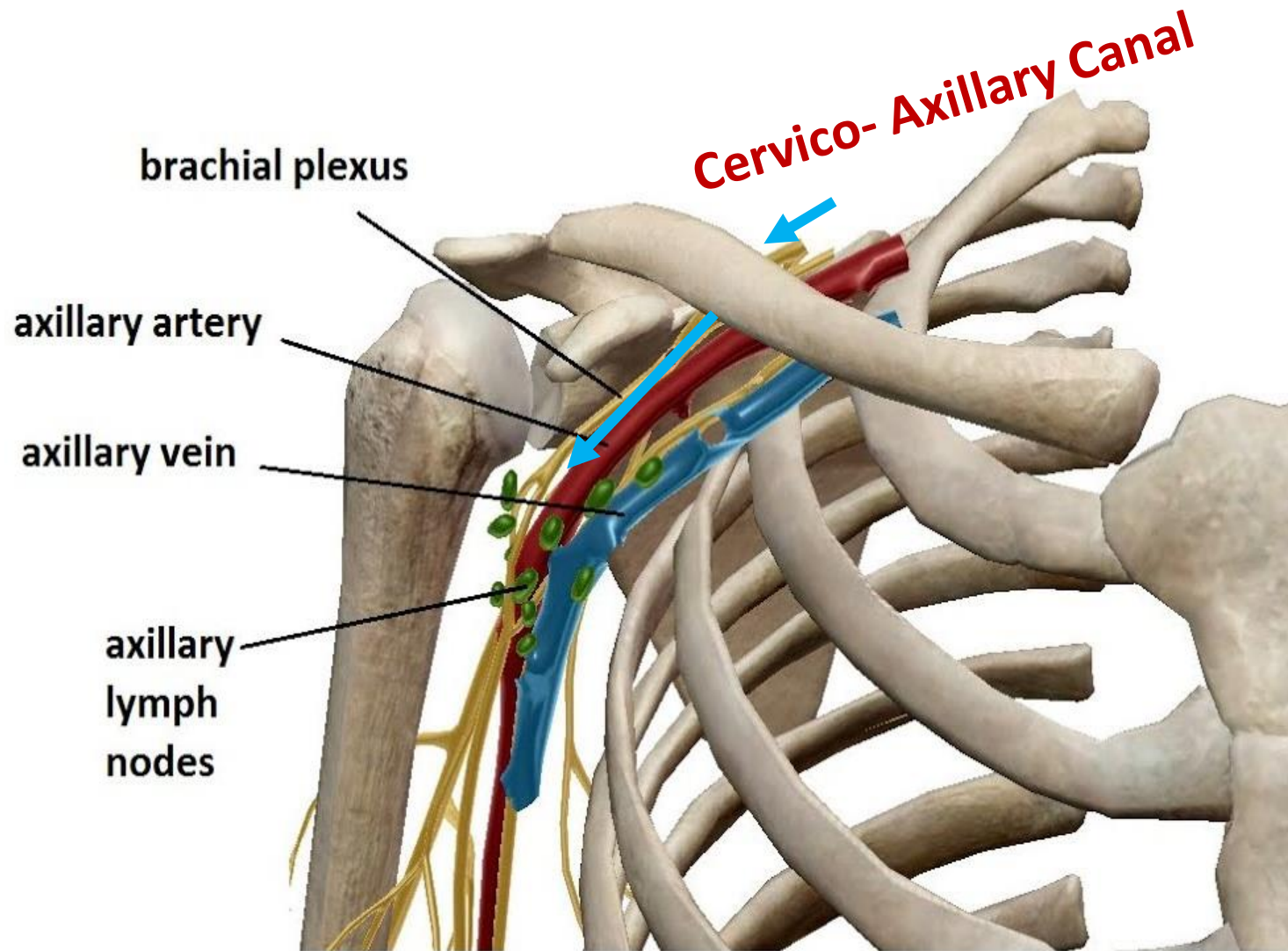
LECTURE [2]

Regions



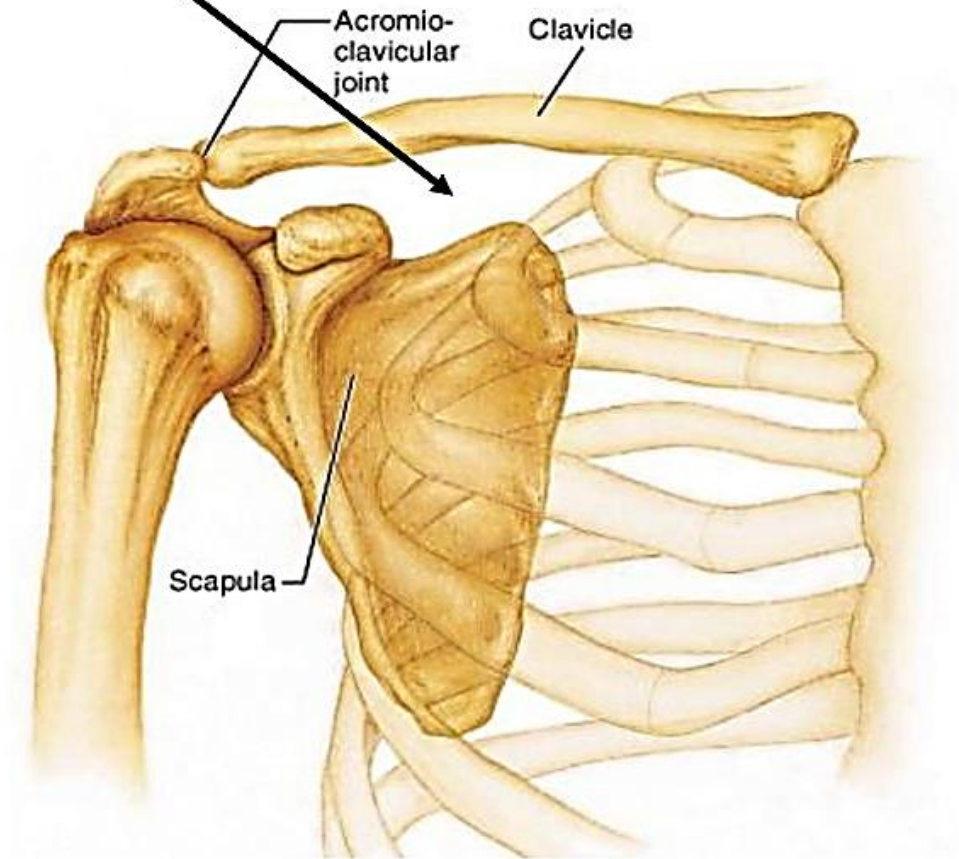
Axilla (Arm pit)



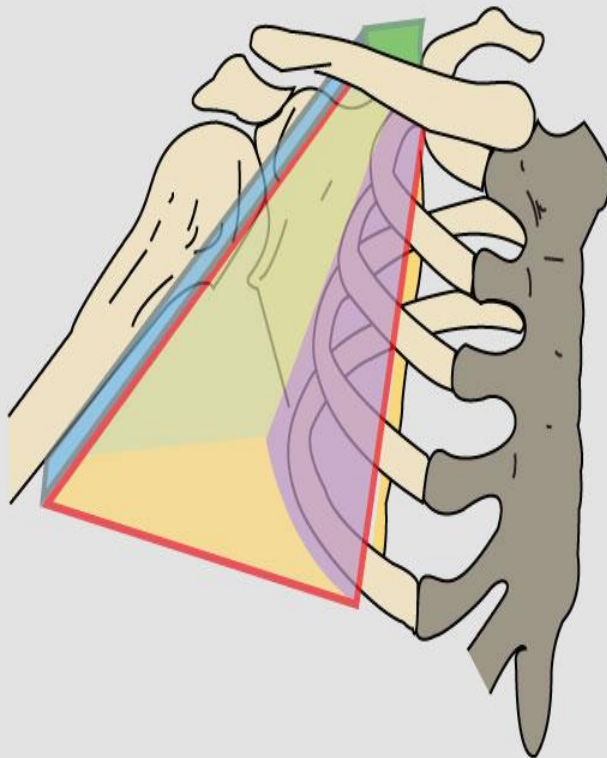


cervico axillary canal

- is bounded, by 3 bones:
 - Clavicle **anteriorly**.
 - Upper border of the scapula **posteriorly**.
 - Outer border of the first rib **medially**.
- It is called **cervico-axillary canal**.



Boundaries of axilla



a. Apex

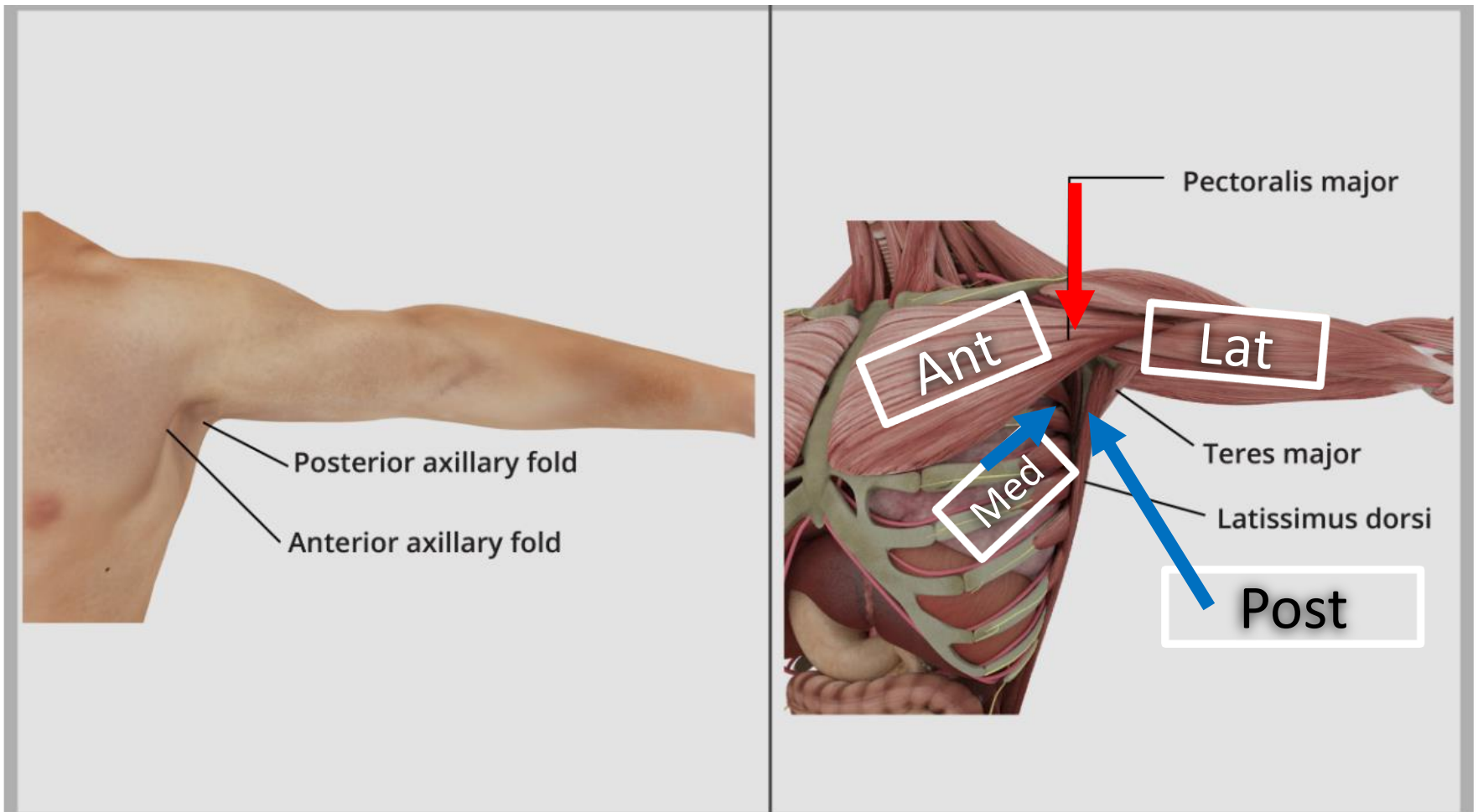
b. Base

c. Anterior wall

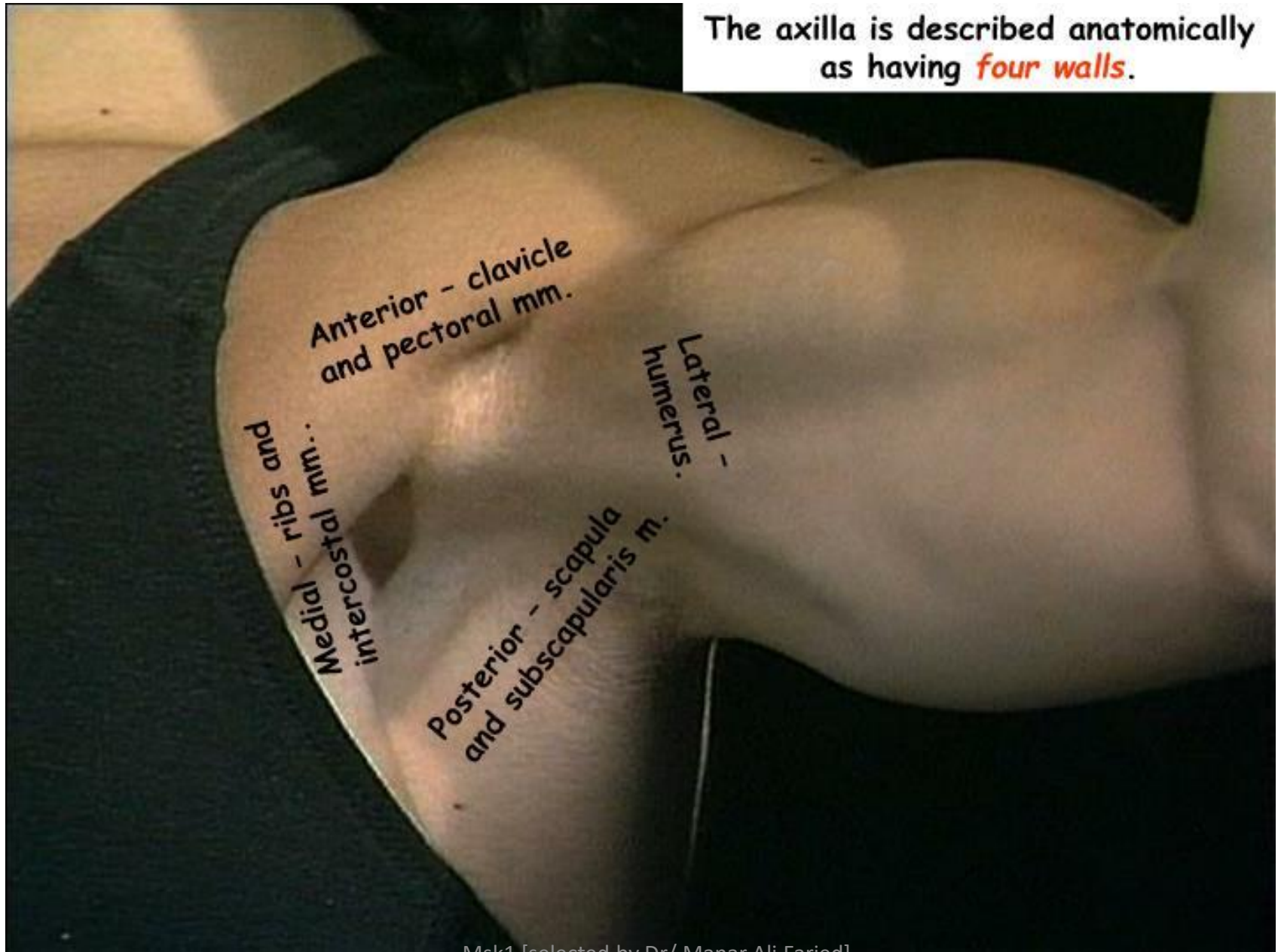
d. Posterior wall

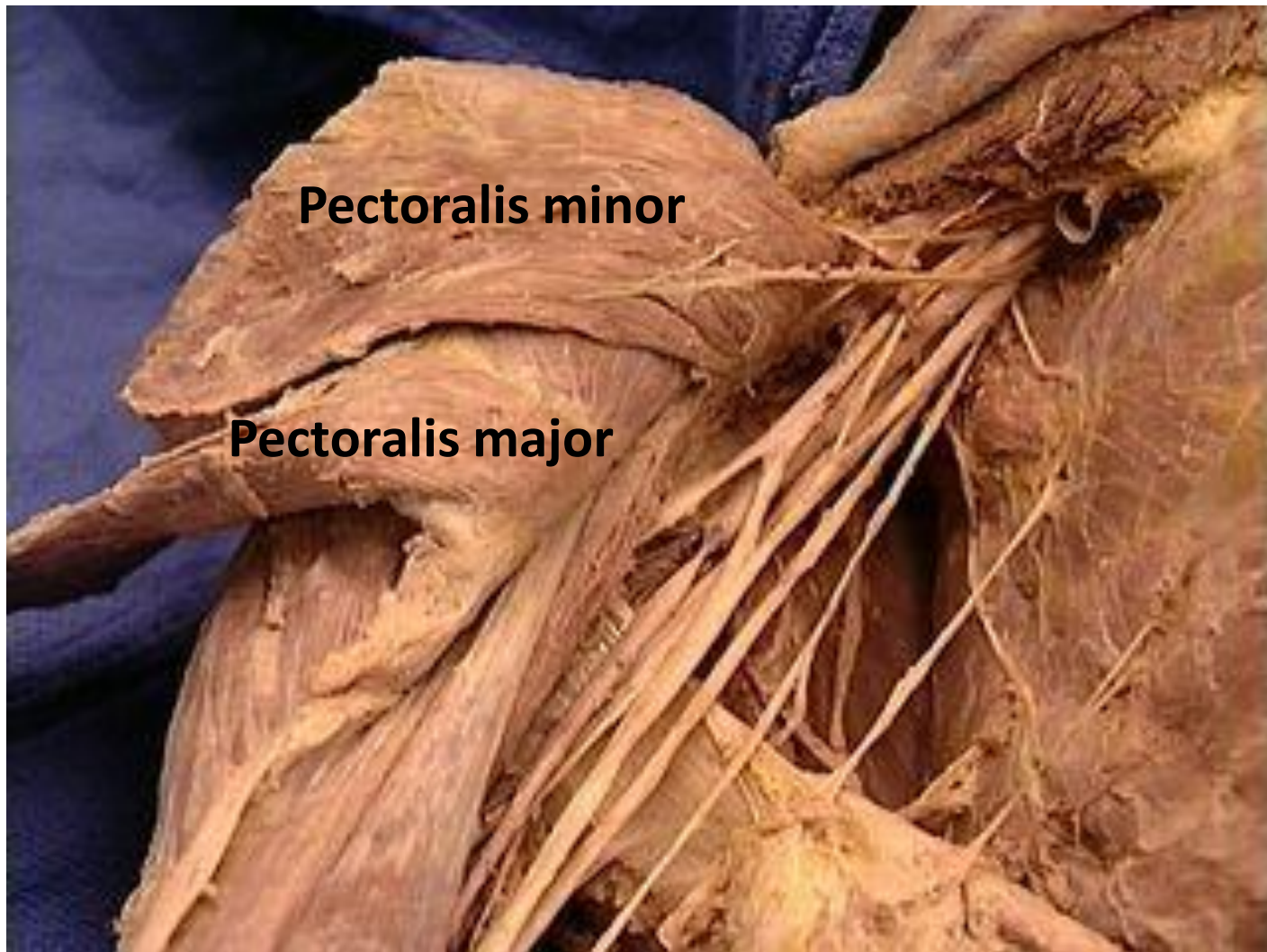
e. Medial wall

f. Lateral wall



The axilla is described anatomically as having **four walls**.

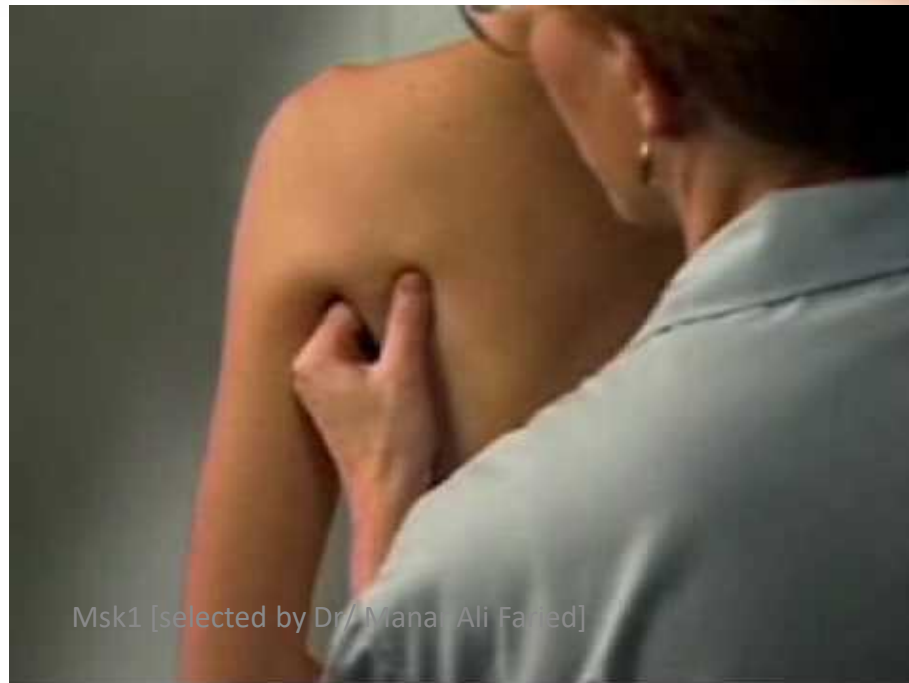
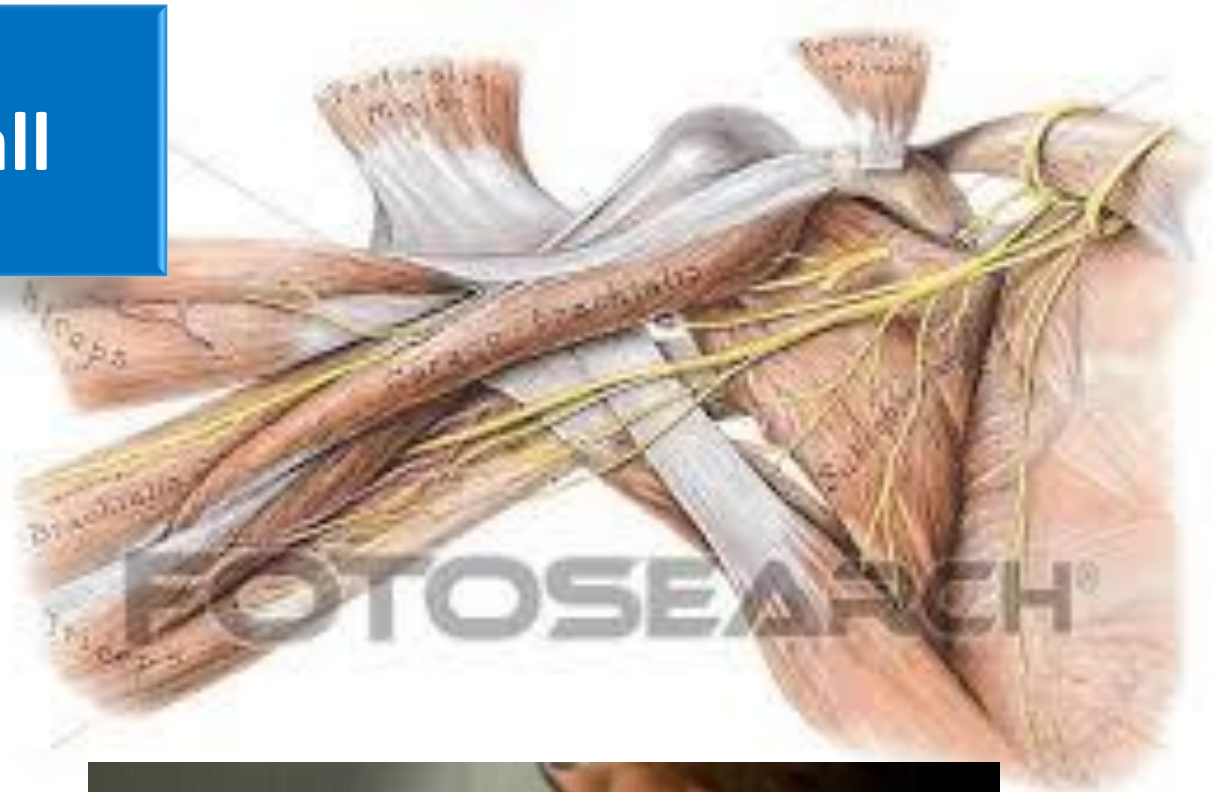


Pectoralis minor

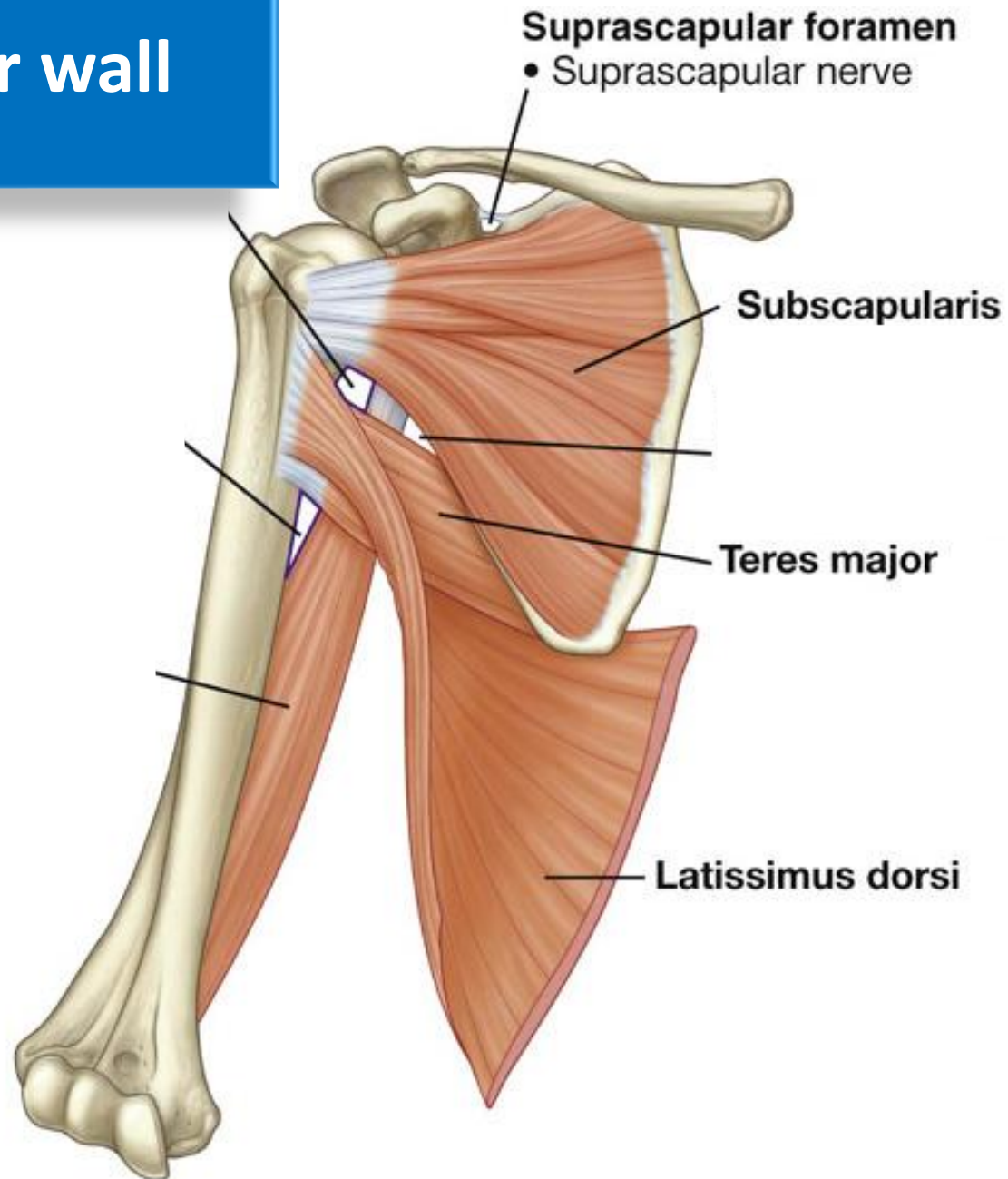
Pectoralis major

Posterior wall

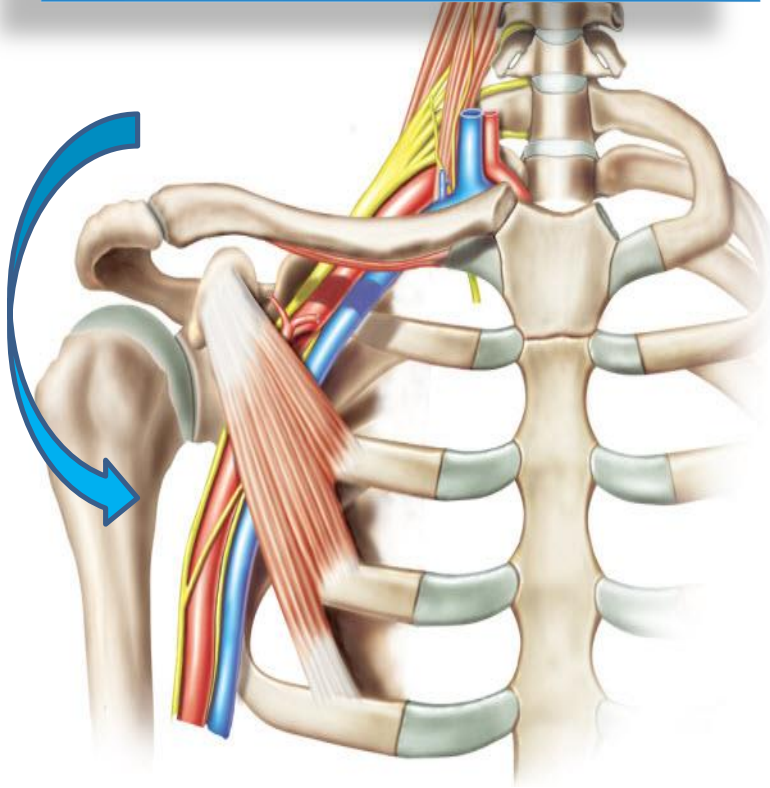


Msk1 [selected by Dr/ Manal Ali Fayed]

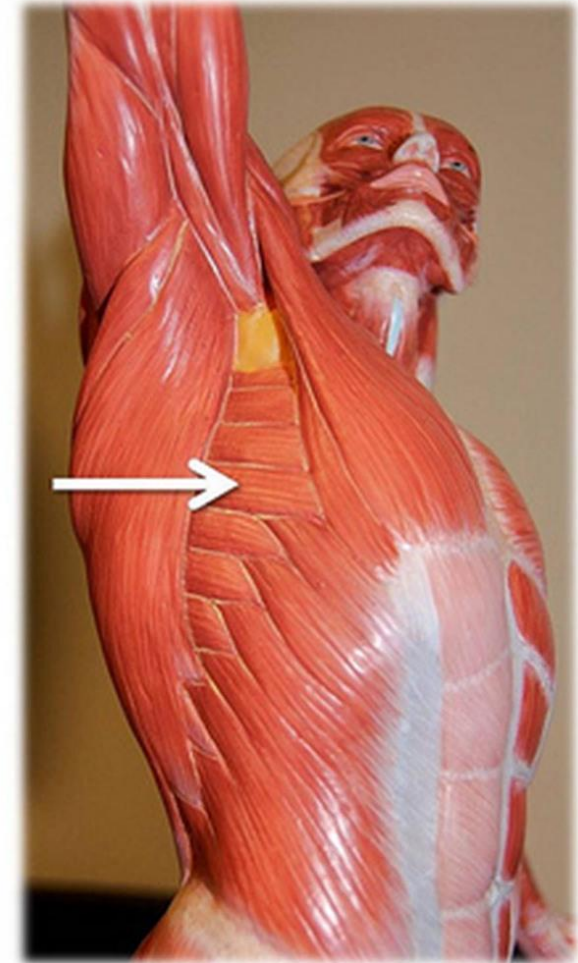
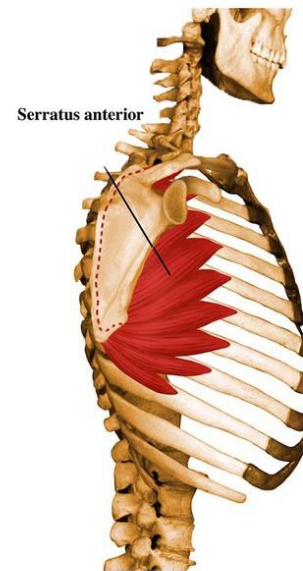
Posterior wall

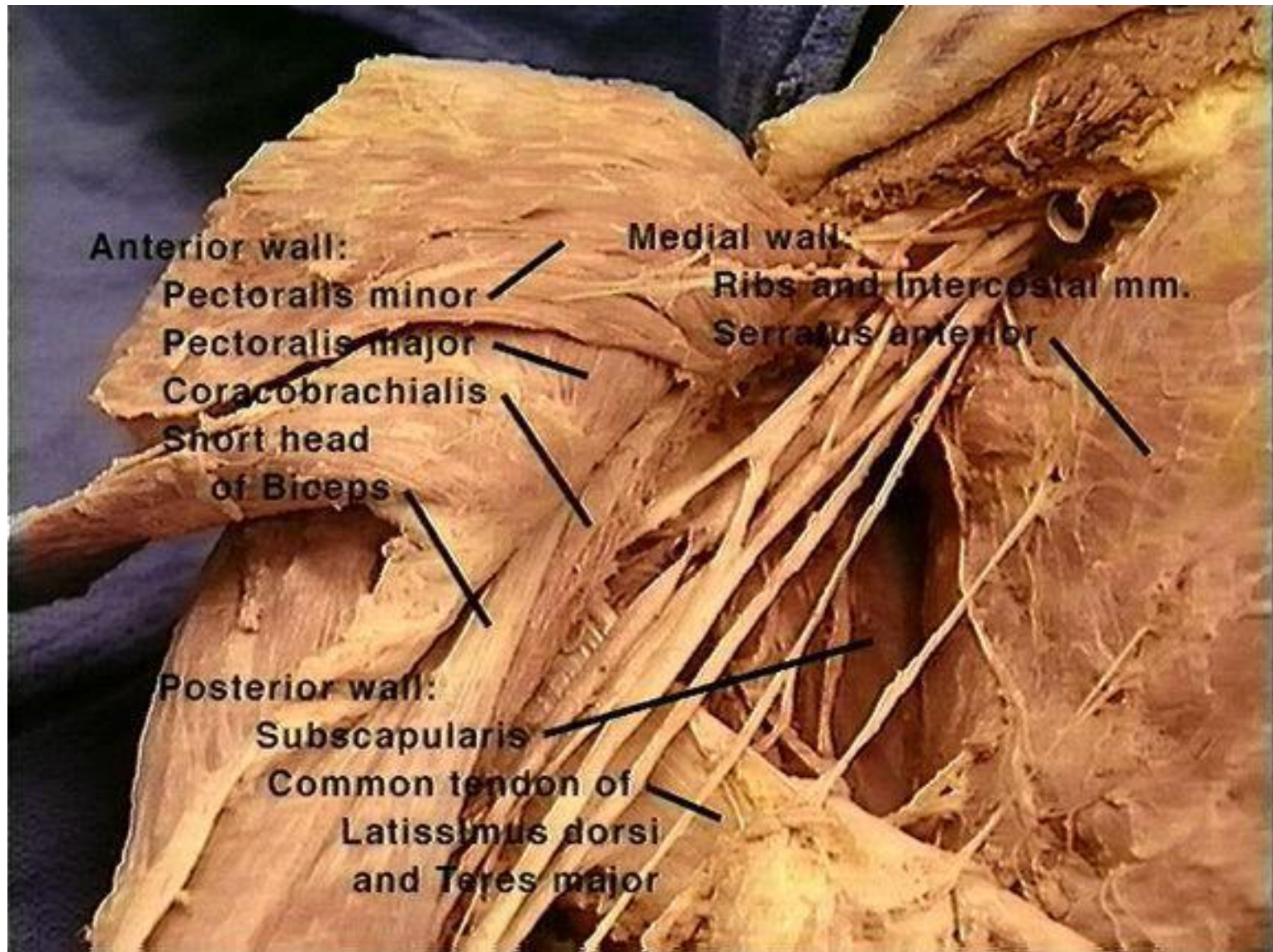


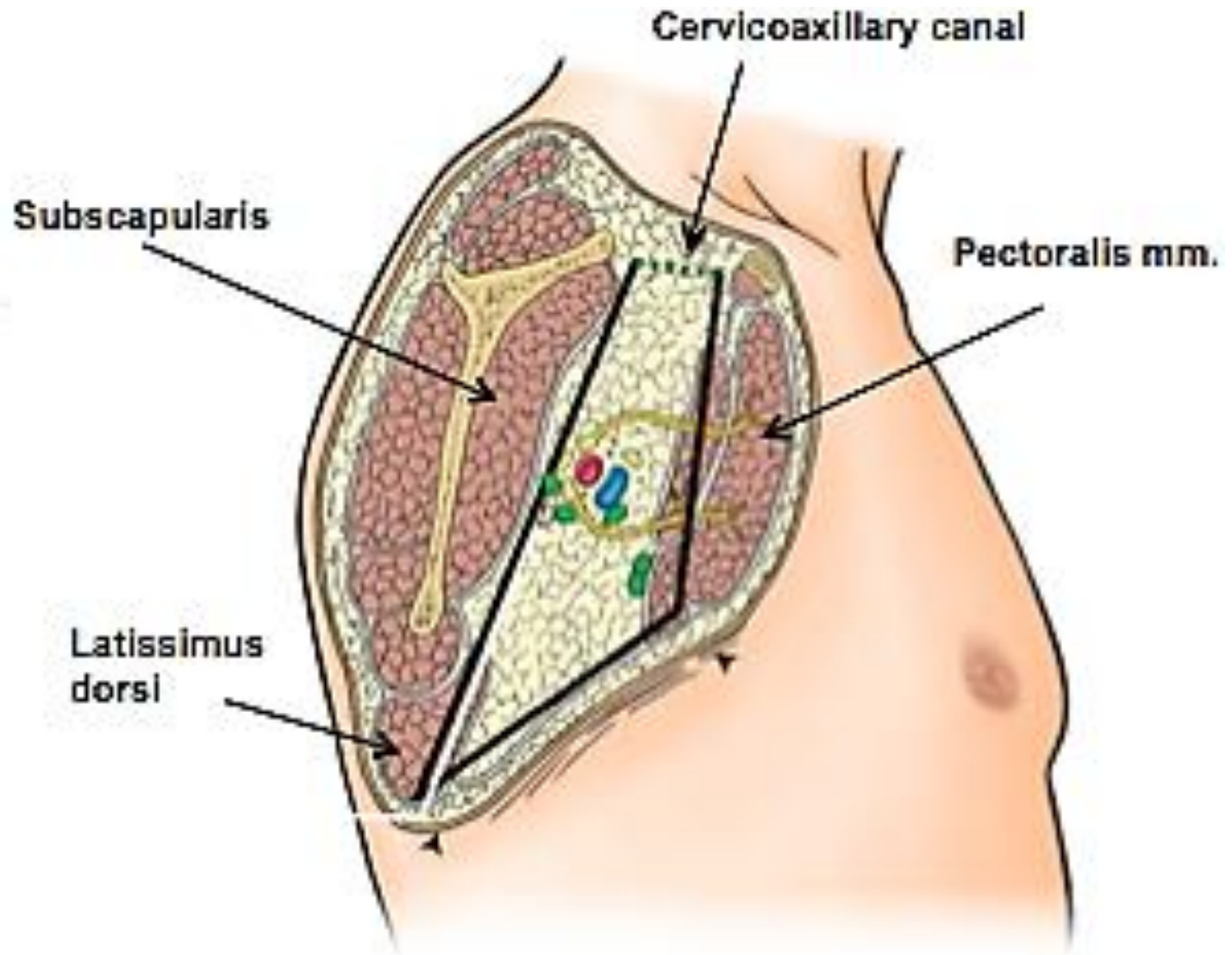
Lateral wall



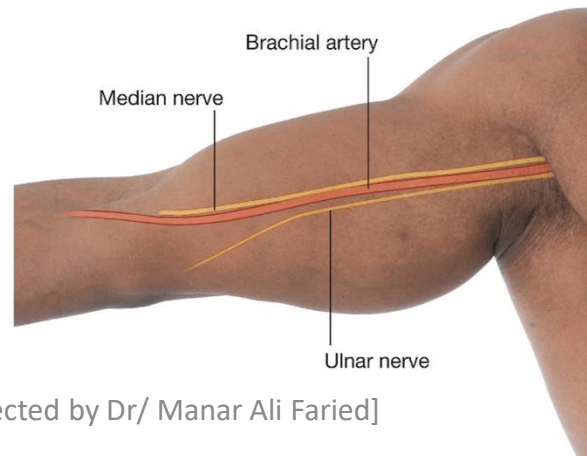
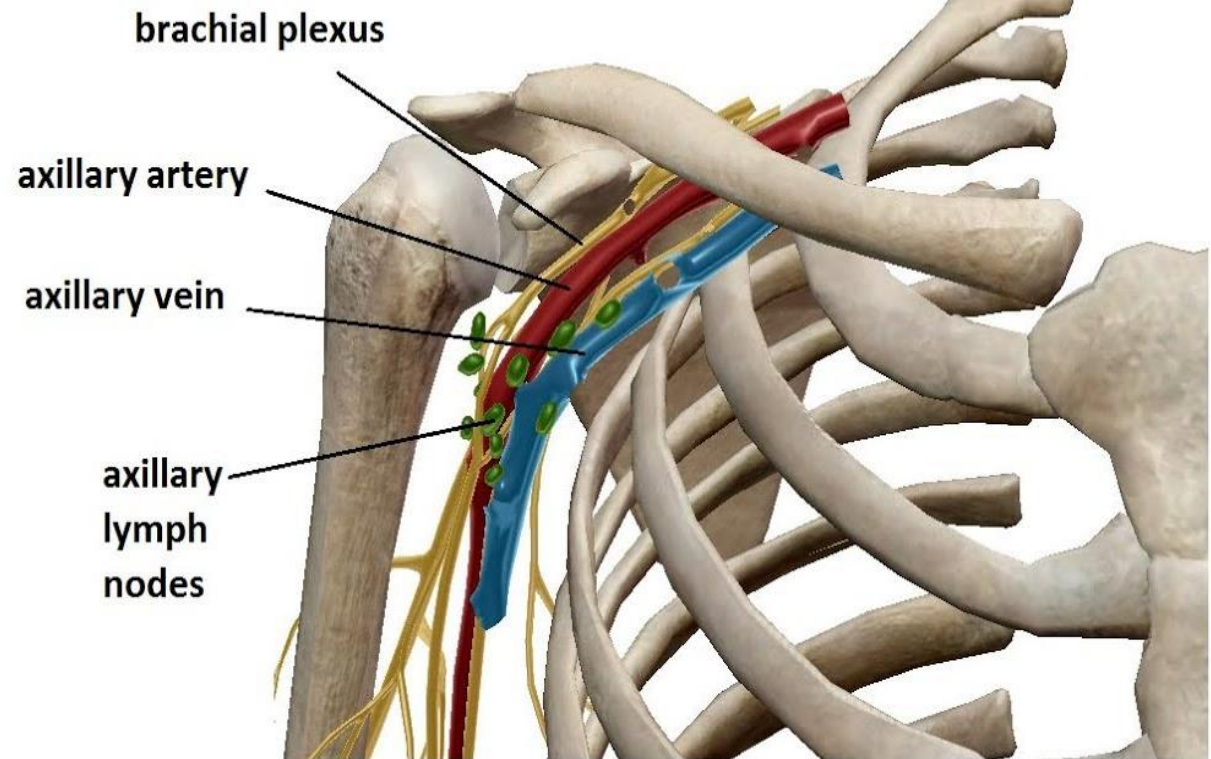
Medial wall



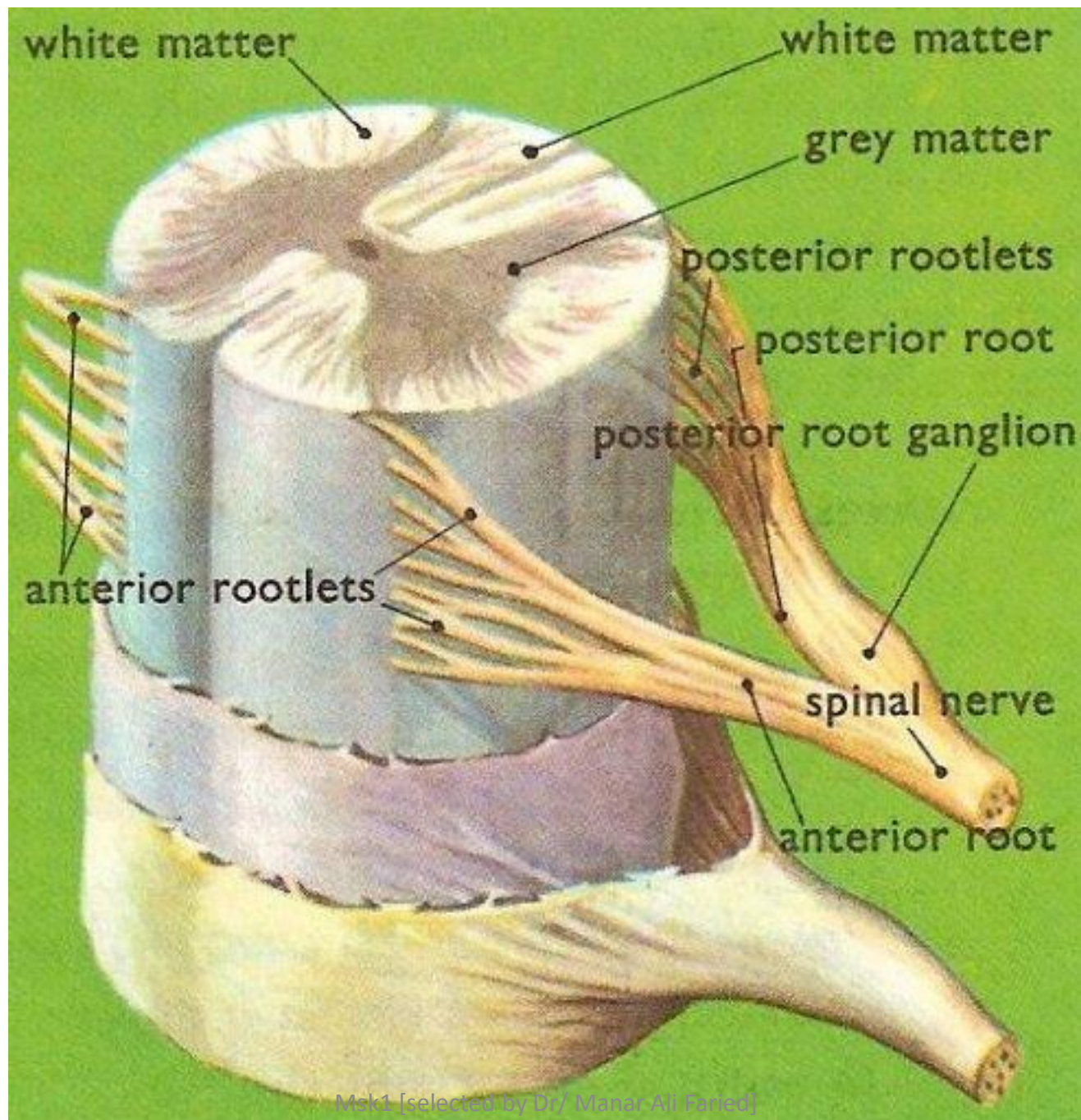


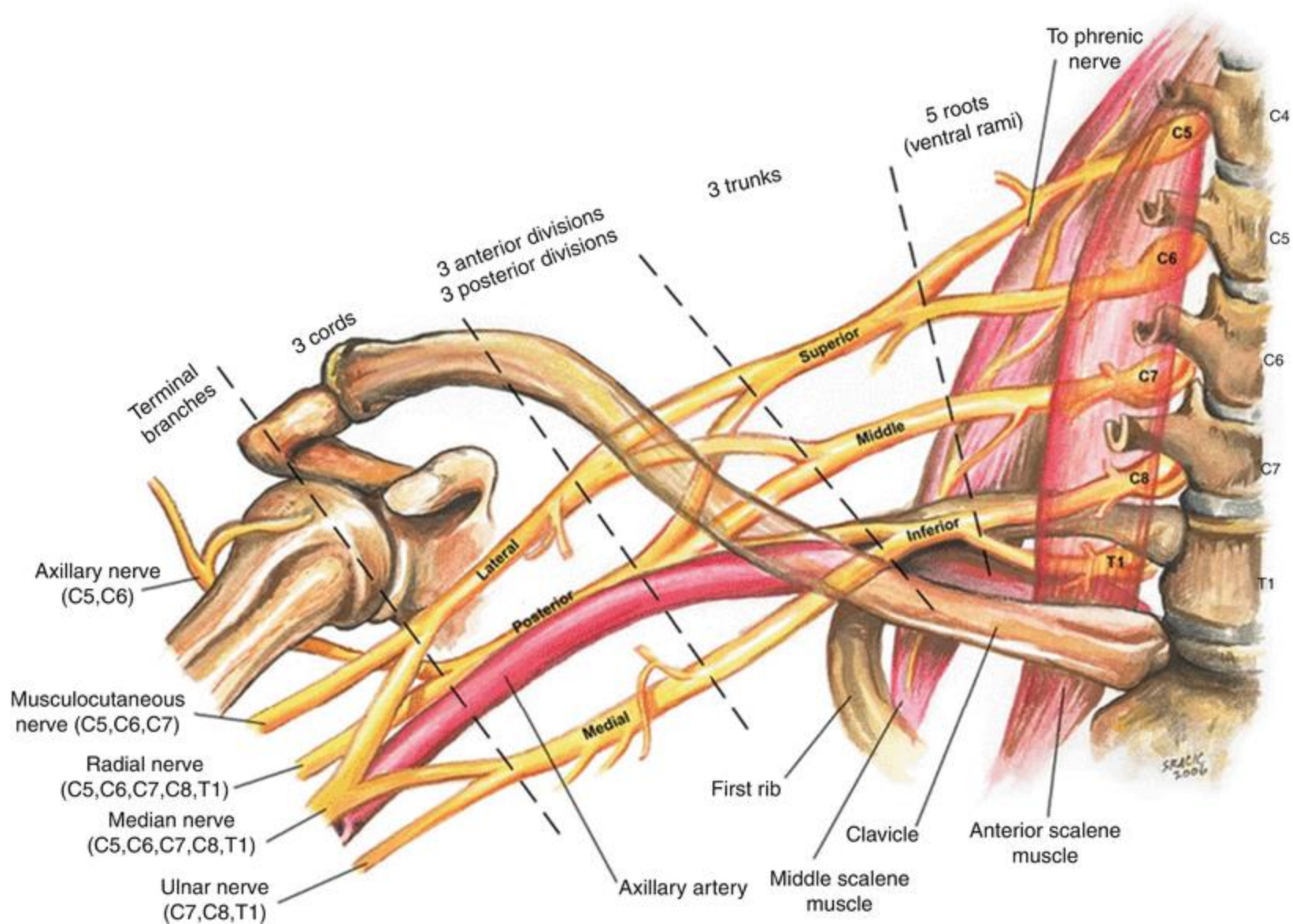


Contents



BRACHIAL PLEXUS

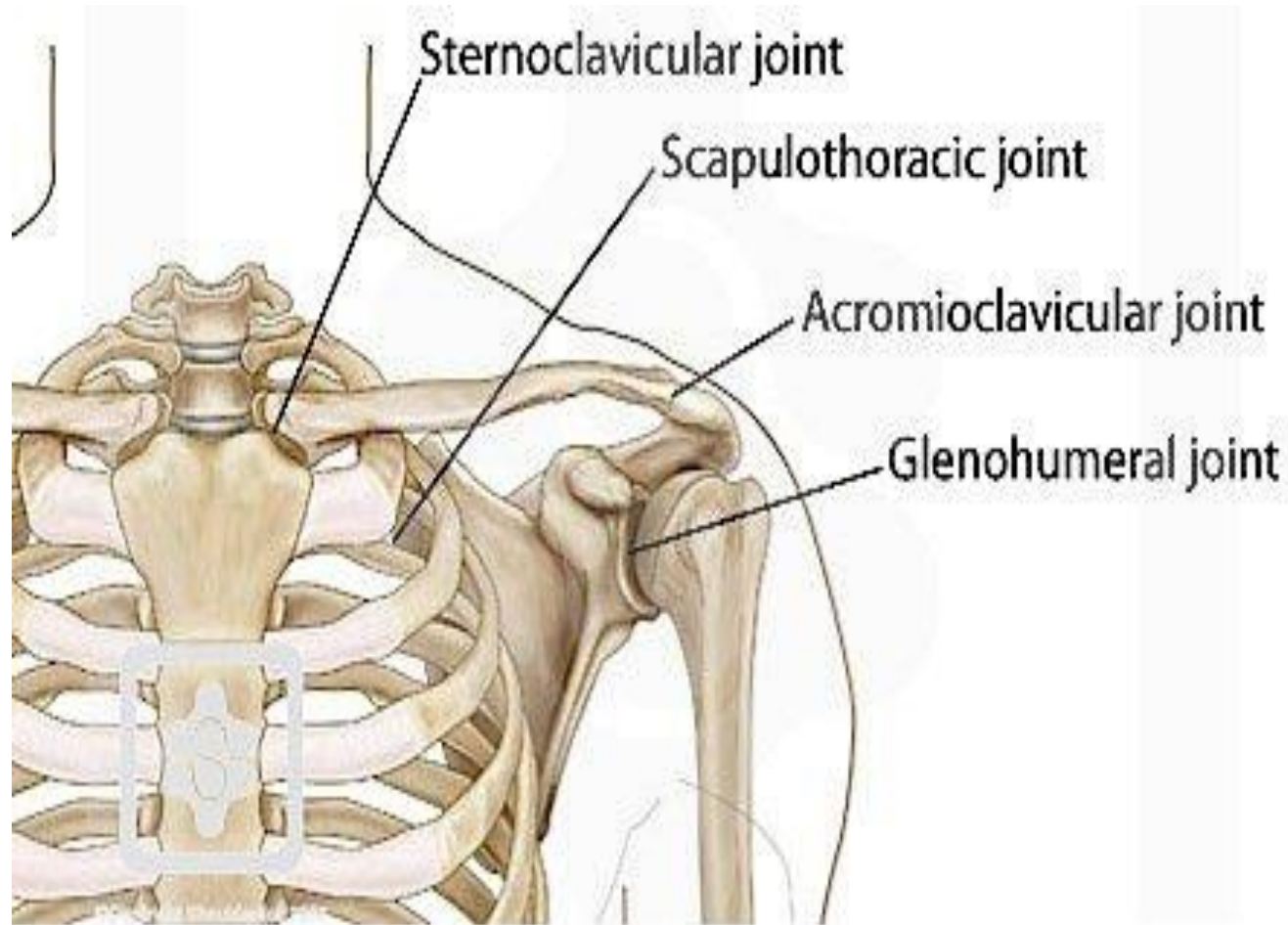




LECTURE [3]

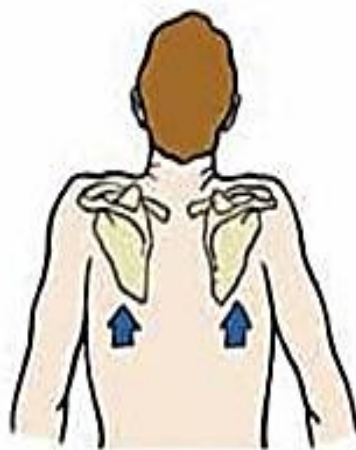Pectoral

Back/Scapular

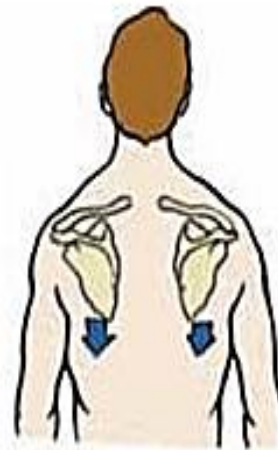

Scapular movement

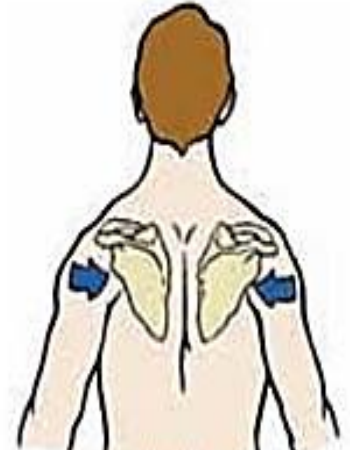Figure 3-34
Scapular movements



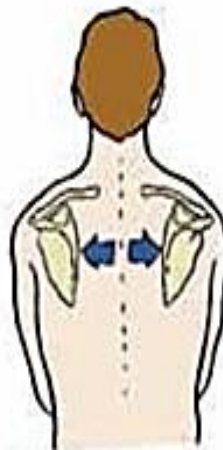Elevation



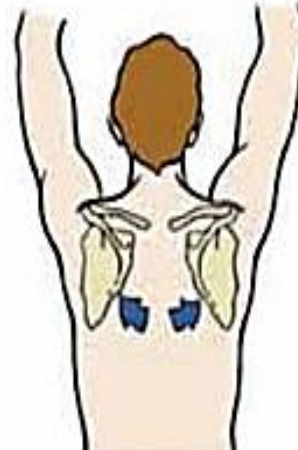Depression



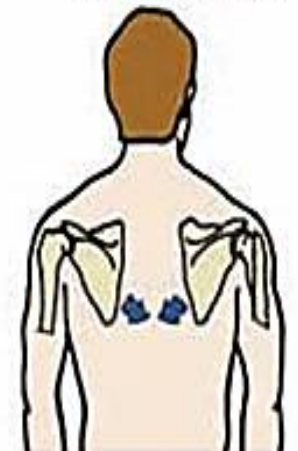
Adduction (retraction)



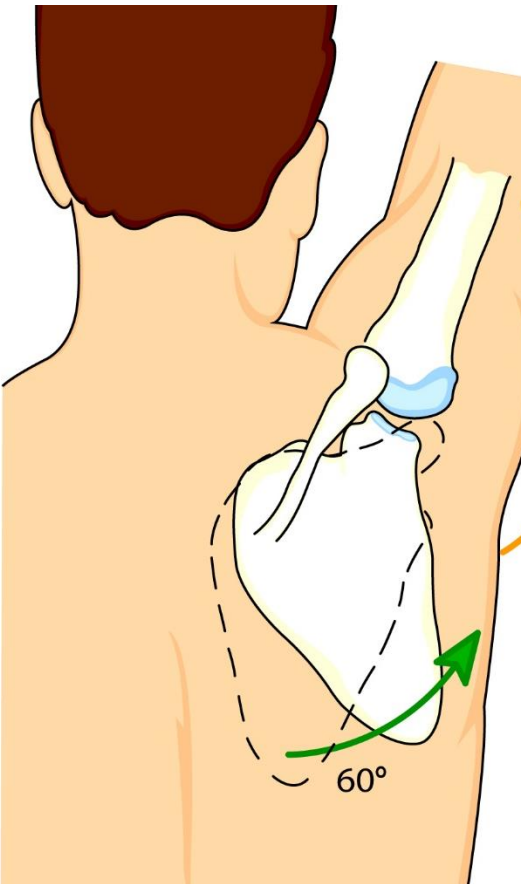Abduction (protraction)



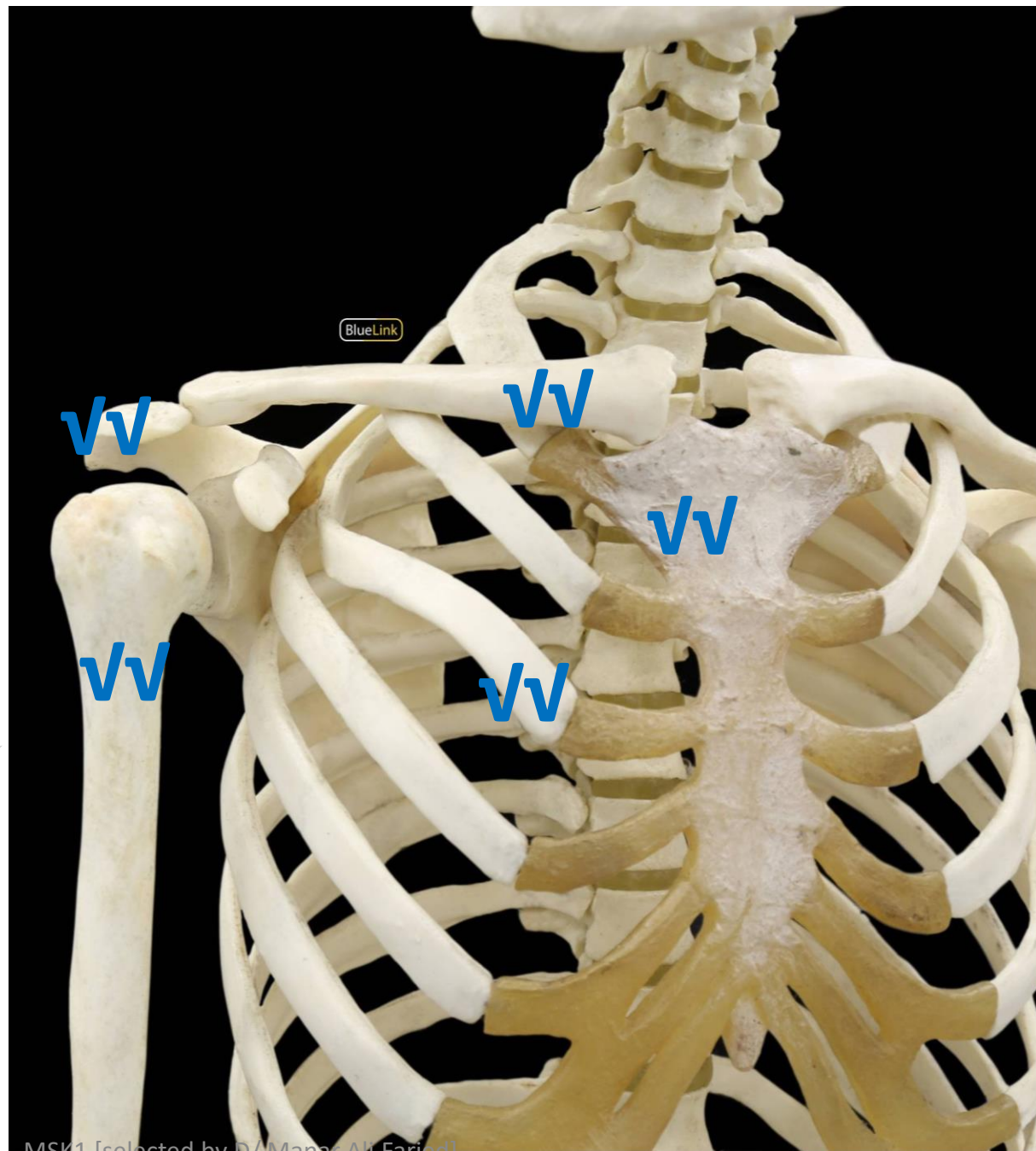
Upward rotation

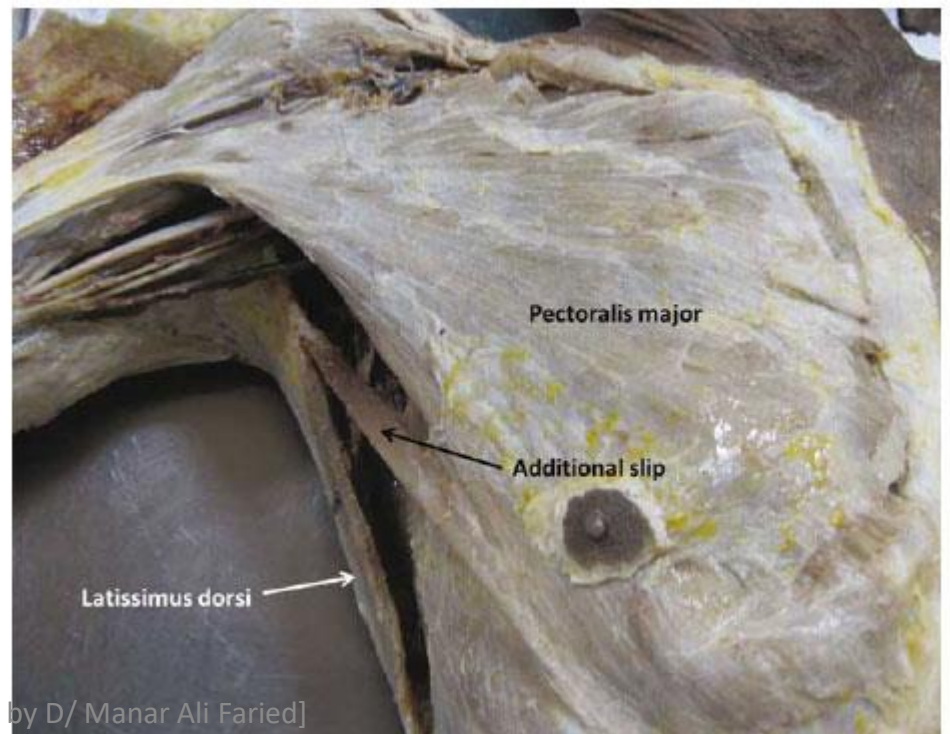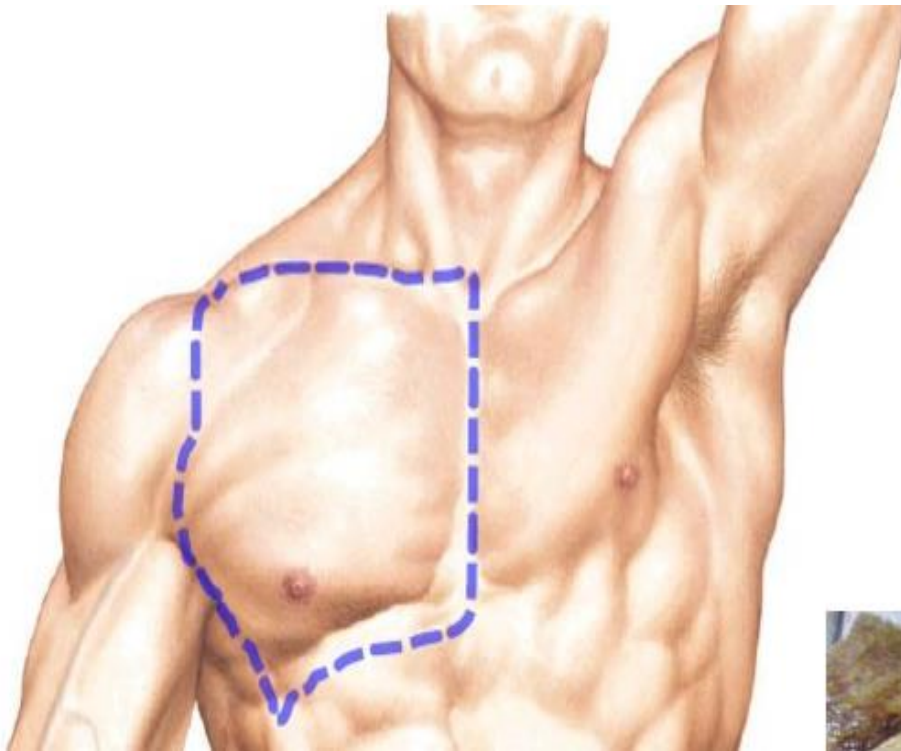


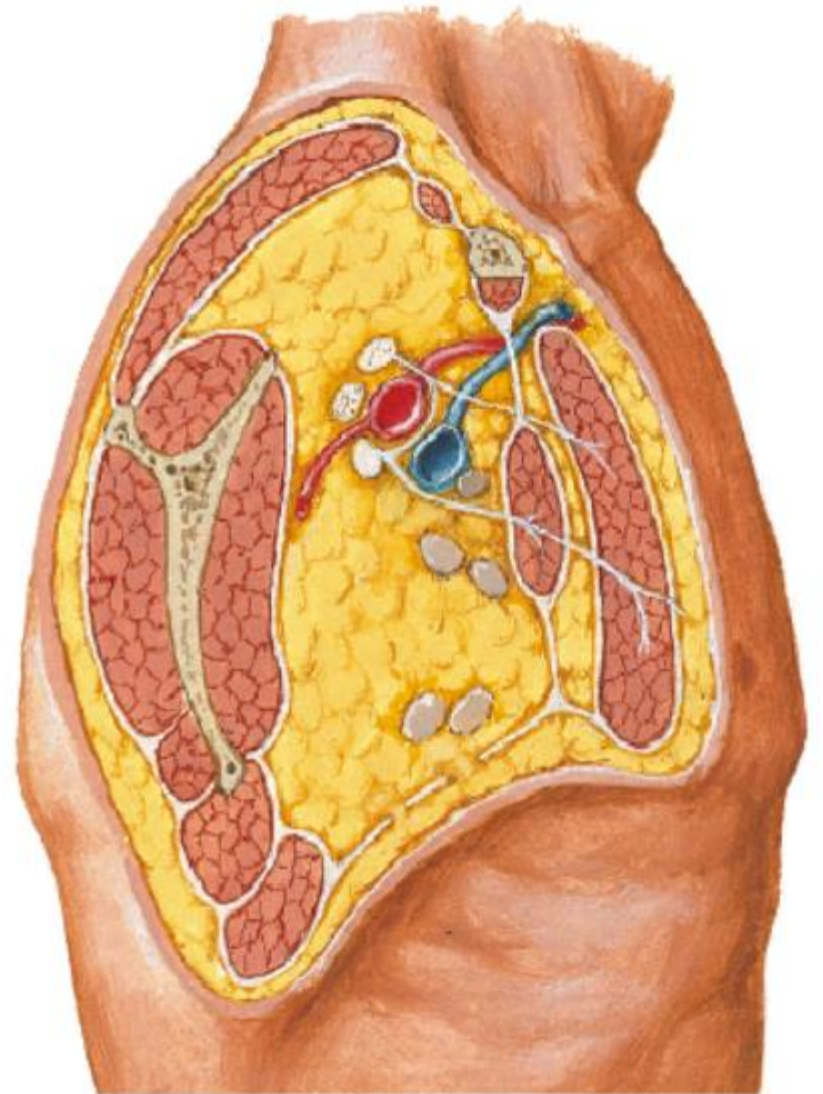
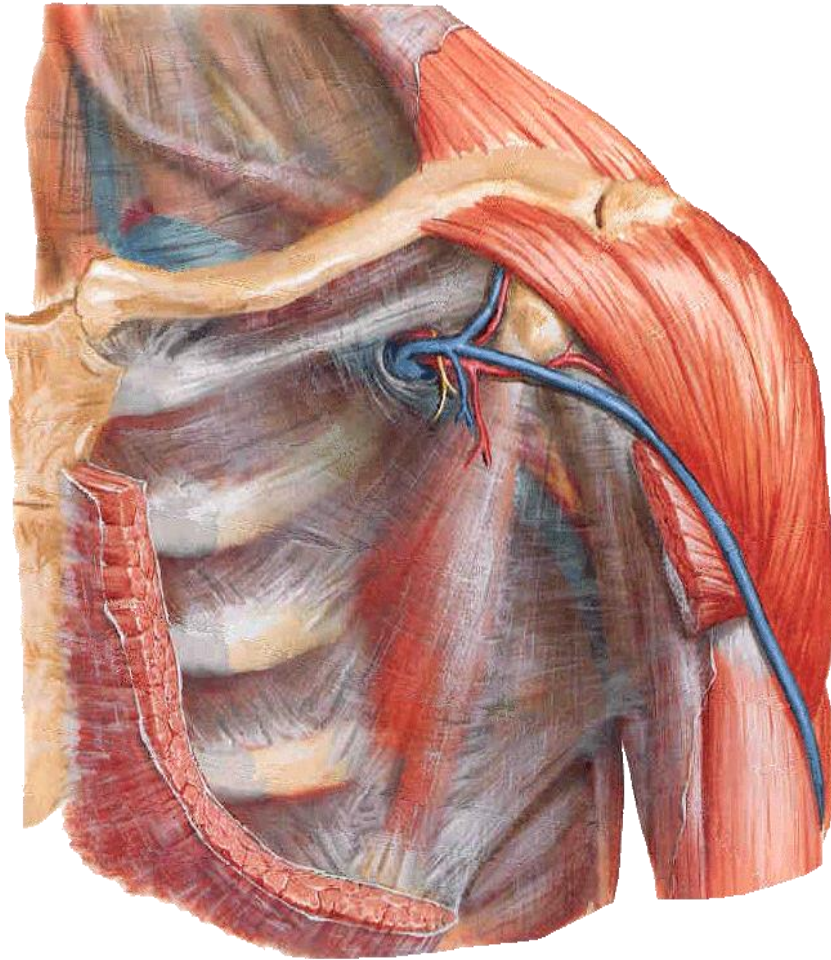
Downward rotation (return to anatomical position)



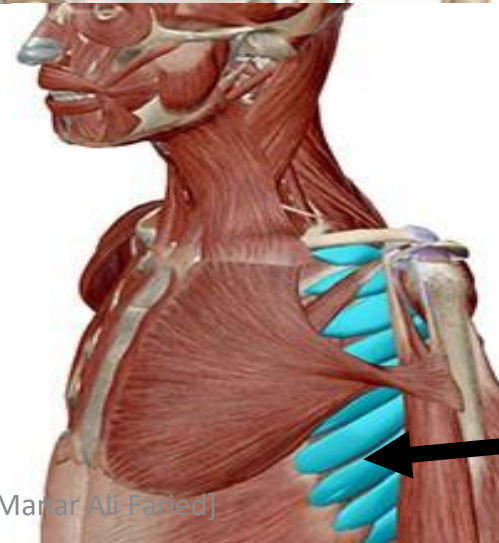
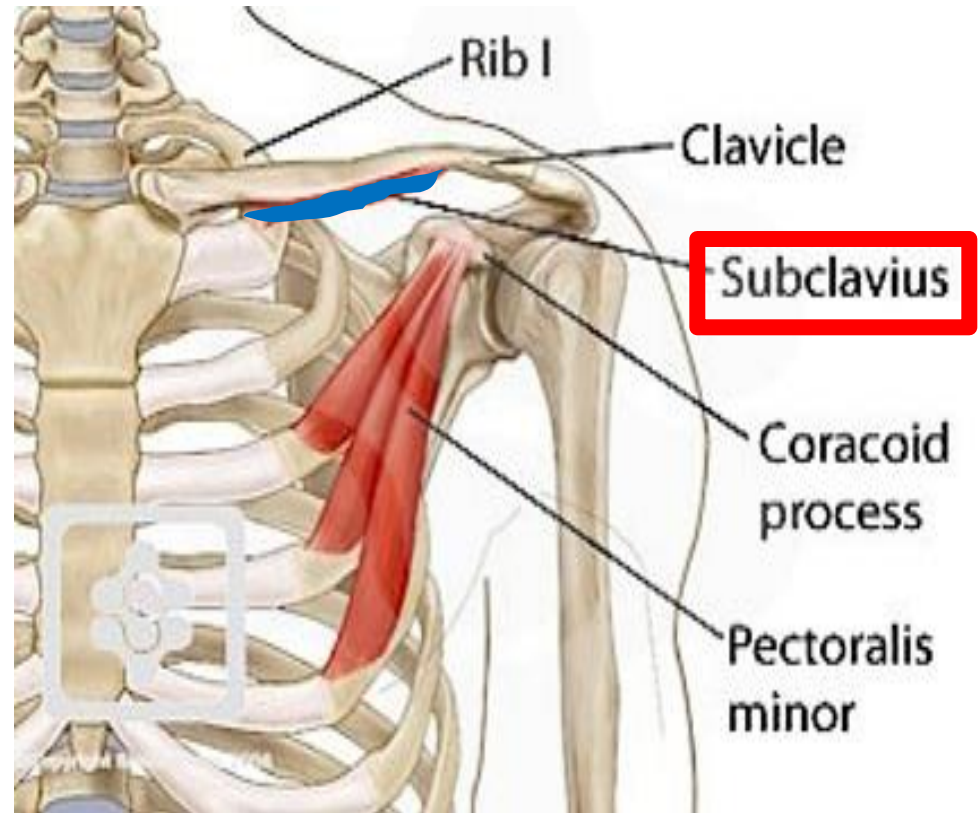
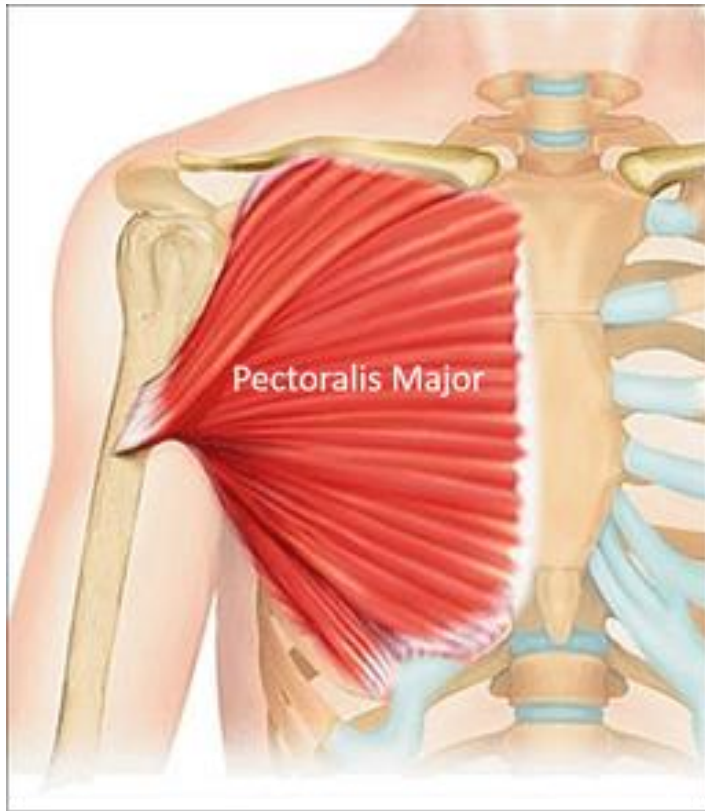
Pectoral Region



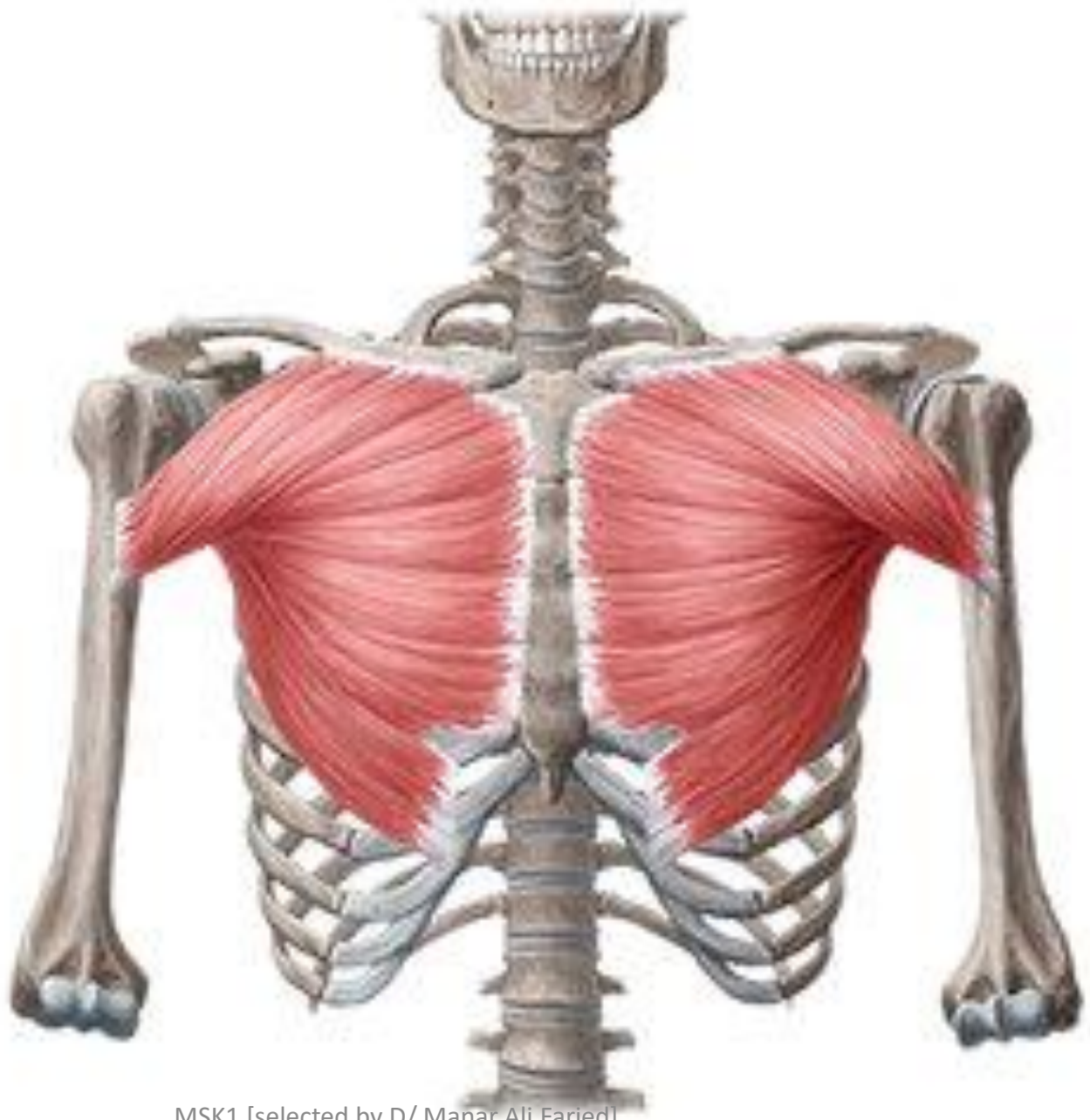




Muscles



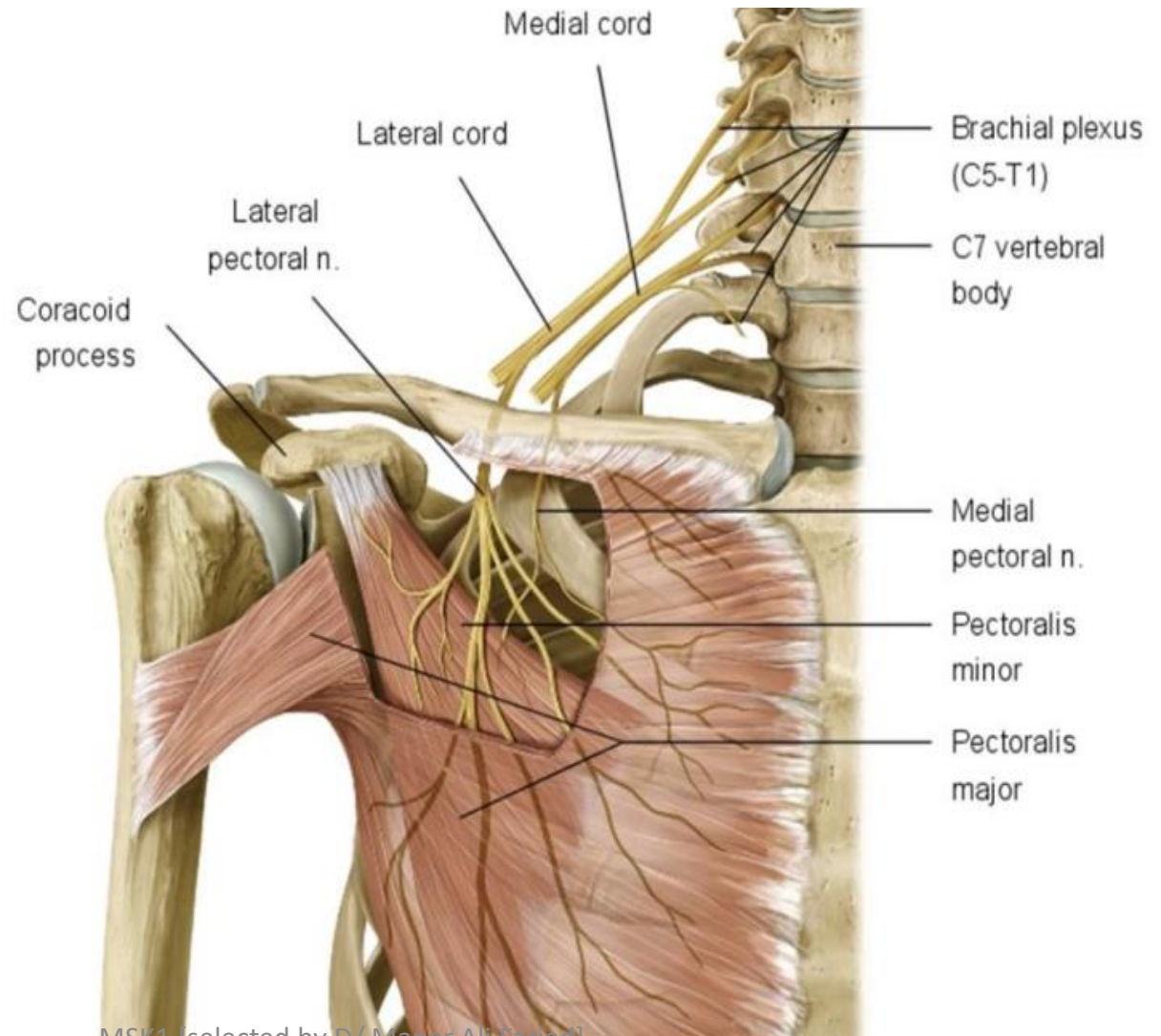
Pectoralis Major



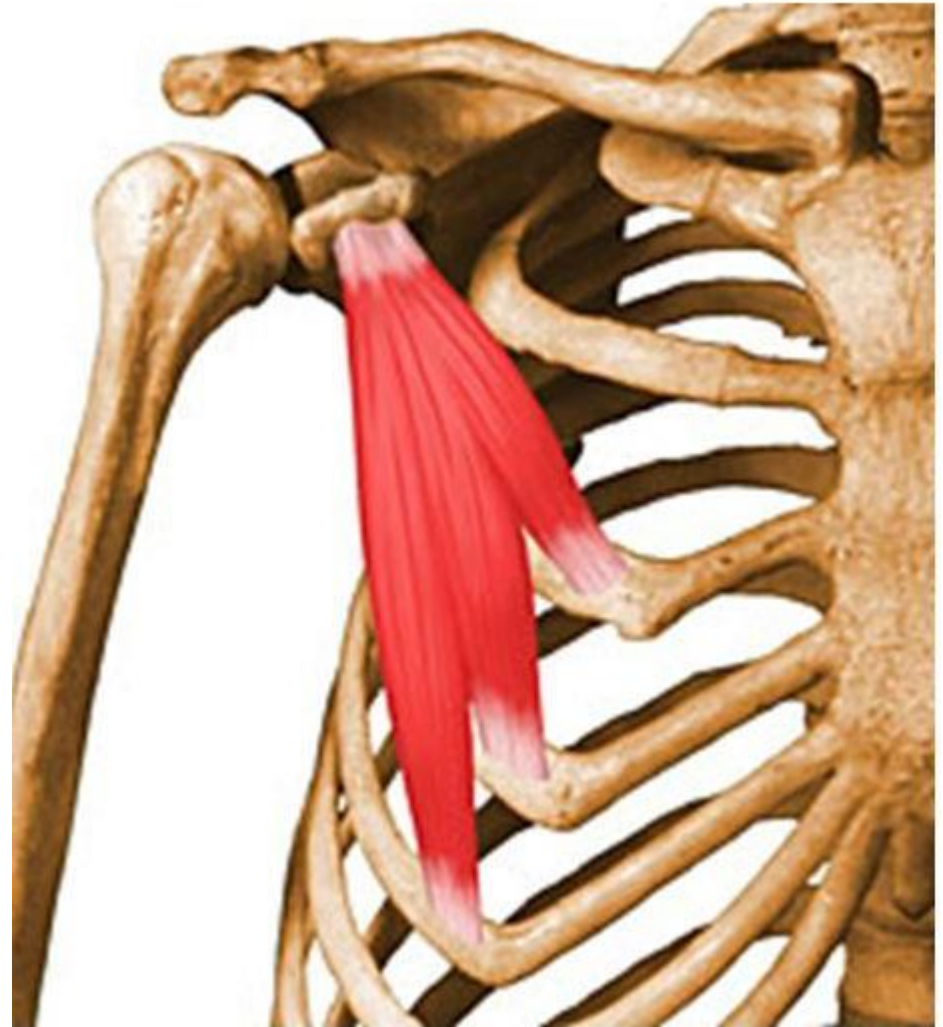MSK1 [selected by D/ Manar Ali Faried]

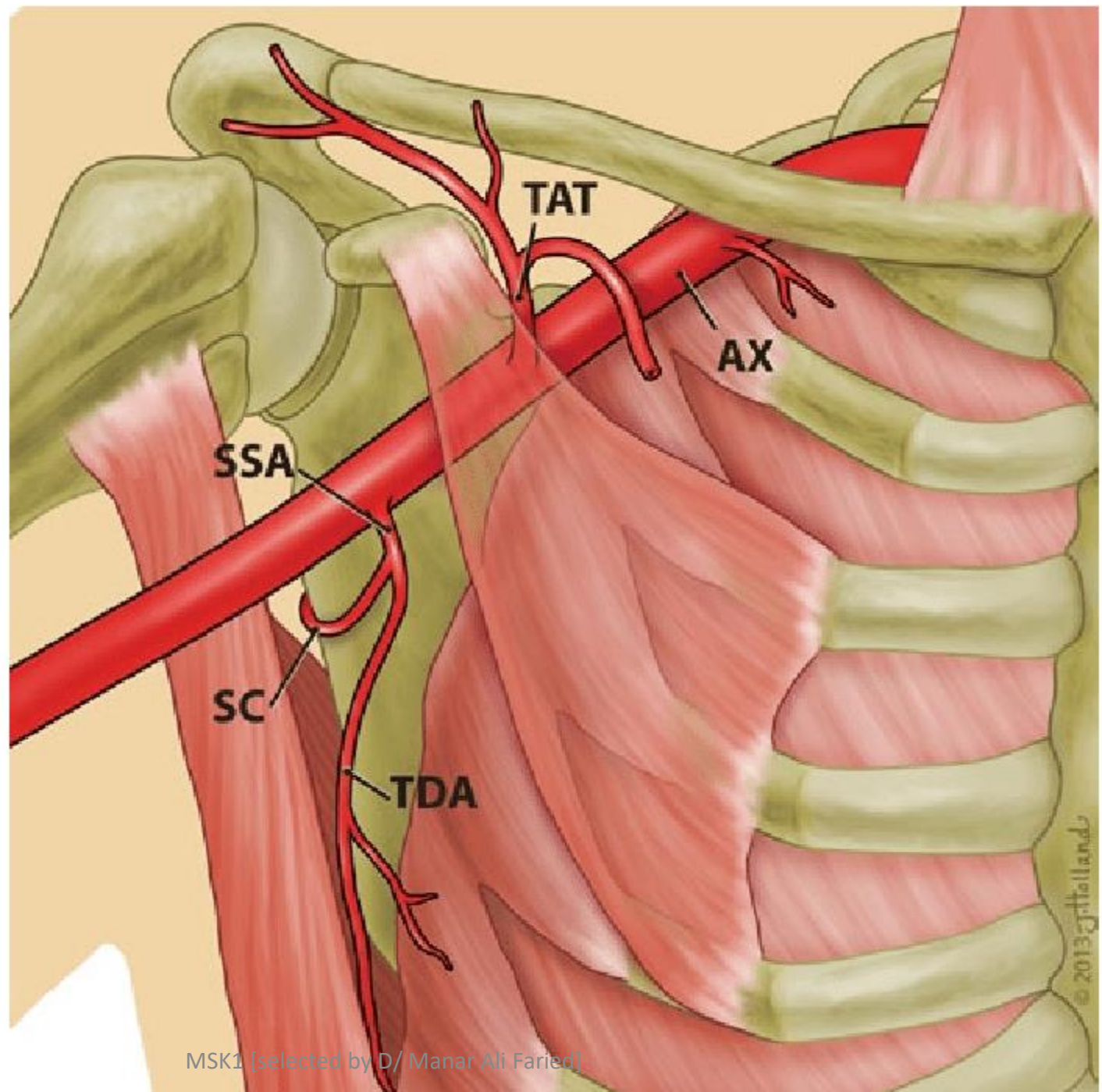
**Medial
pectoral N**

**Lateral
pectoral N**

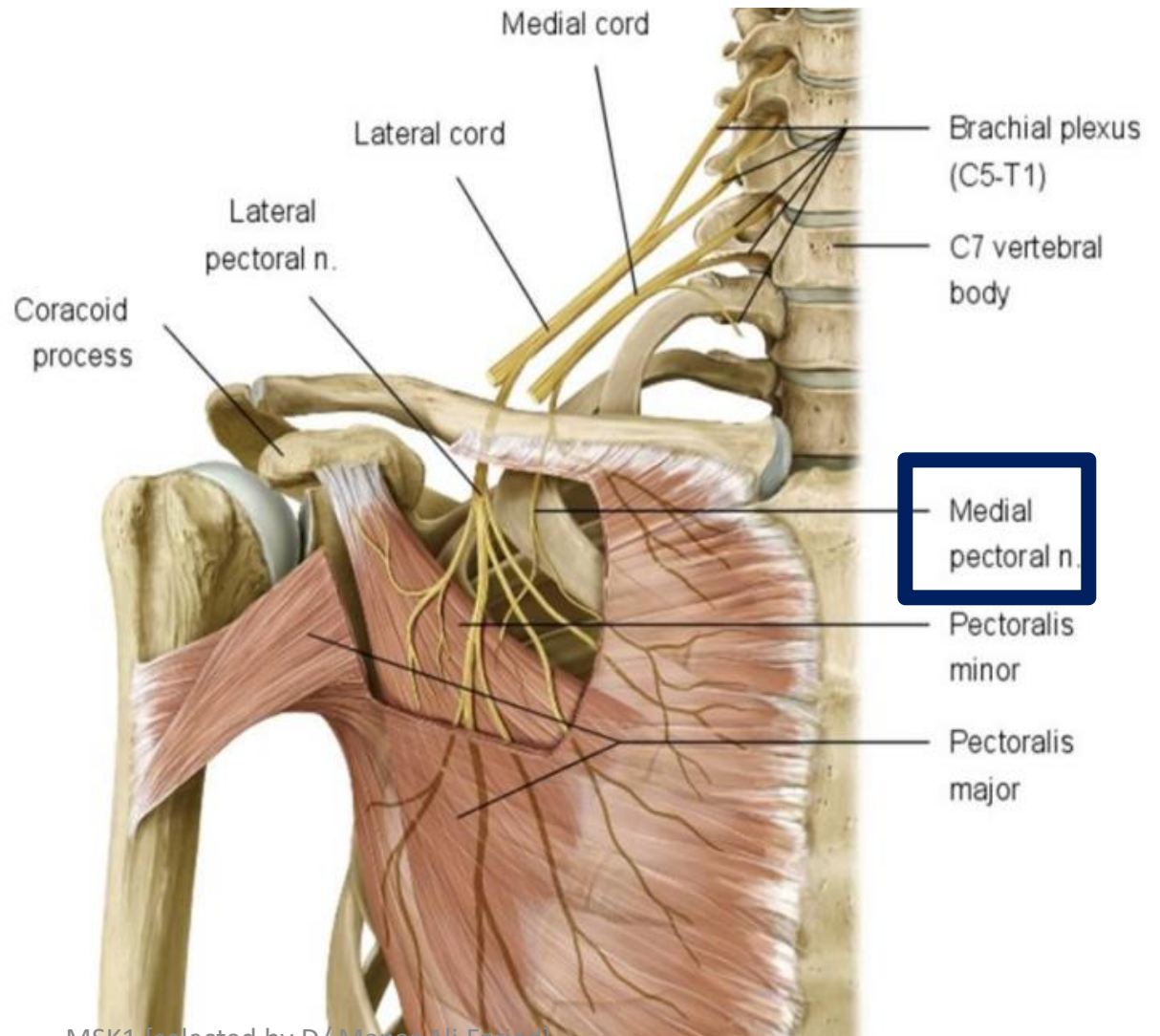


Pectoralis minor

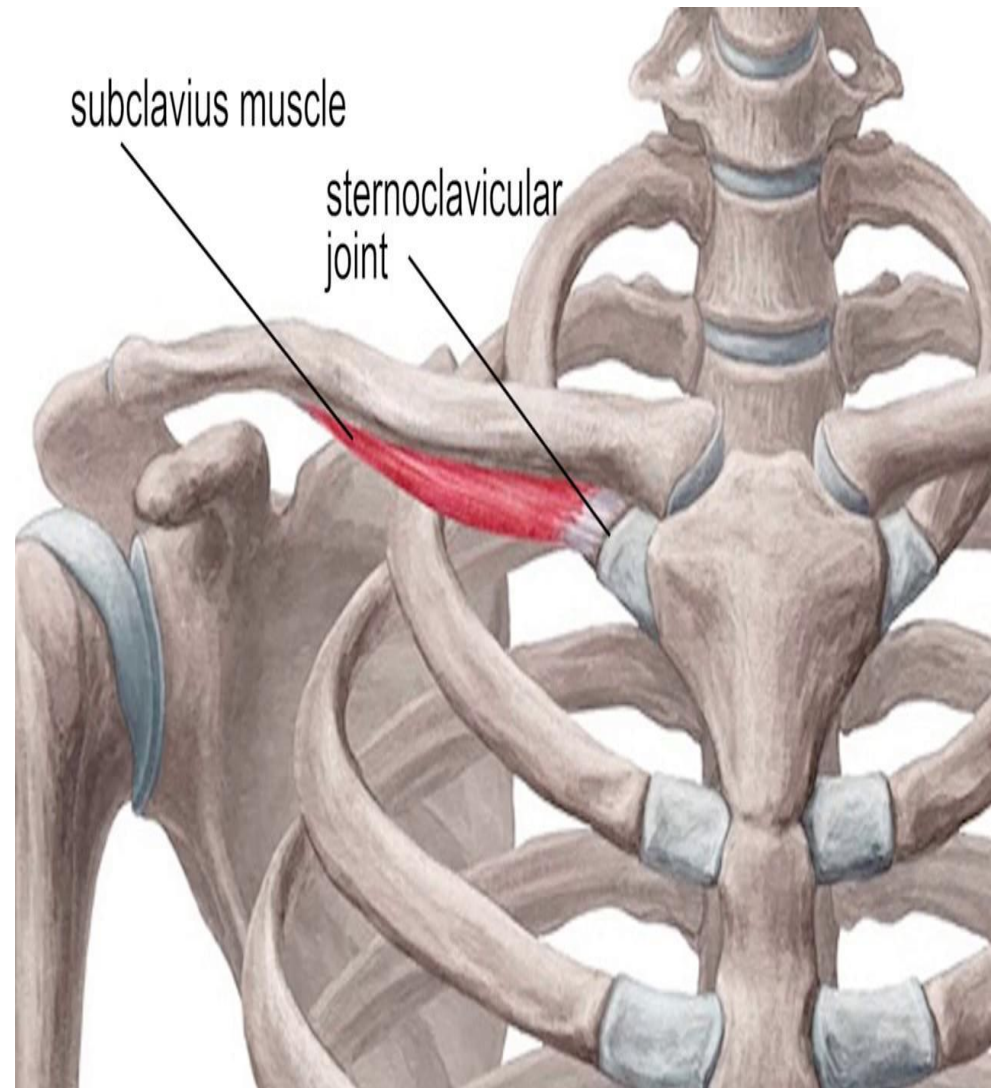




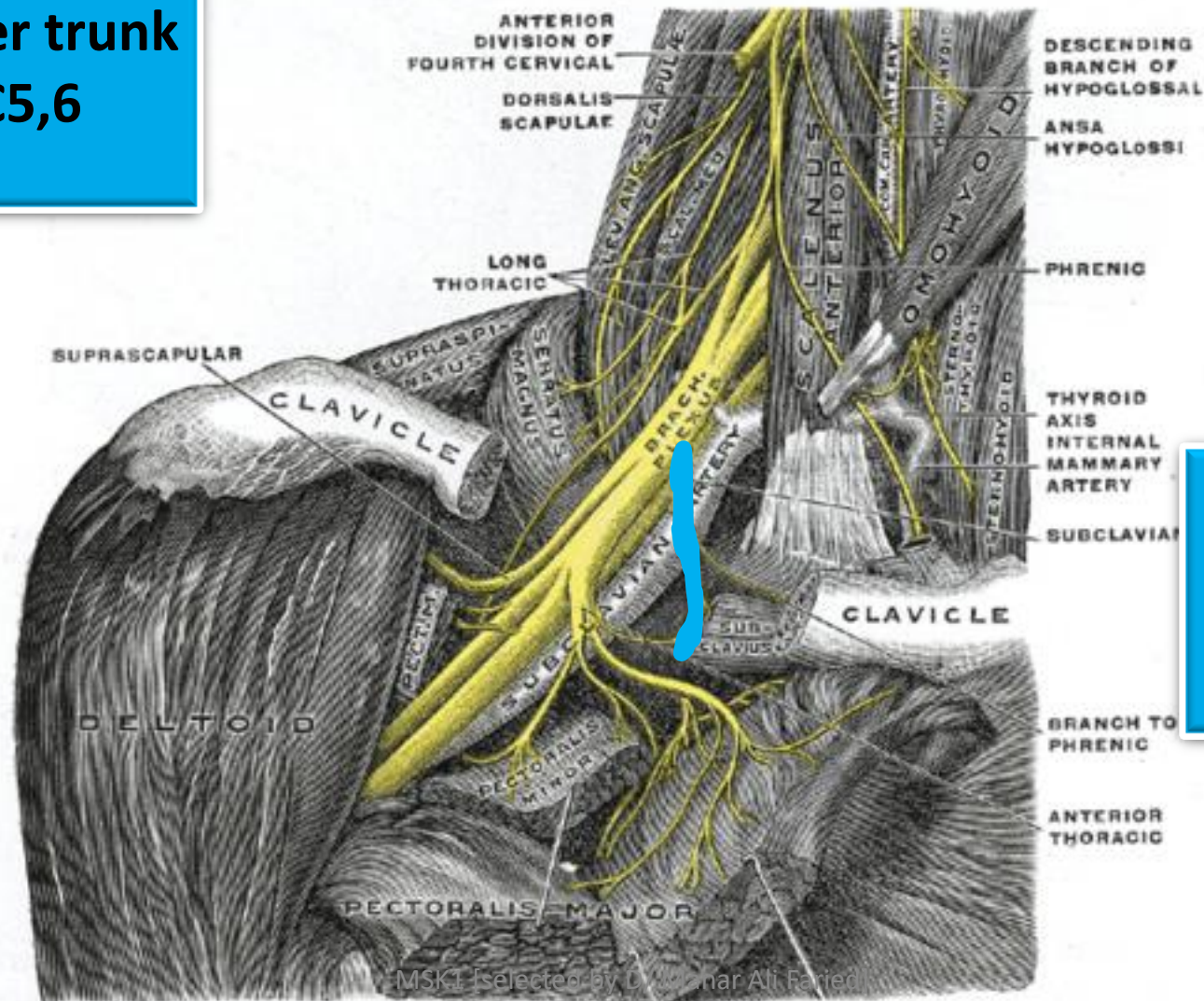
Medial pectoral N



Subclavius

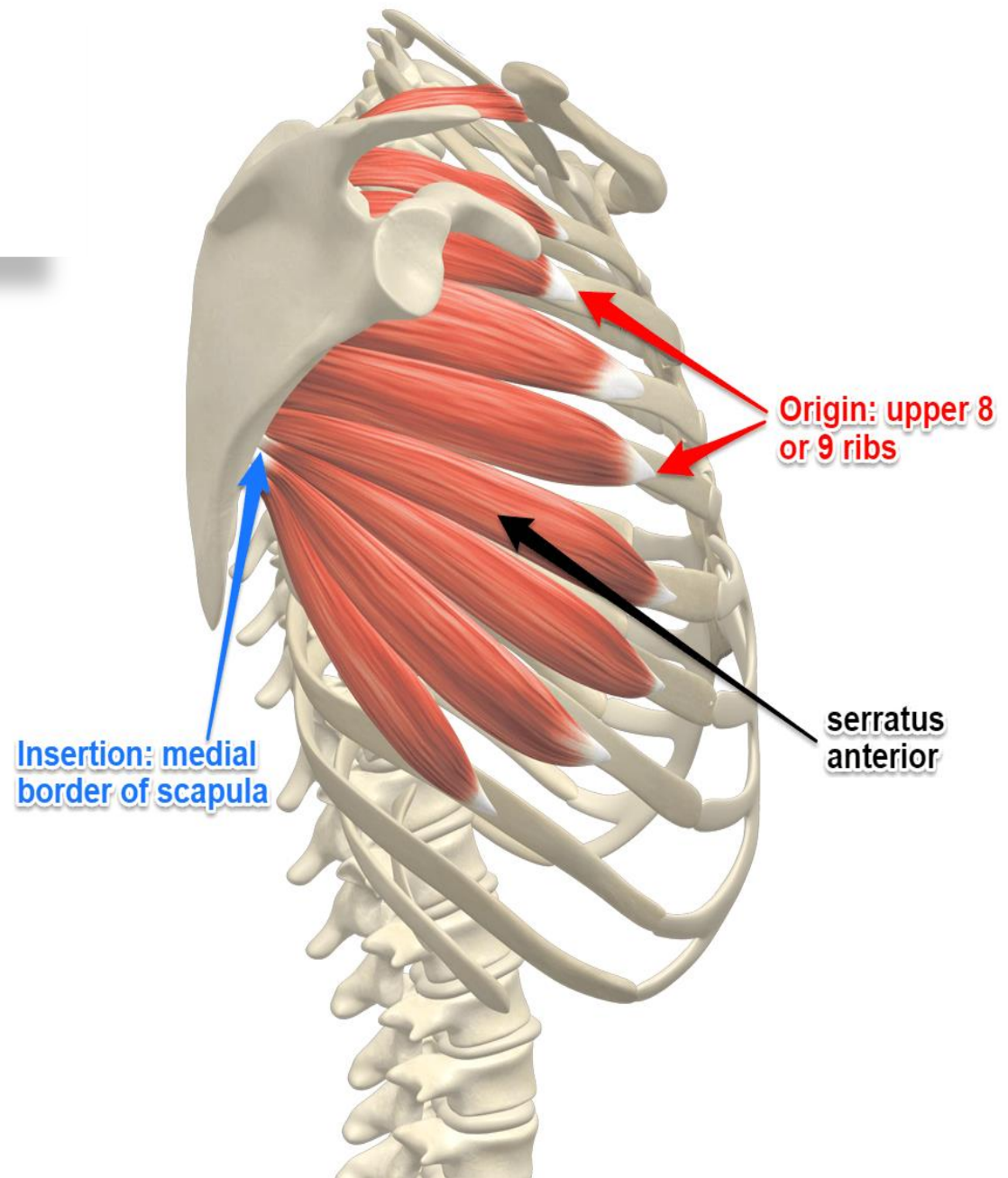


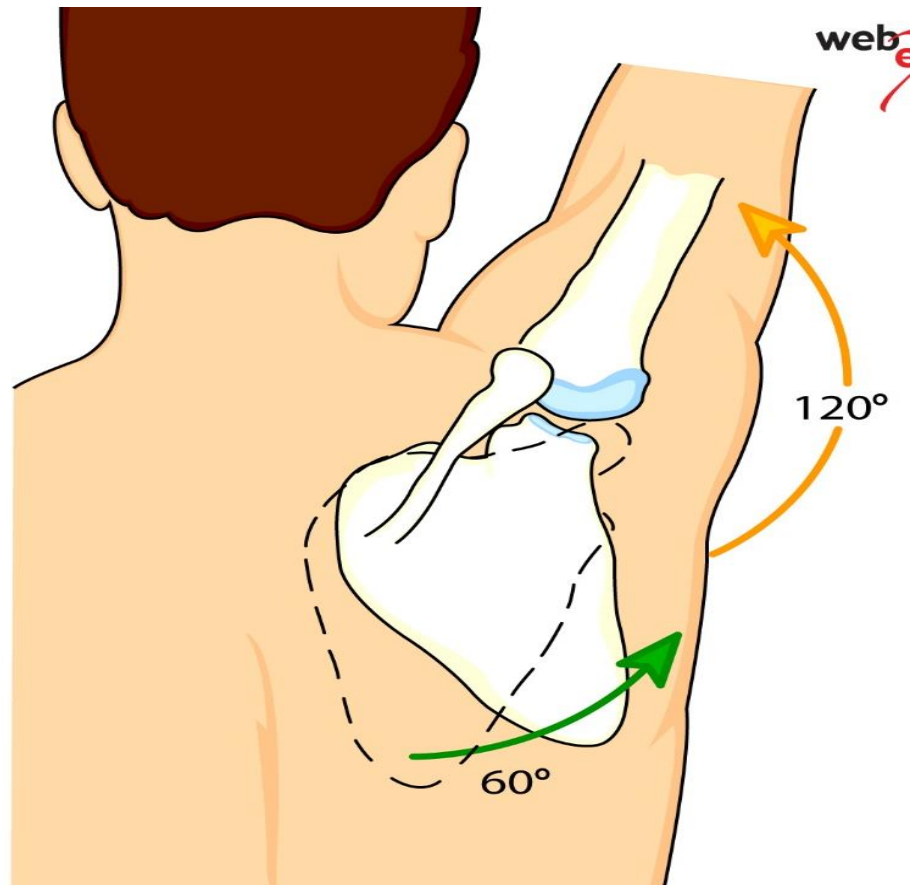
Upper trunk
C5,6



N
To
subclavius

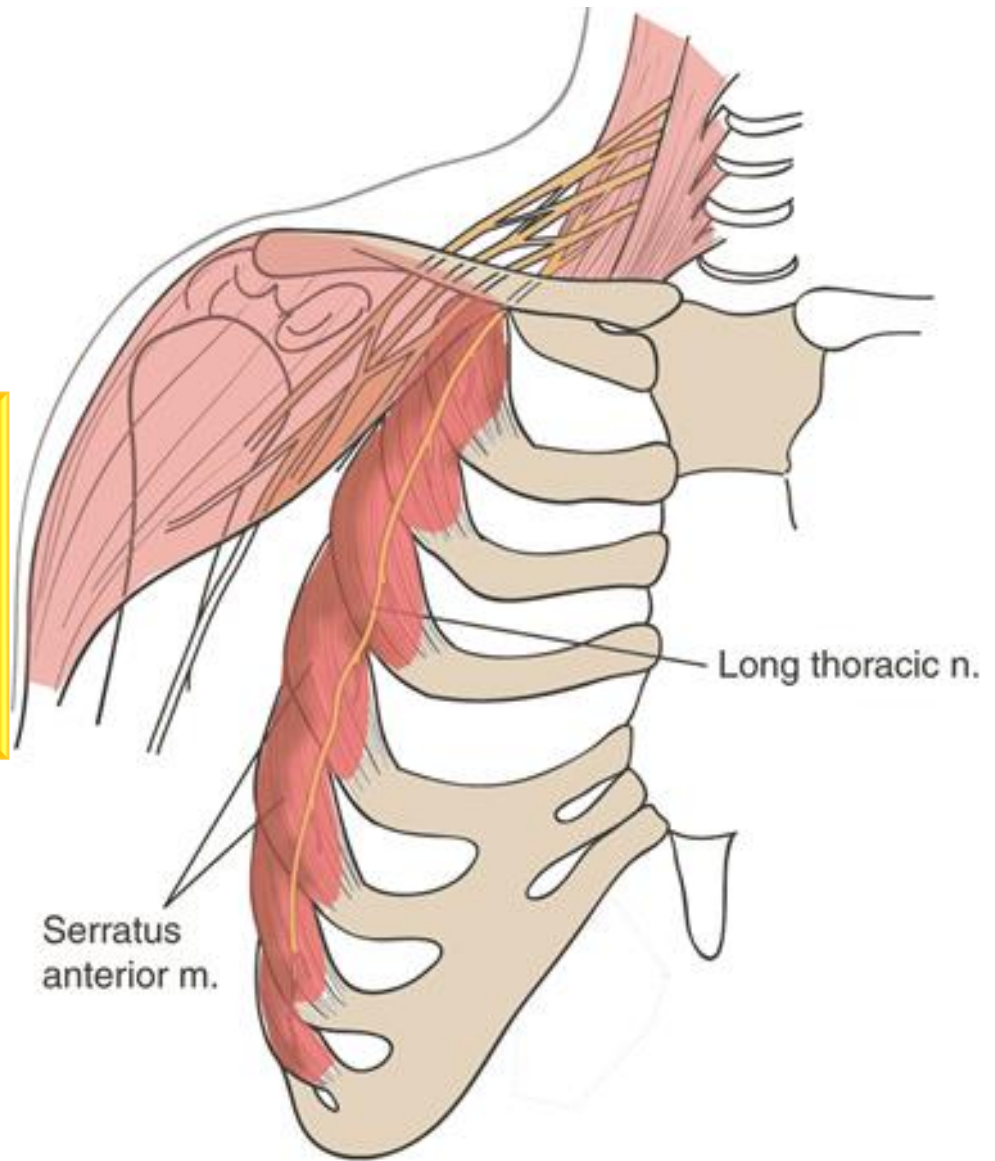
Serratus anterior



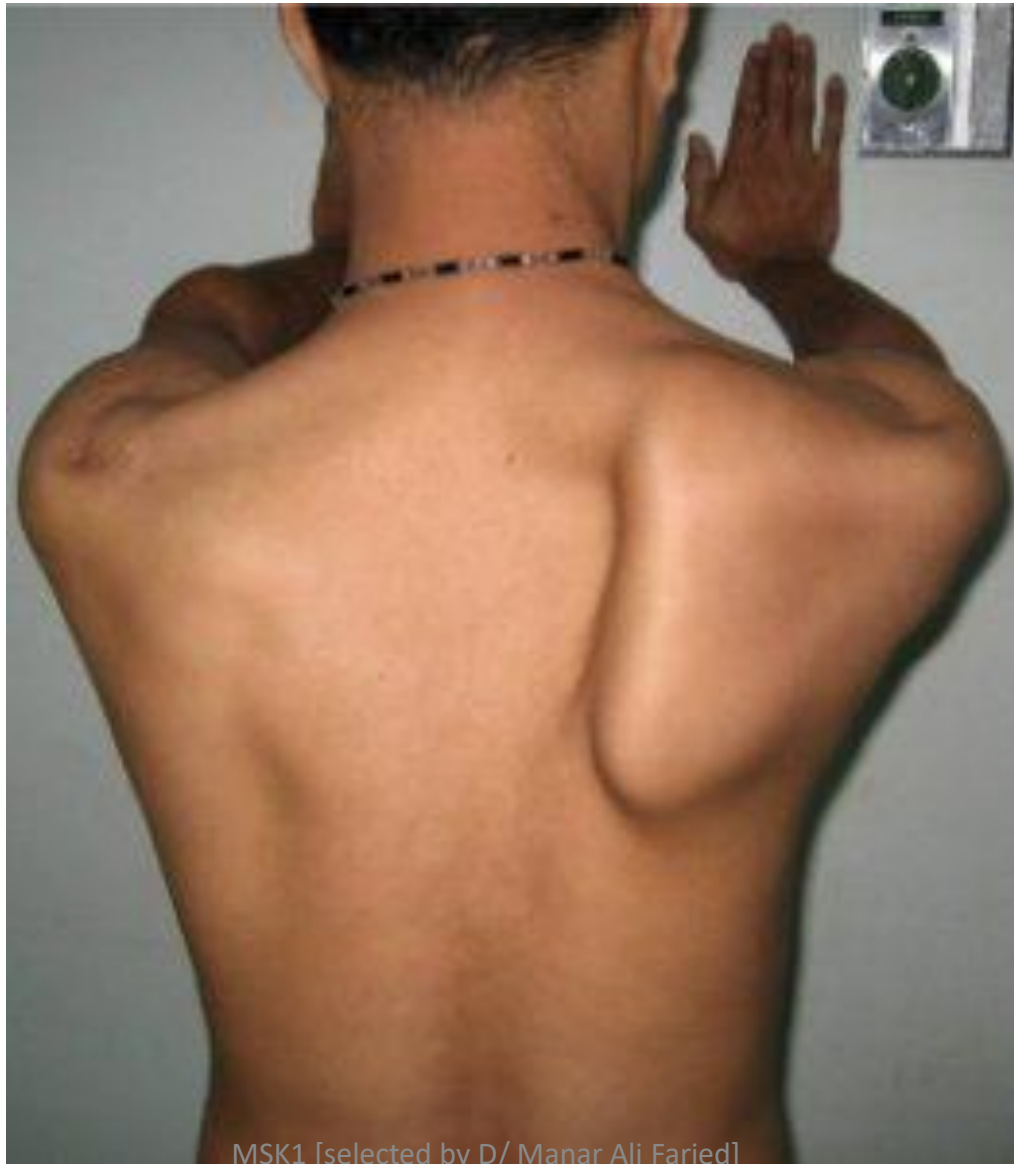

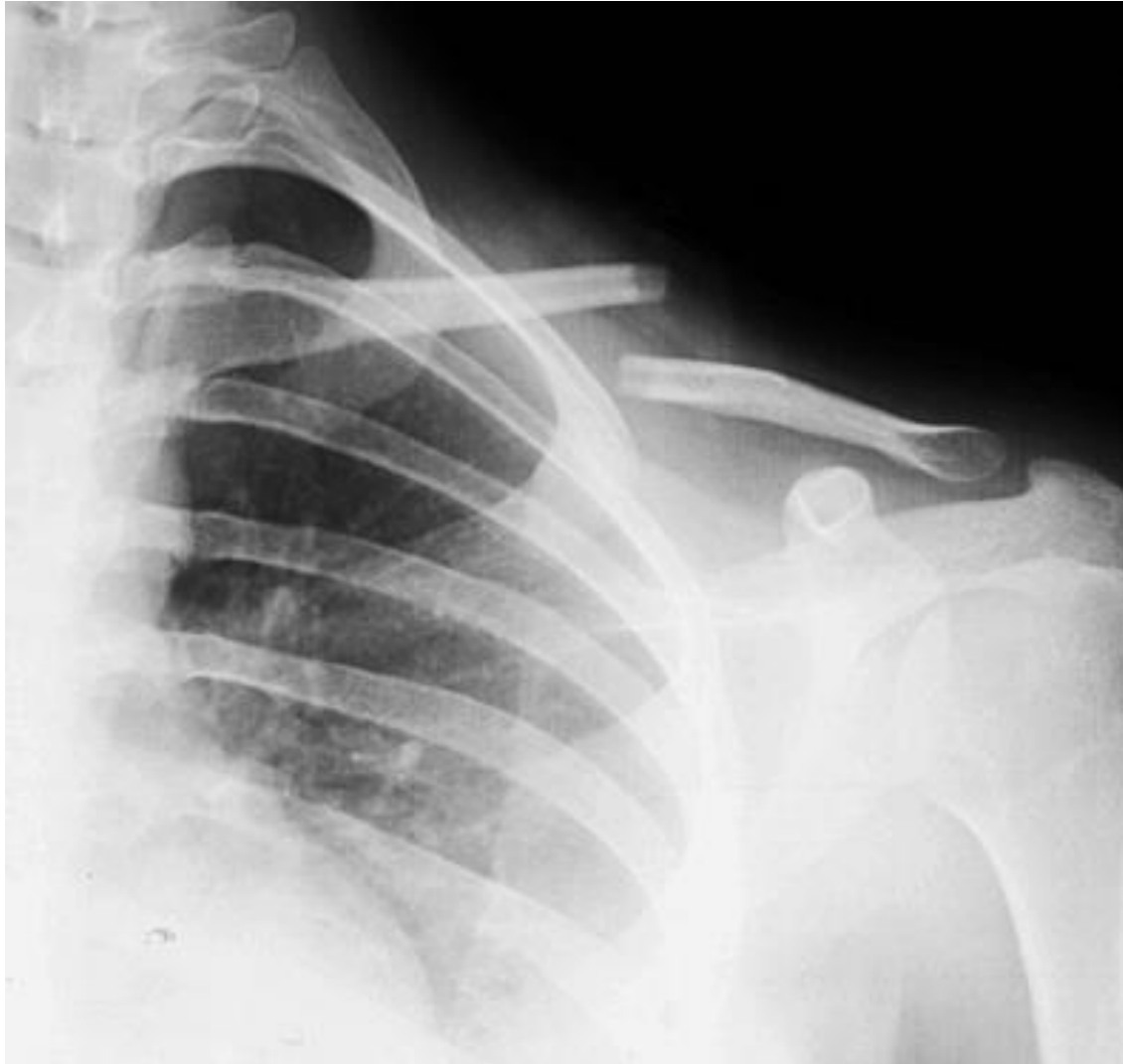**Long thoracic Nerve
[N to serratus
anterior]**

**Roots of the brachial
plexus
C5,6,7**



The scapula protrudes from a person's back in an abnormal position.

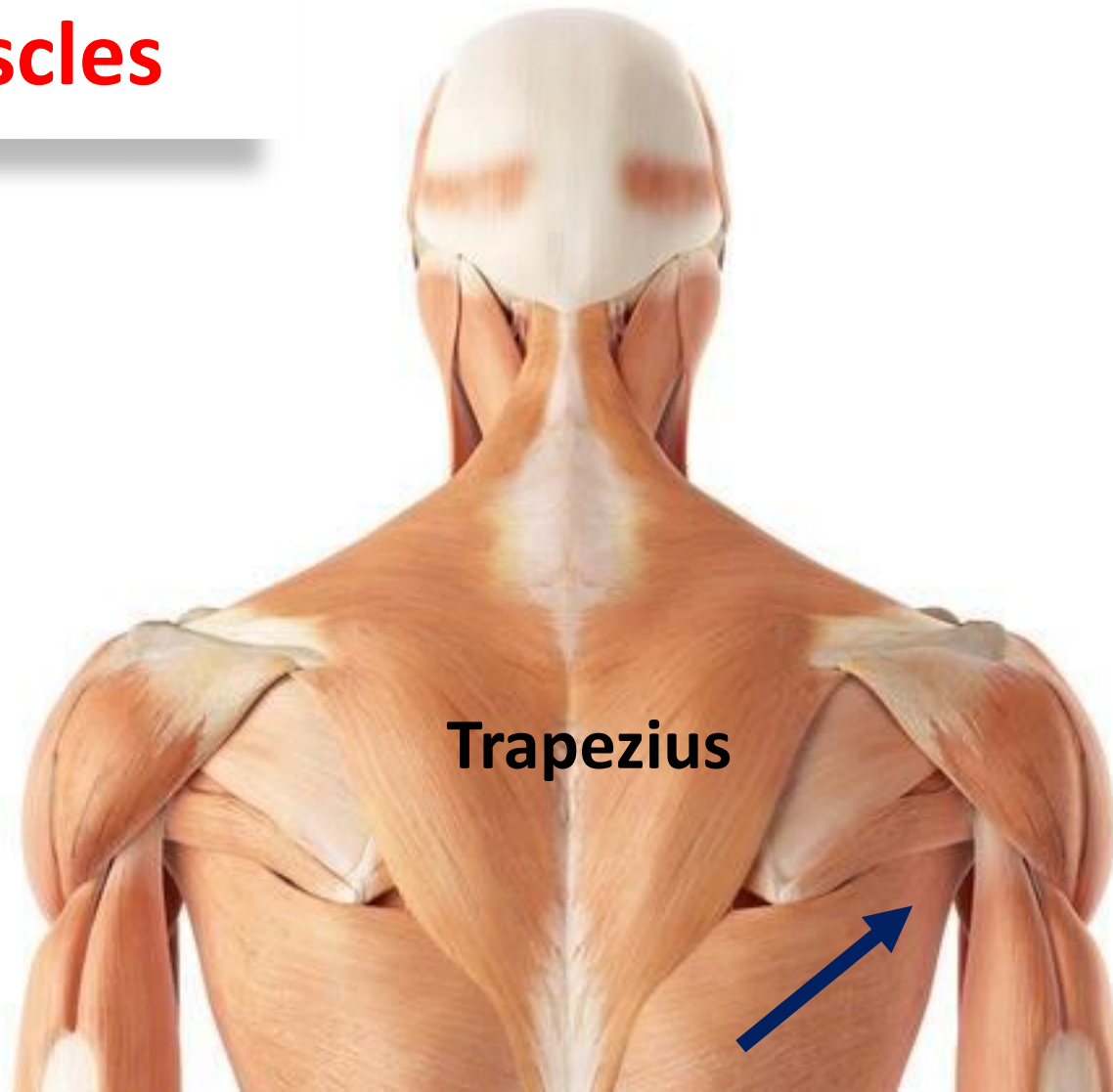




MSK1 [selected by D/ Manar Ali Faried]

THE BACK

Muscles



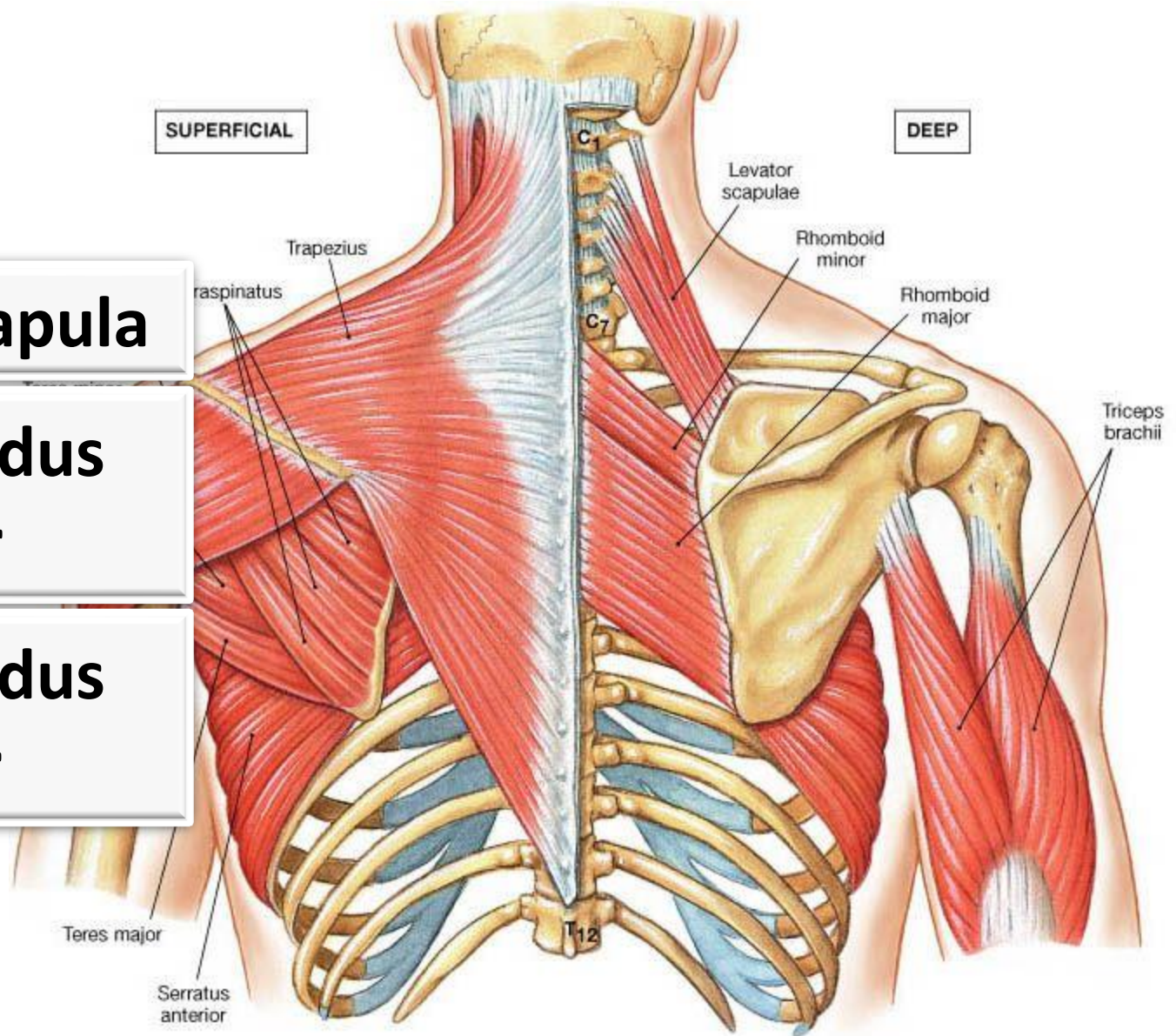
Latissimus Dorsi

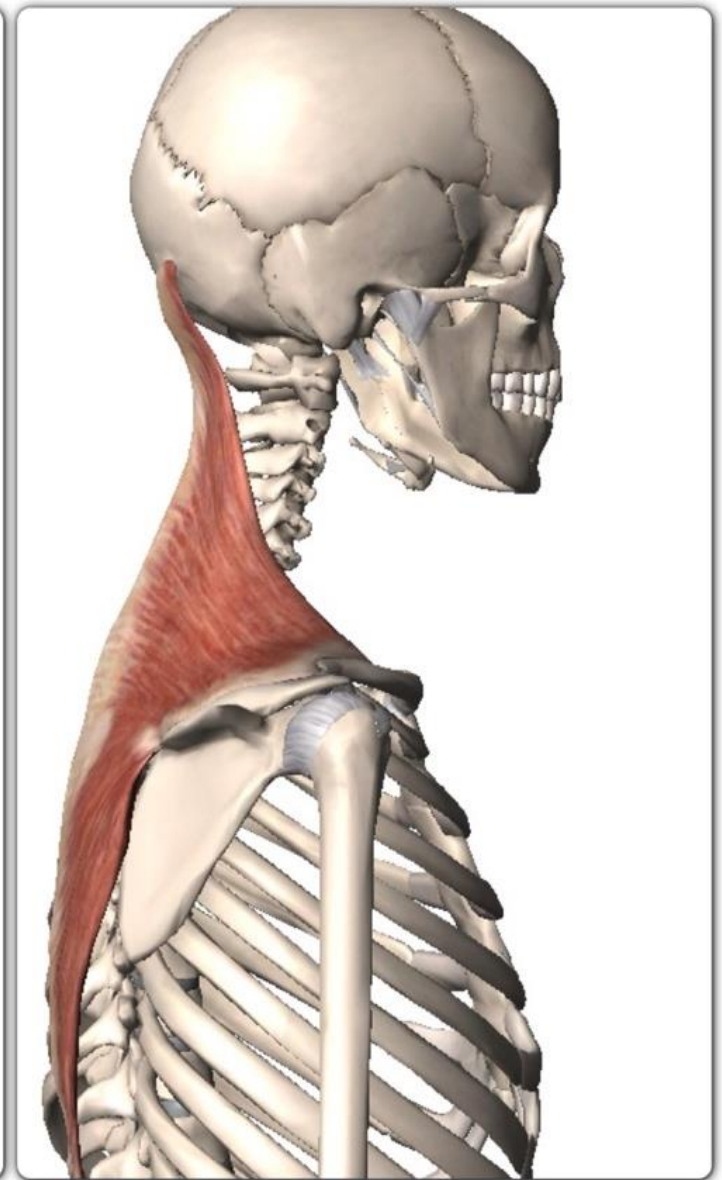
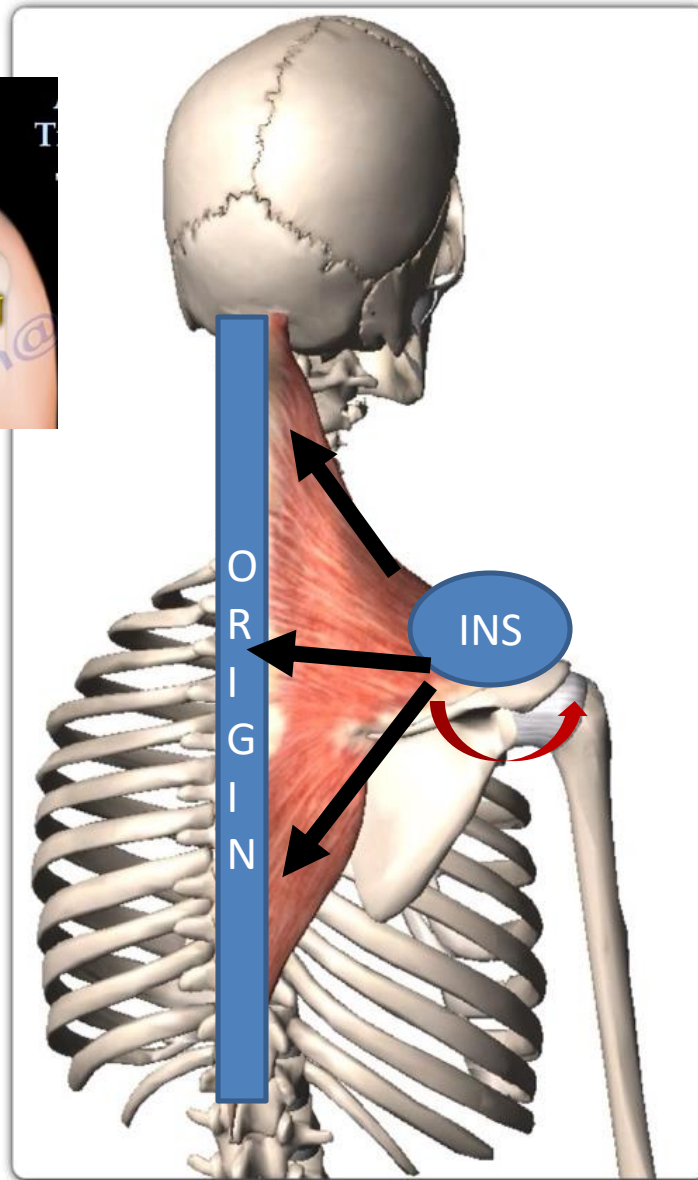
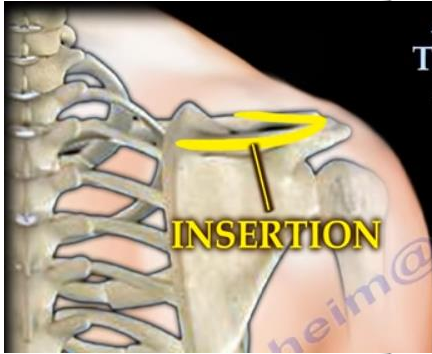
MSK1 [selected by D/ Manar Ali Faried]

Levator scapula

**Rhomboideus
minor**

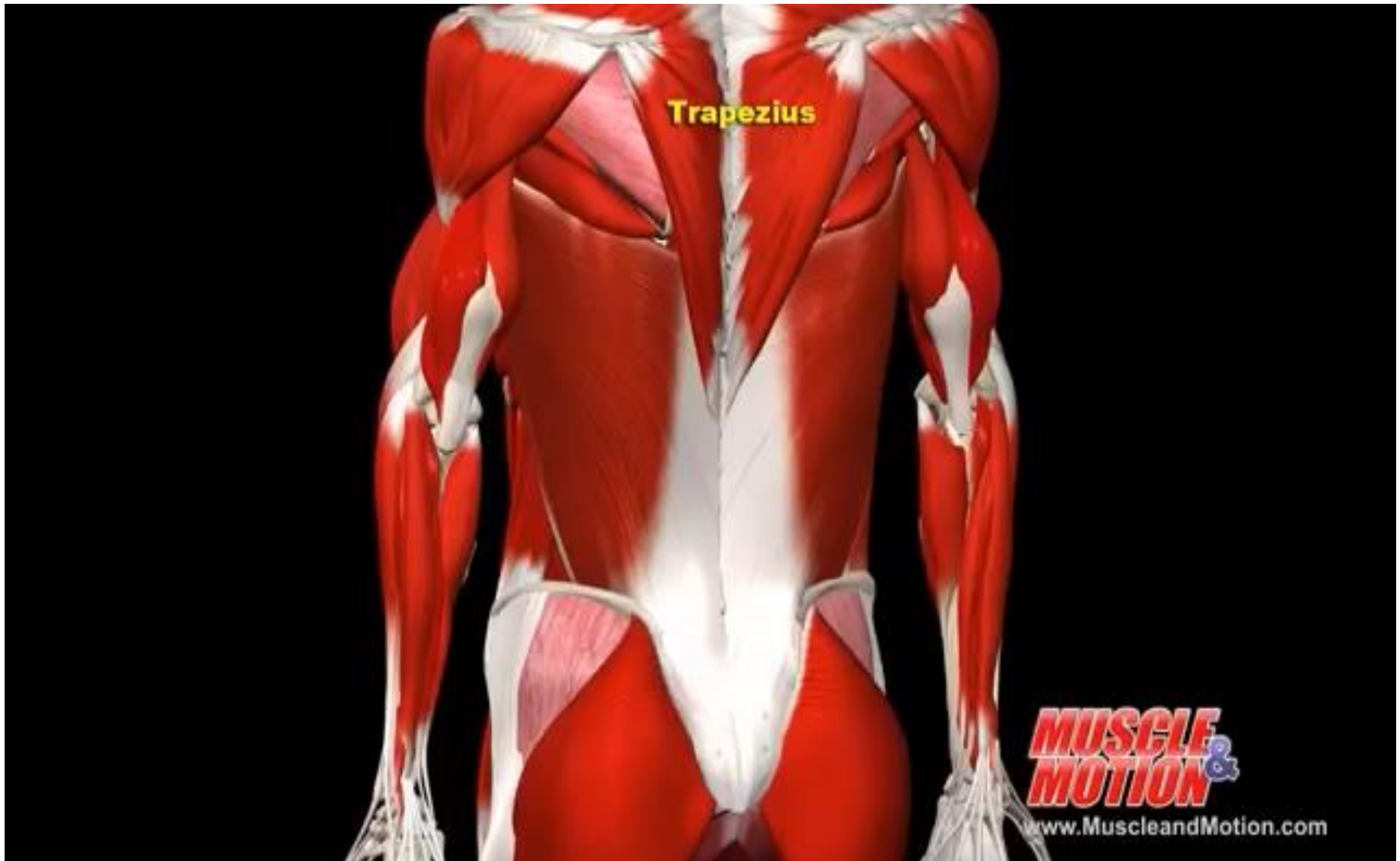**Rhomboideus
major**



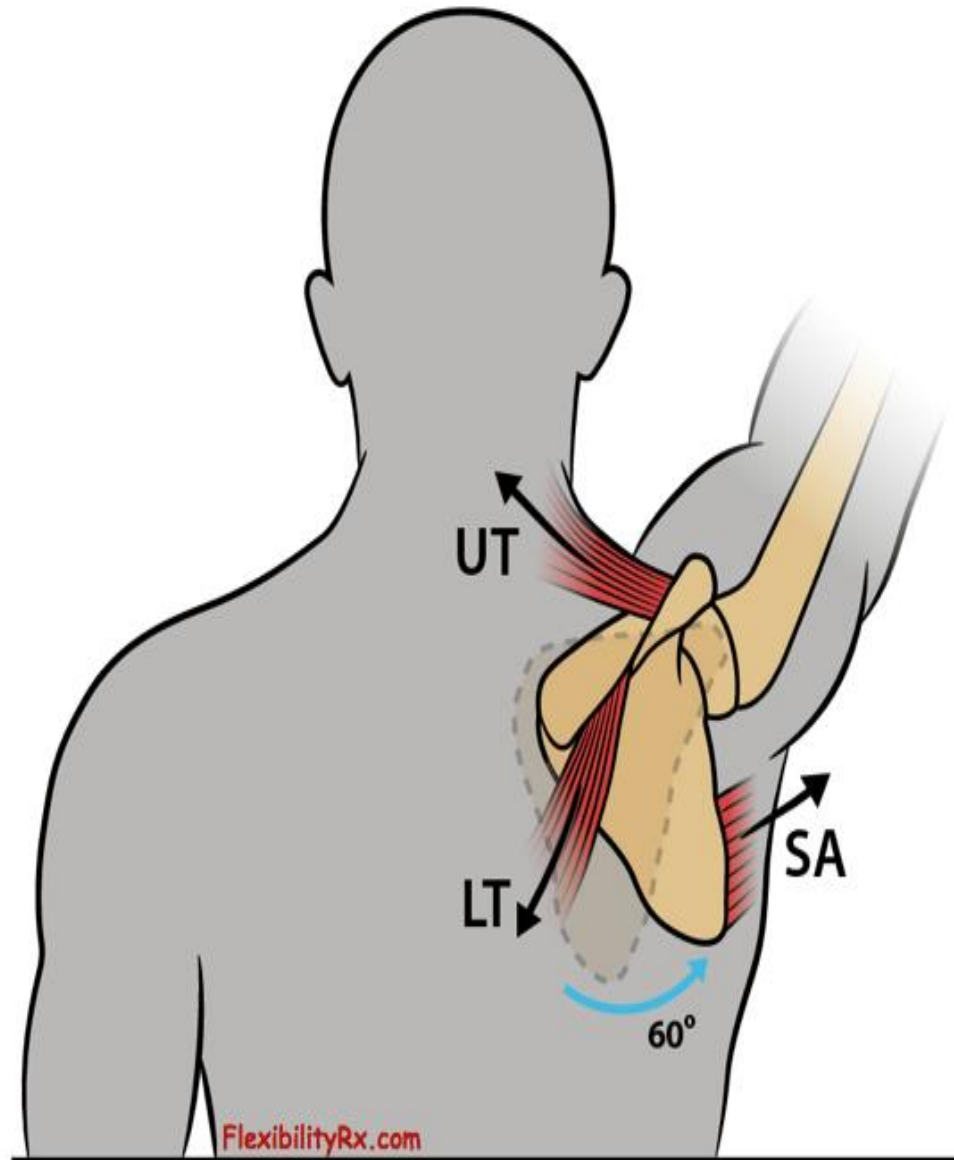


The Trapezius Muscle

MSK1 [selected by D/ Manar Ali Faried]



MSK1 [selected by D/ Manar Ali Faried]



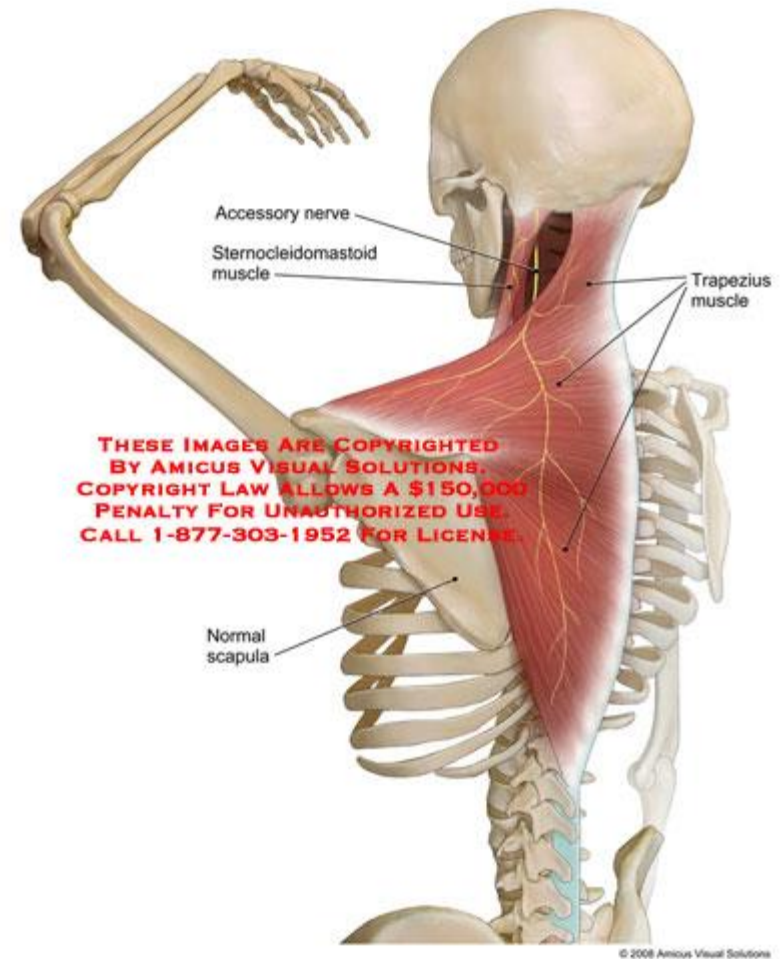
upward rotation: (UT) Upper Trap:
(LT) Lower Trap: (SA) Serratus Anterior

[UpK1 (referred by D. J. W. and M. H. Paried)]

Nerve supply

**Spinal
accessory
N**

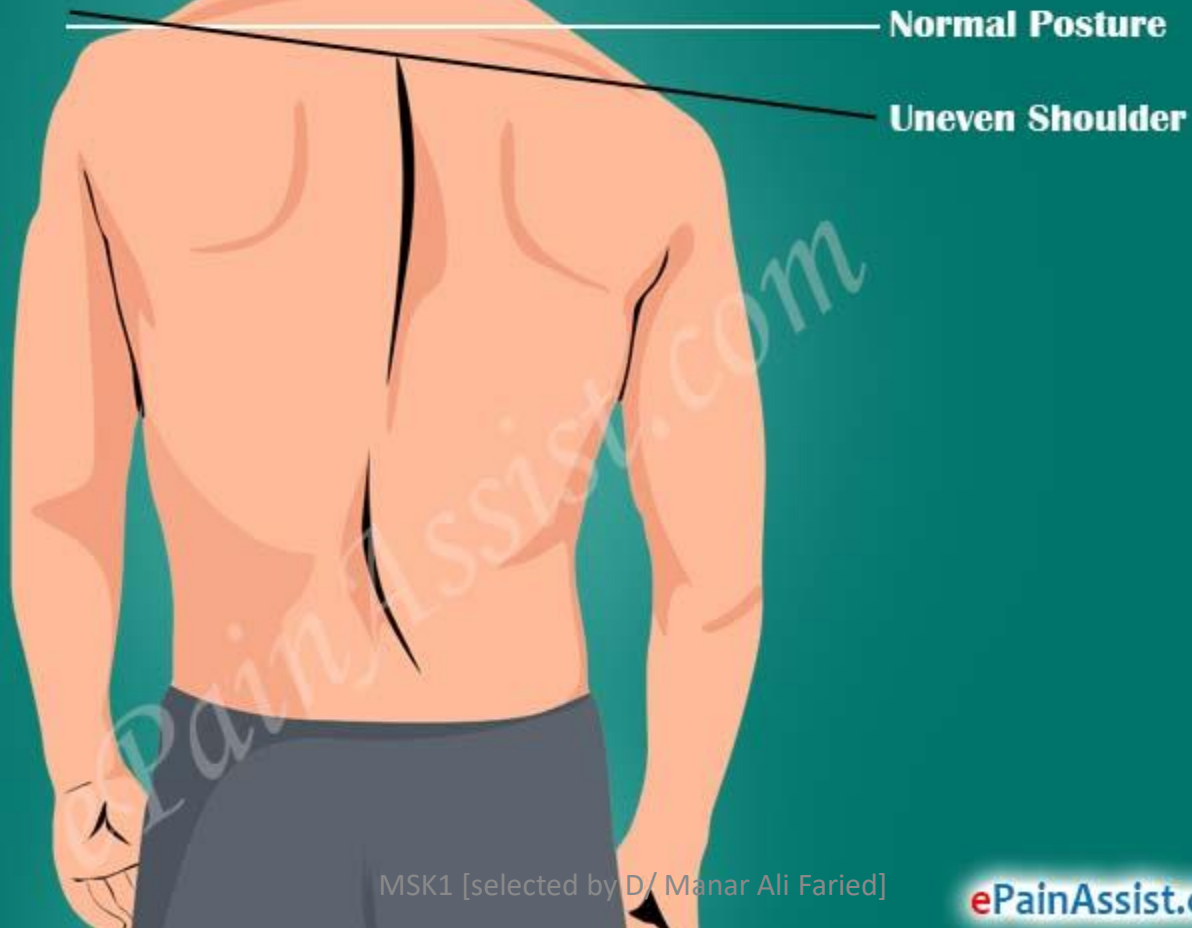
Muscles Innervated by the Accessory Nerve



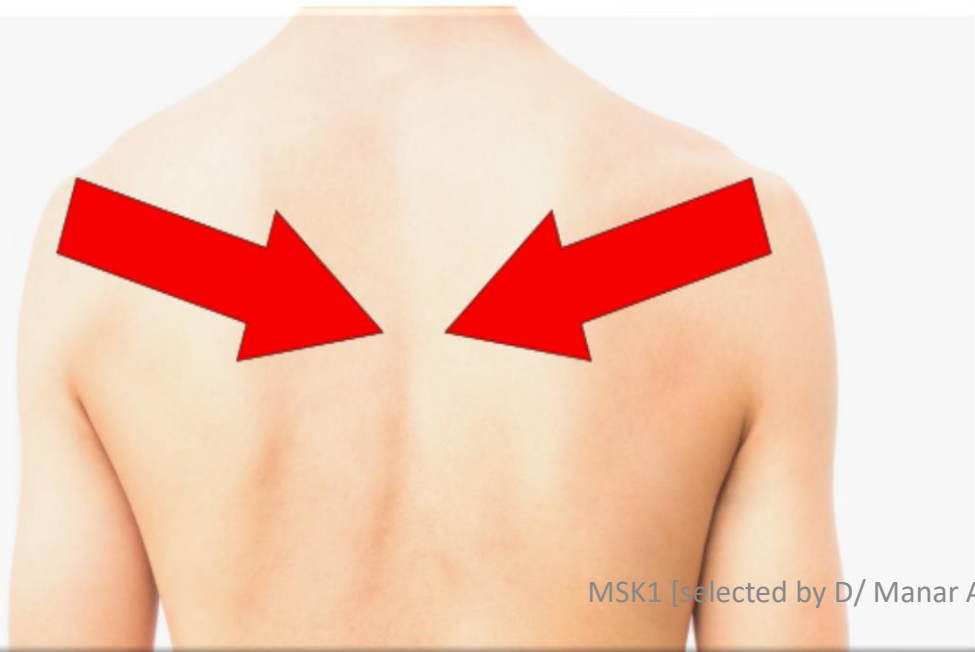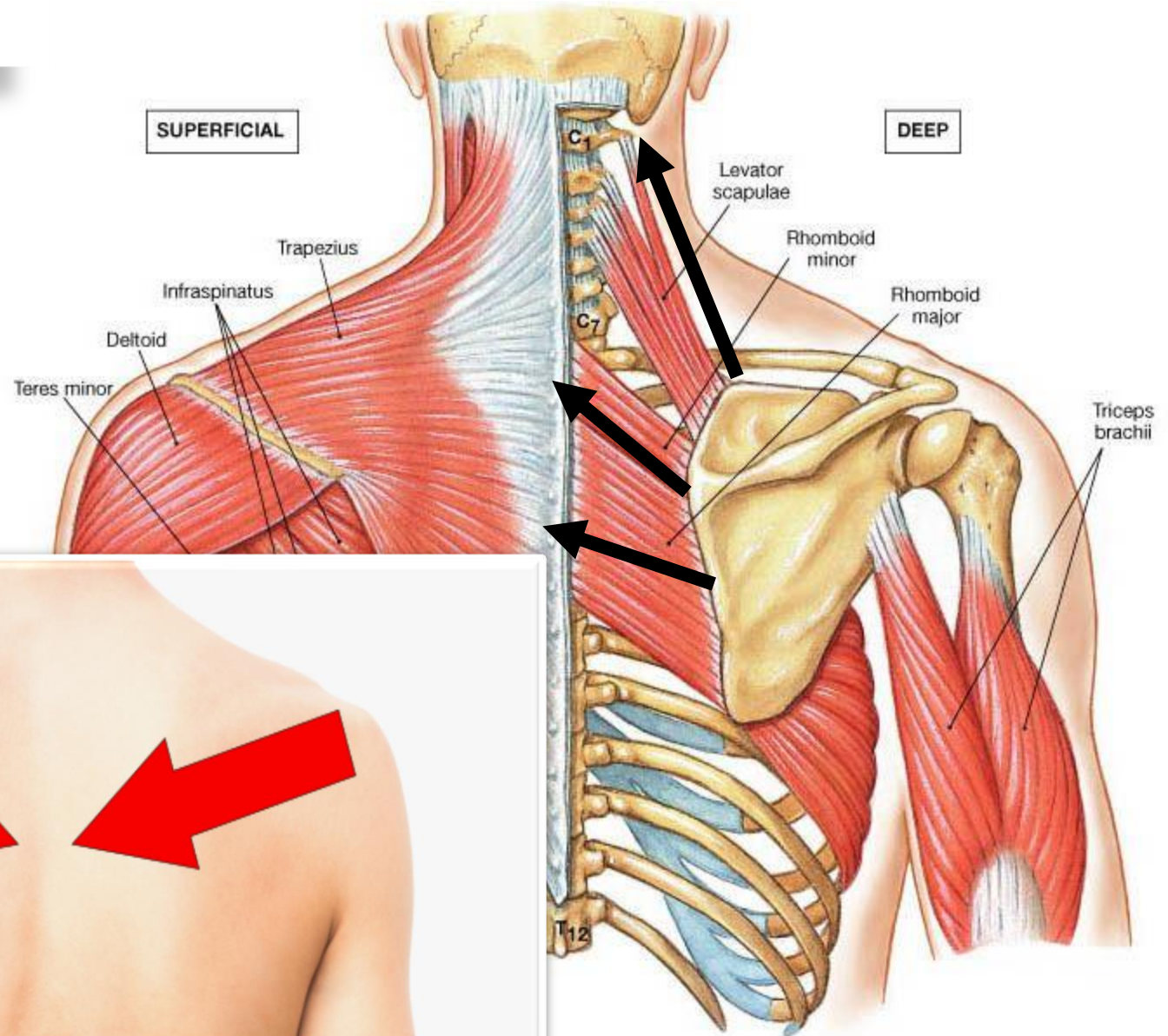
Uneven Shoulder

Uneven shoulder is an abnormal condition, where an asymmetry is noted between both shoulders.

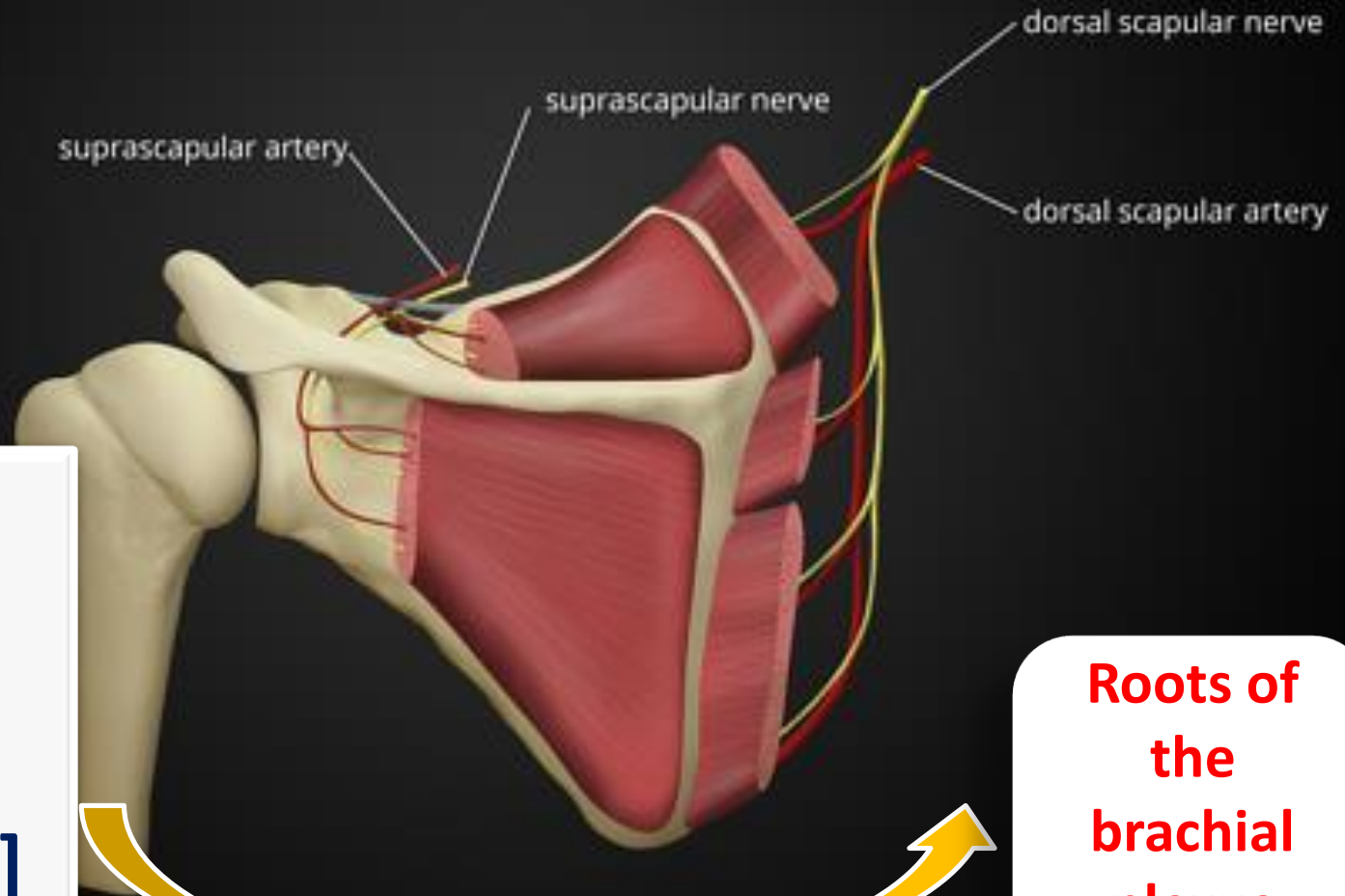
For More Information:
Visit: www.epainassist.com



Action



Nerve supply



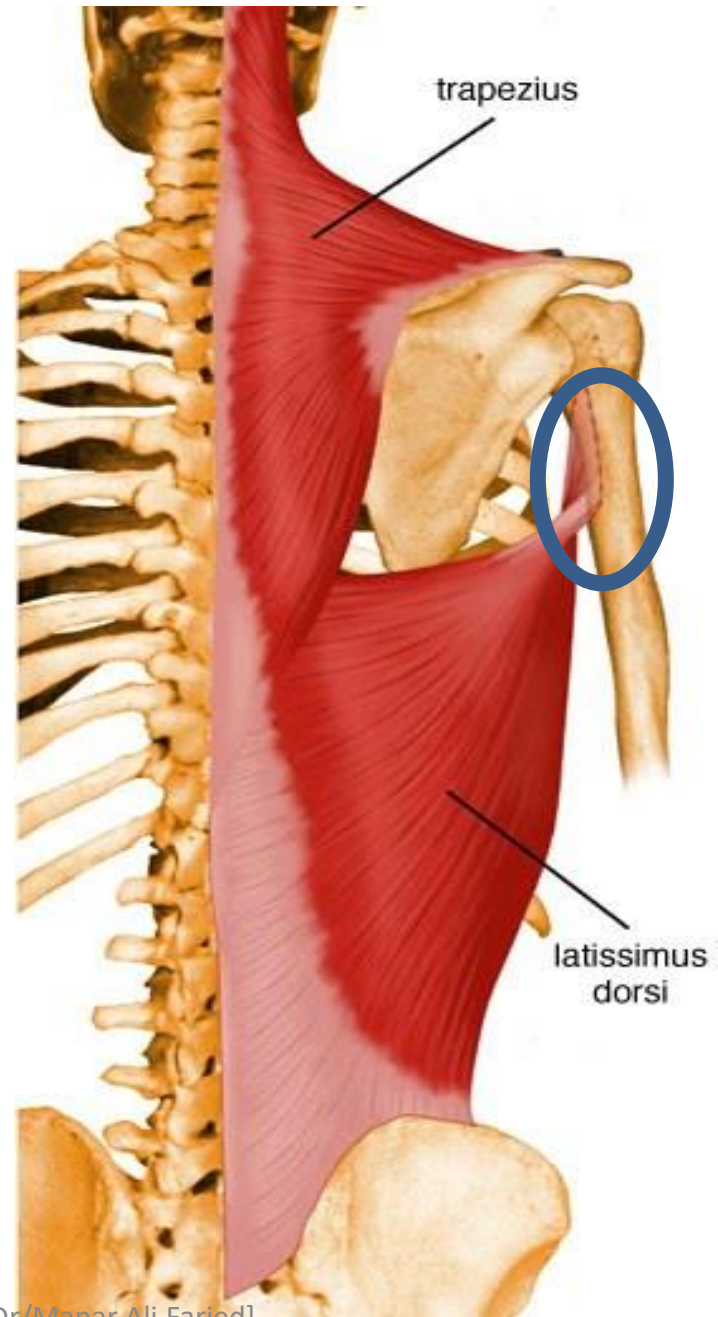
**Dorsal
scapular
[N to
rhomboid]**

**Roots of
the
brachial
plexus
C5**

LECTURE [4]

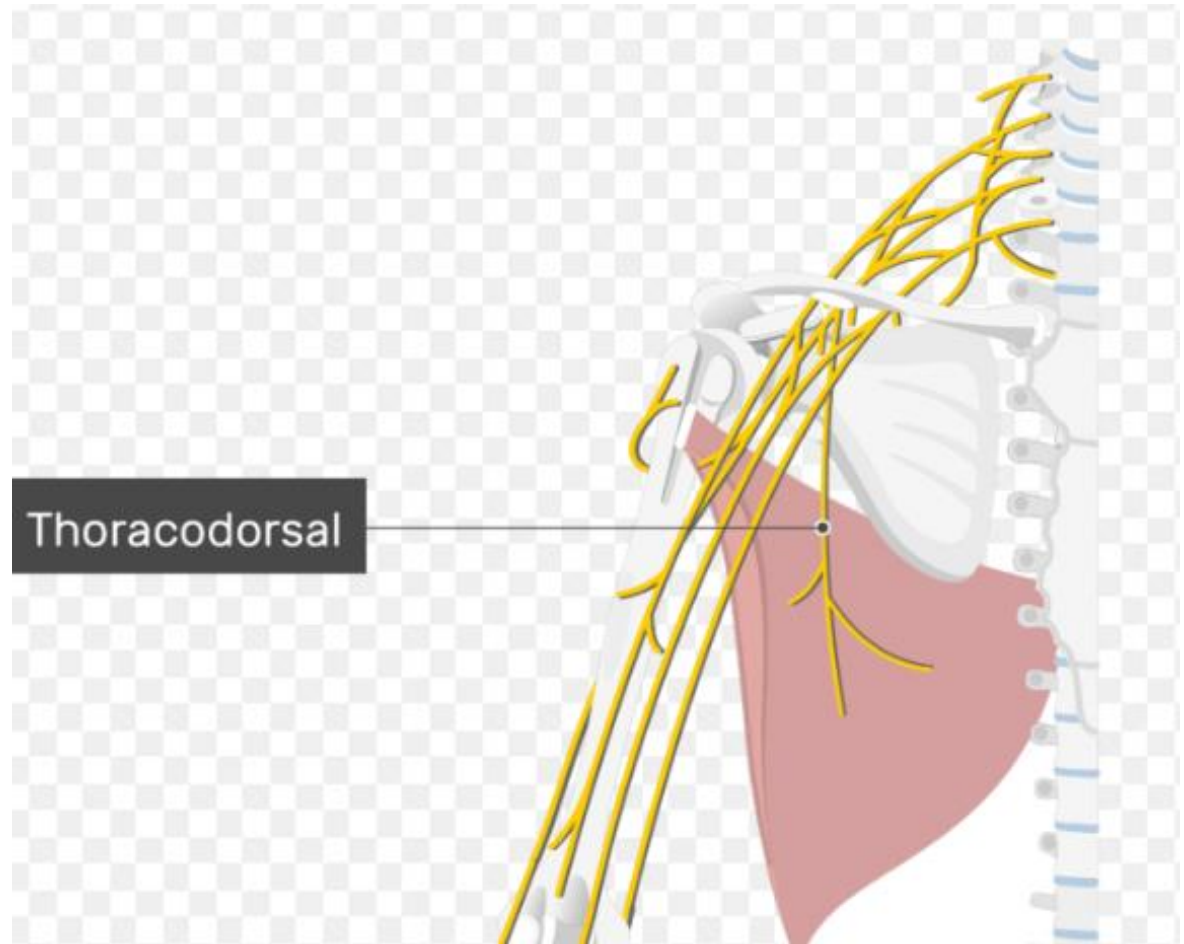
MUSCLE OF THE BACK ACTING ON THE SHOULDER JOINT

Latissimus Dorsi



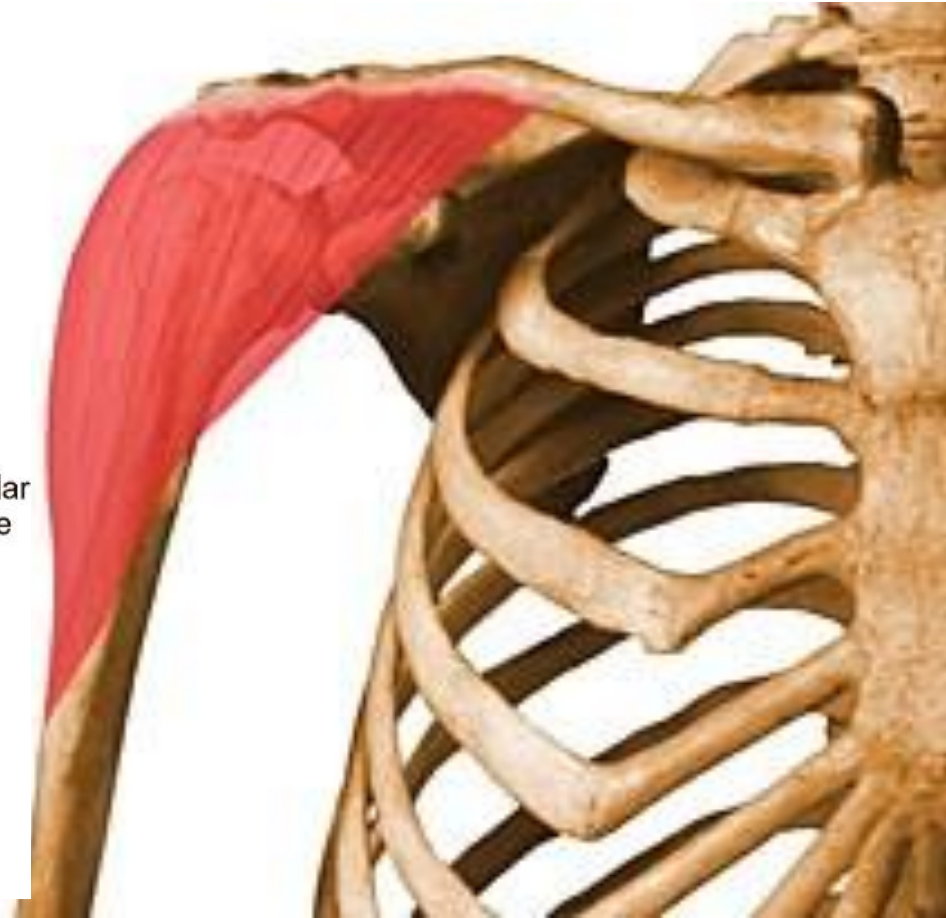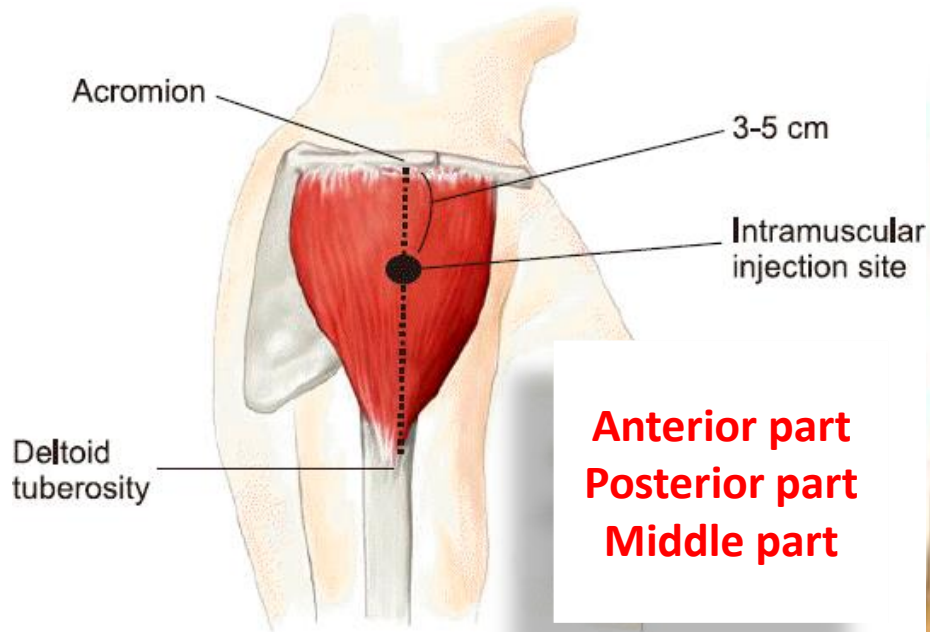
N to Latissimus Dorsi (Thoracodorsal)

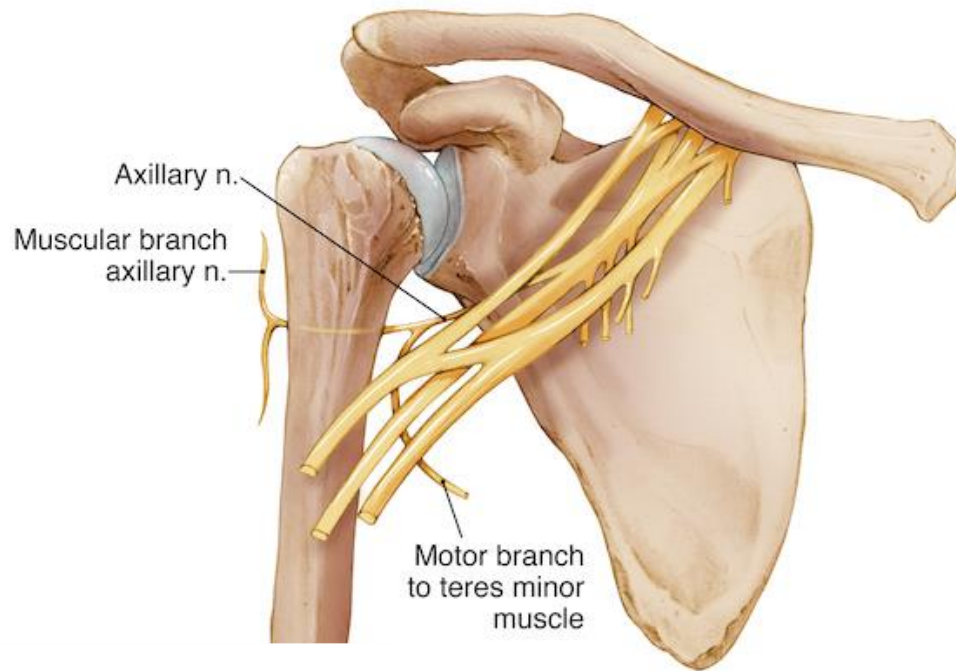
Posterior cord
C6,7,8



SCAPULAR / SHOULDER REGION

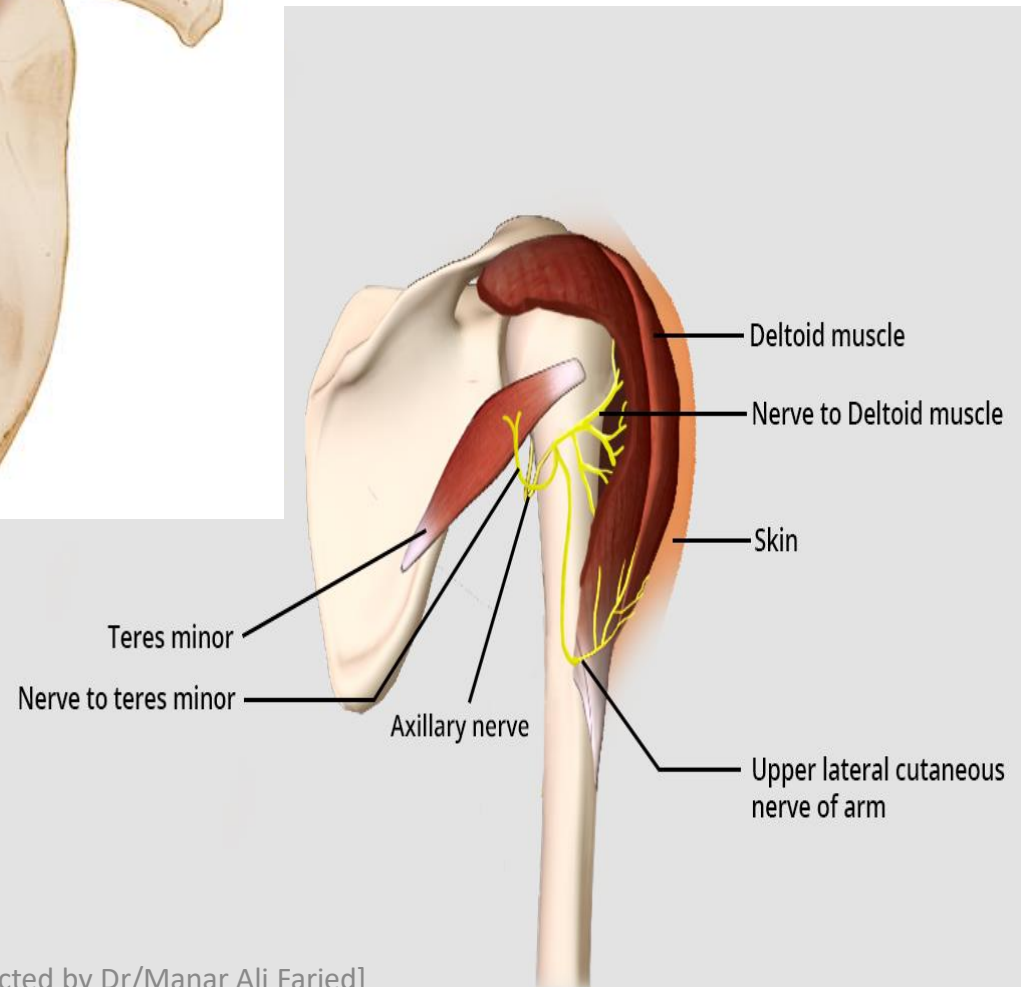
Deltoid





Axillary N
C5,6

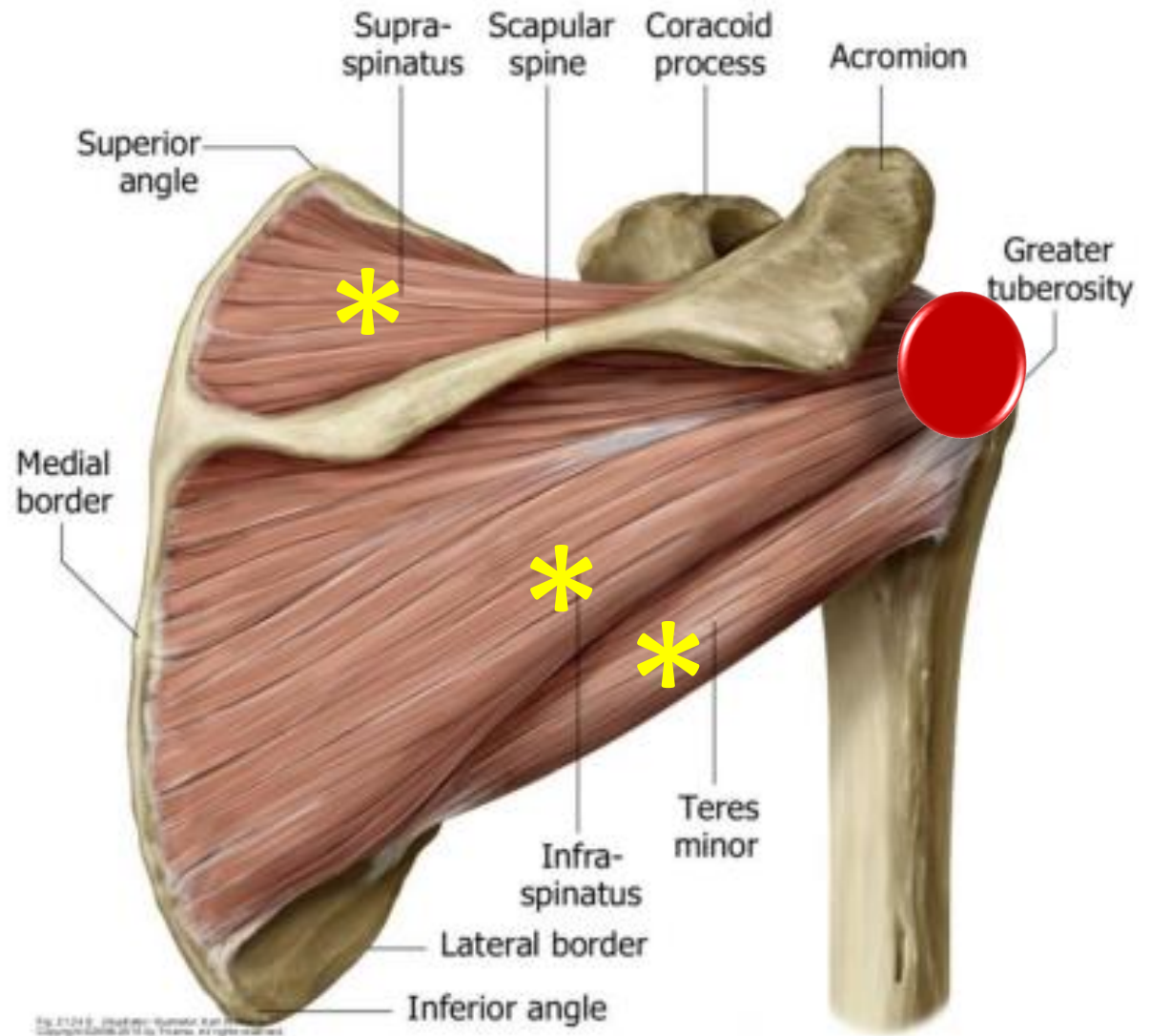
Posterior
cord



Supraspinatus

Infraspinatus

Teres minor

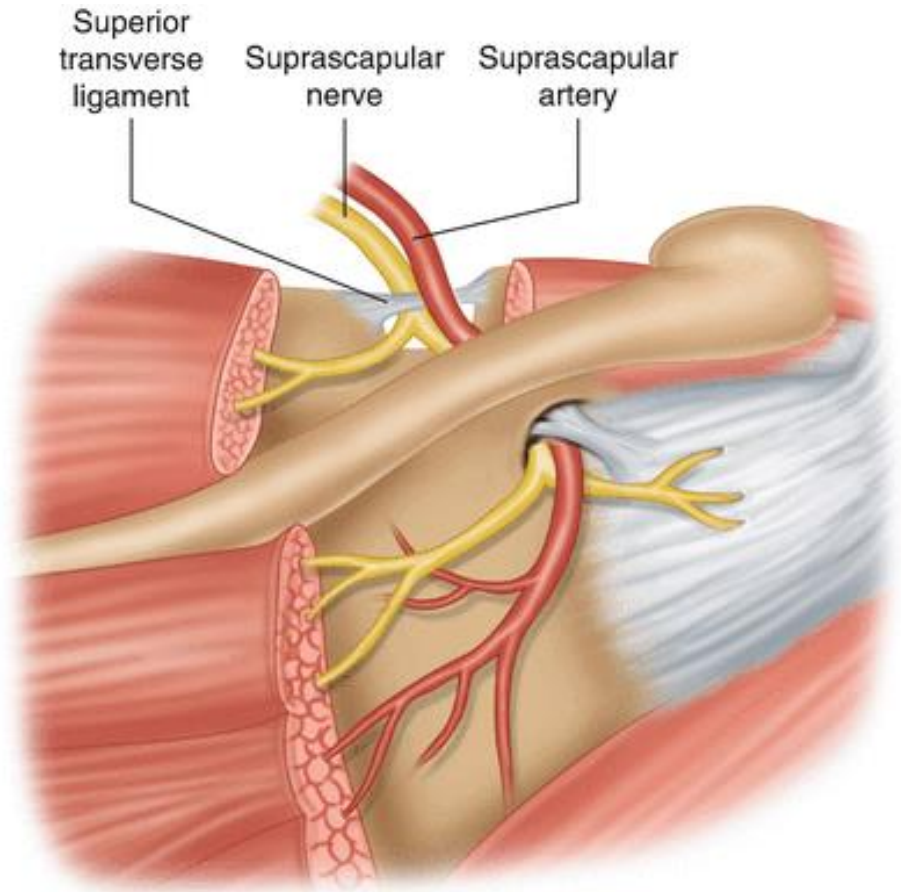


Posterior View

Nerve Supply

Suprascapular N
C5,6

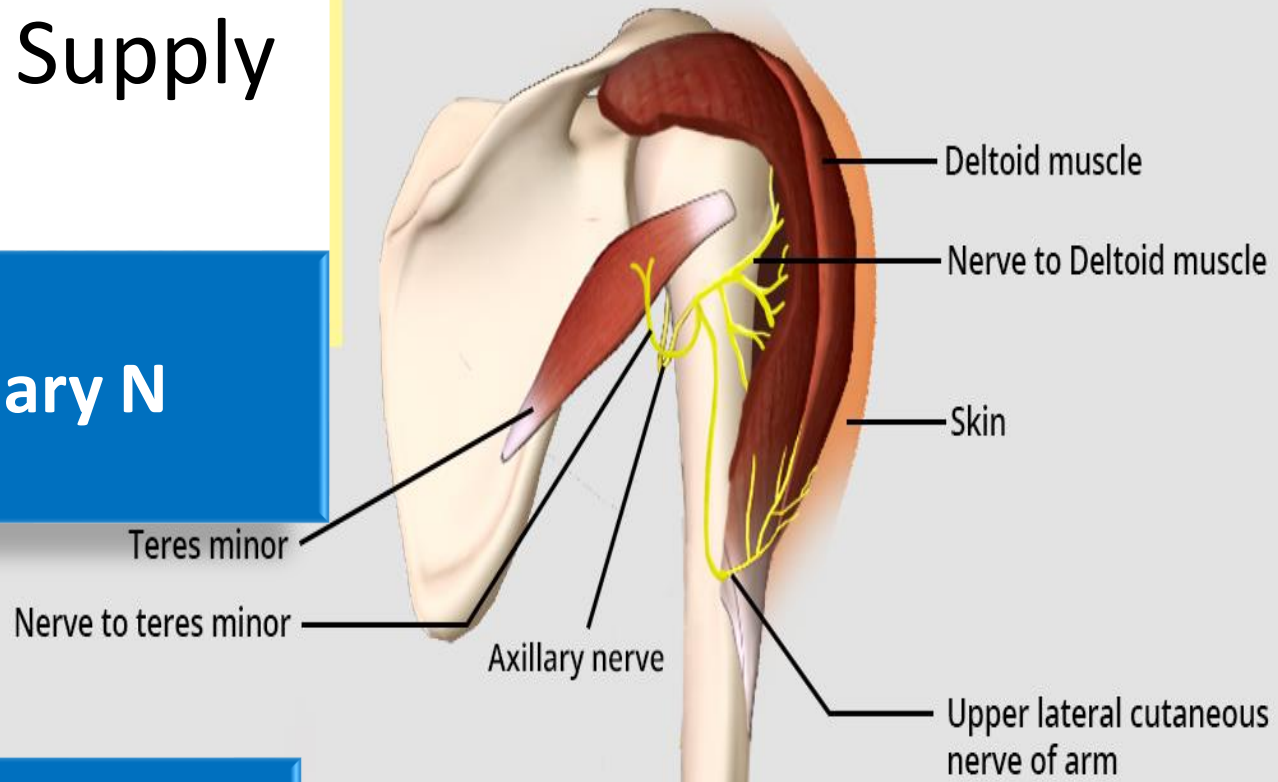
Upper trunk



Supraspinatus
Infraspinatus
ms

Nerve Supply

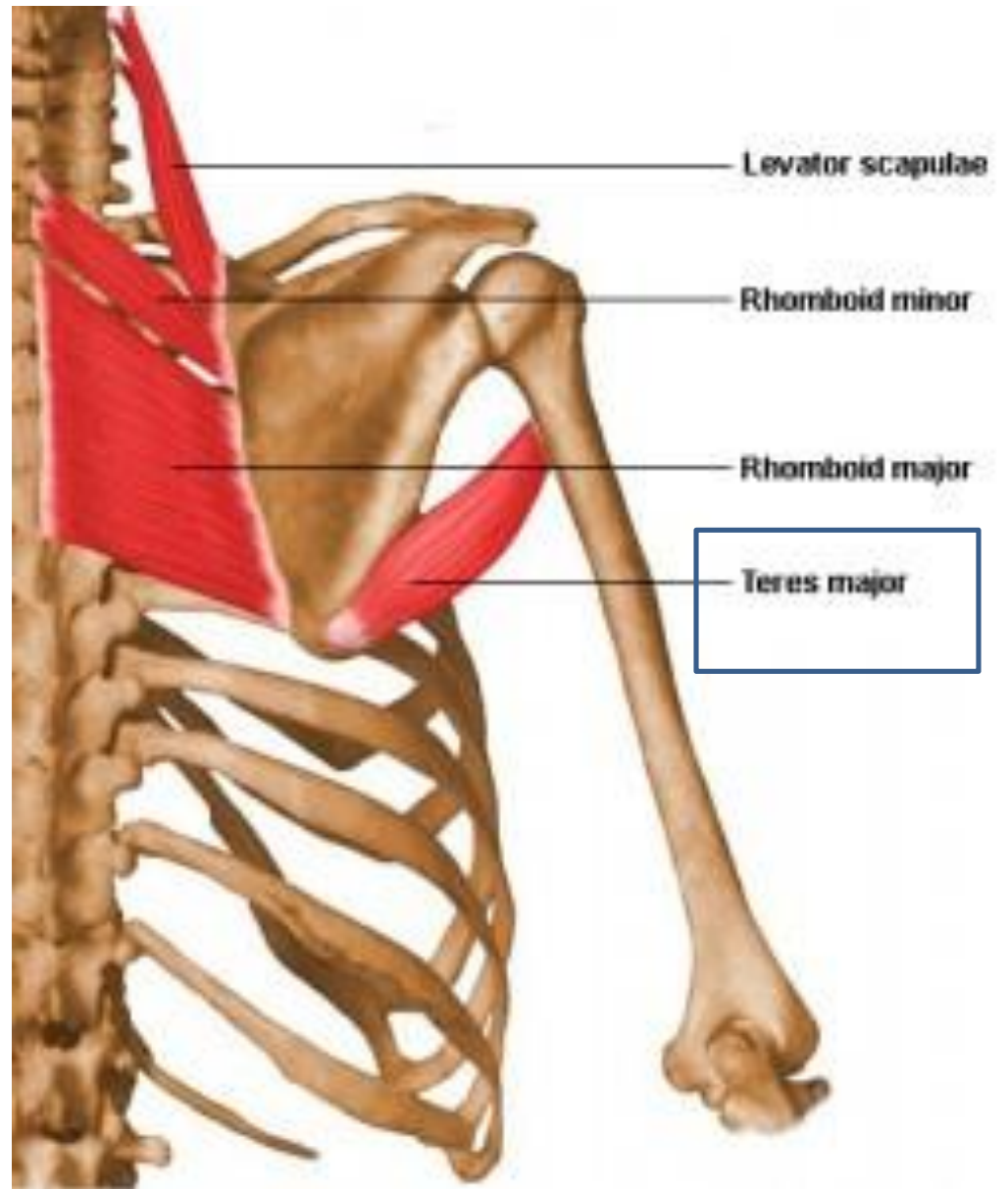
Axillary N



Posterior cord

**Teres minor
ms**

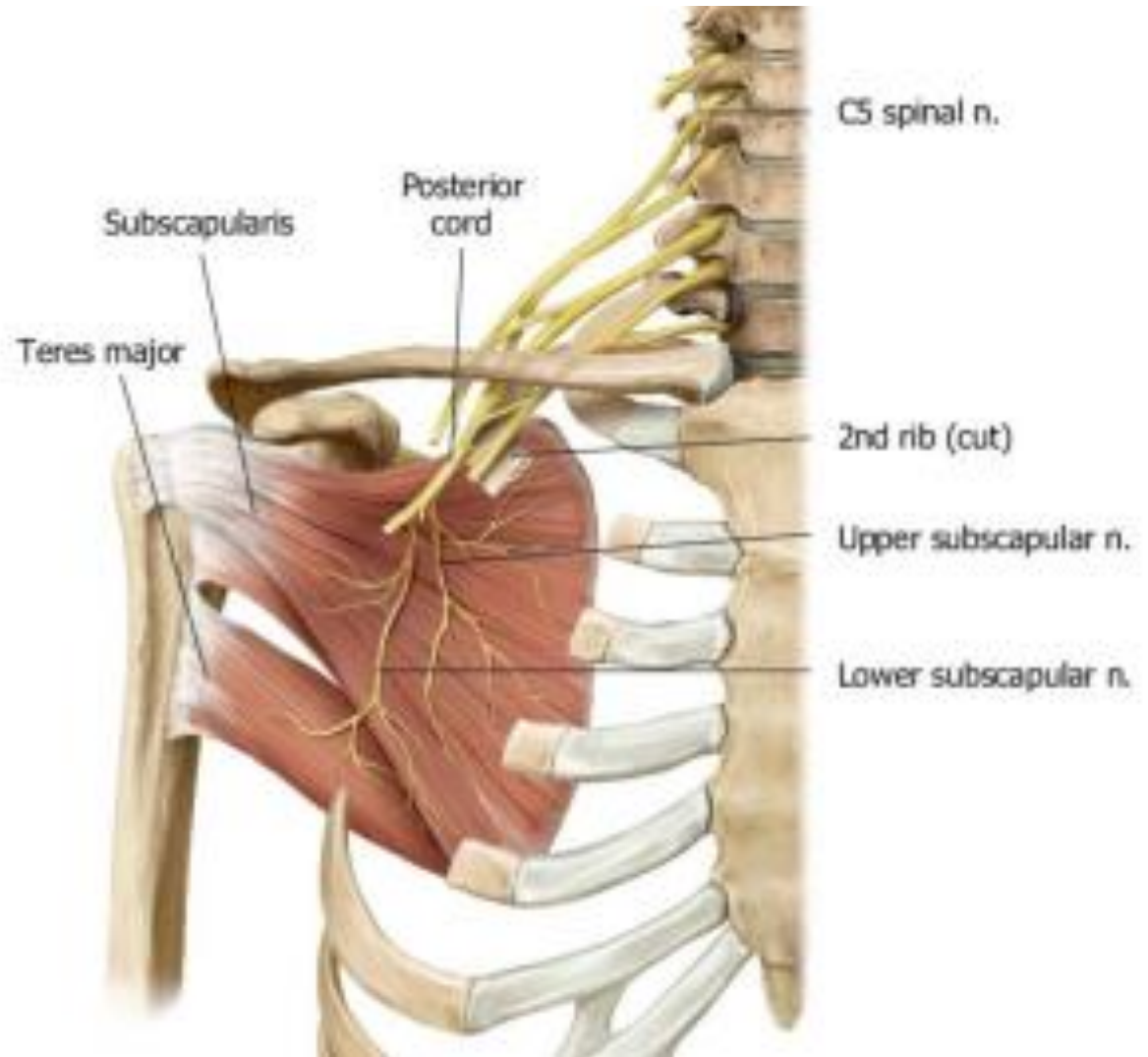
Teres major



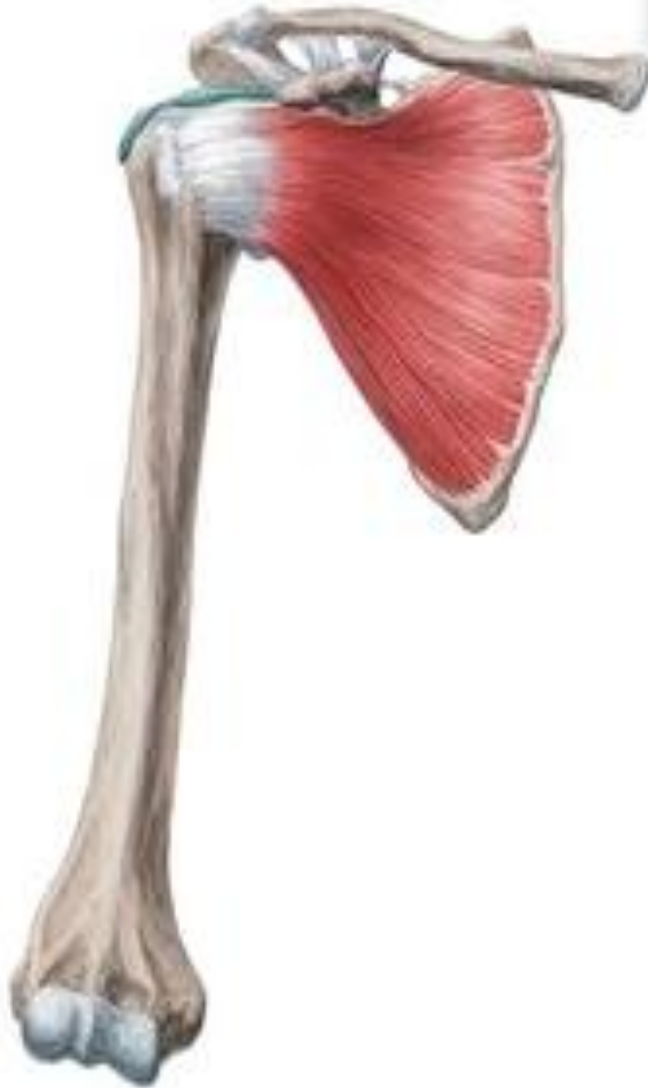Nerve Supply

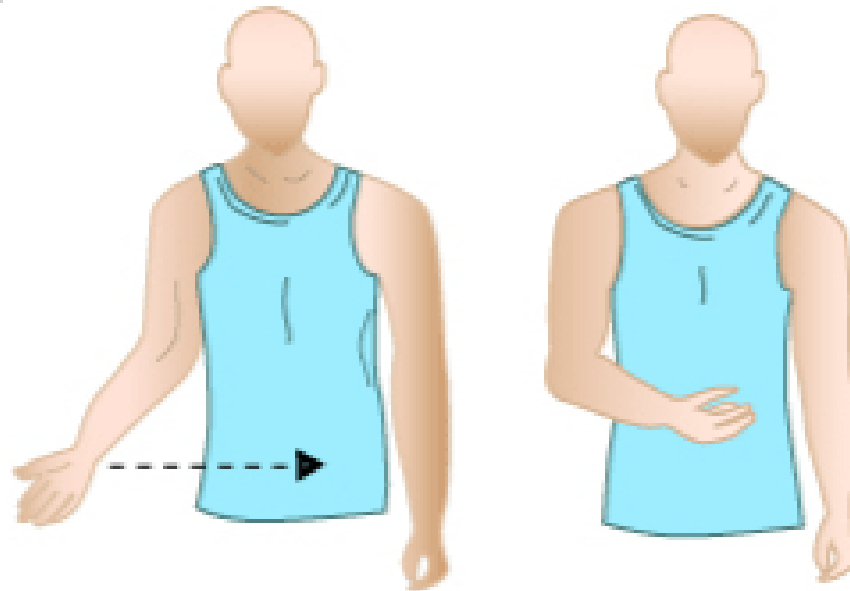
Lower
subscapular
(C5,6)

Posterior cord



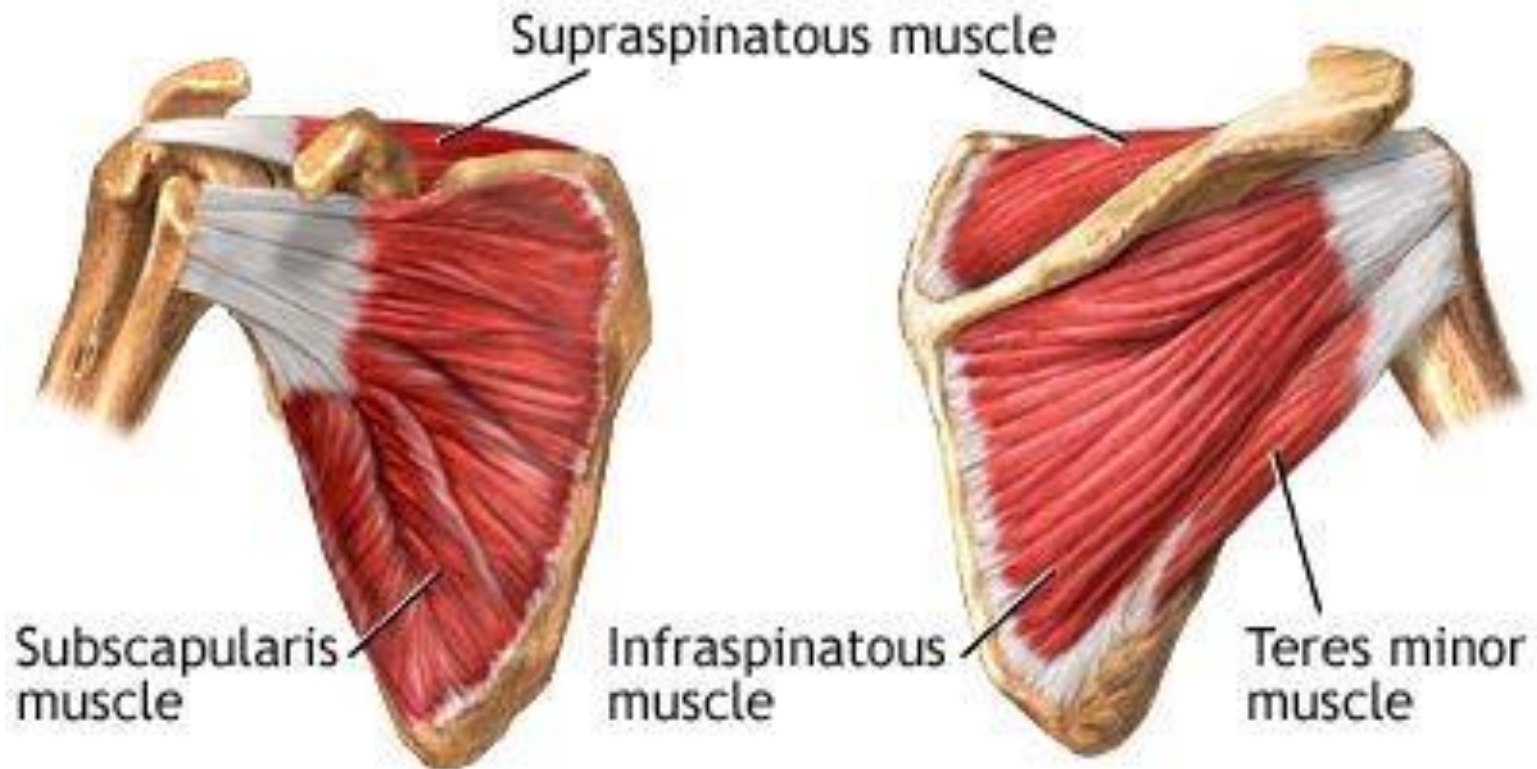
Subscapularis





The **subscapularis muscle** is used when the arm and shoulder rotate towards the body.

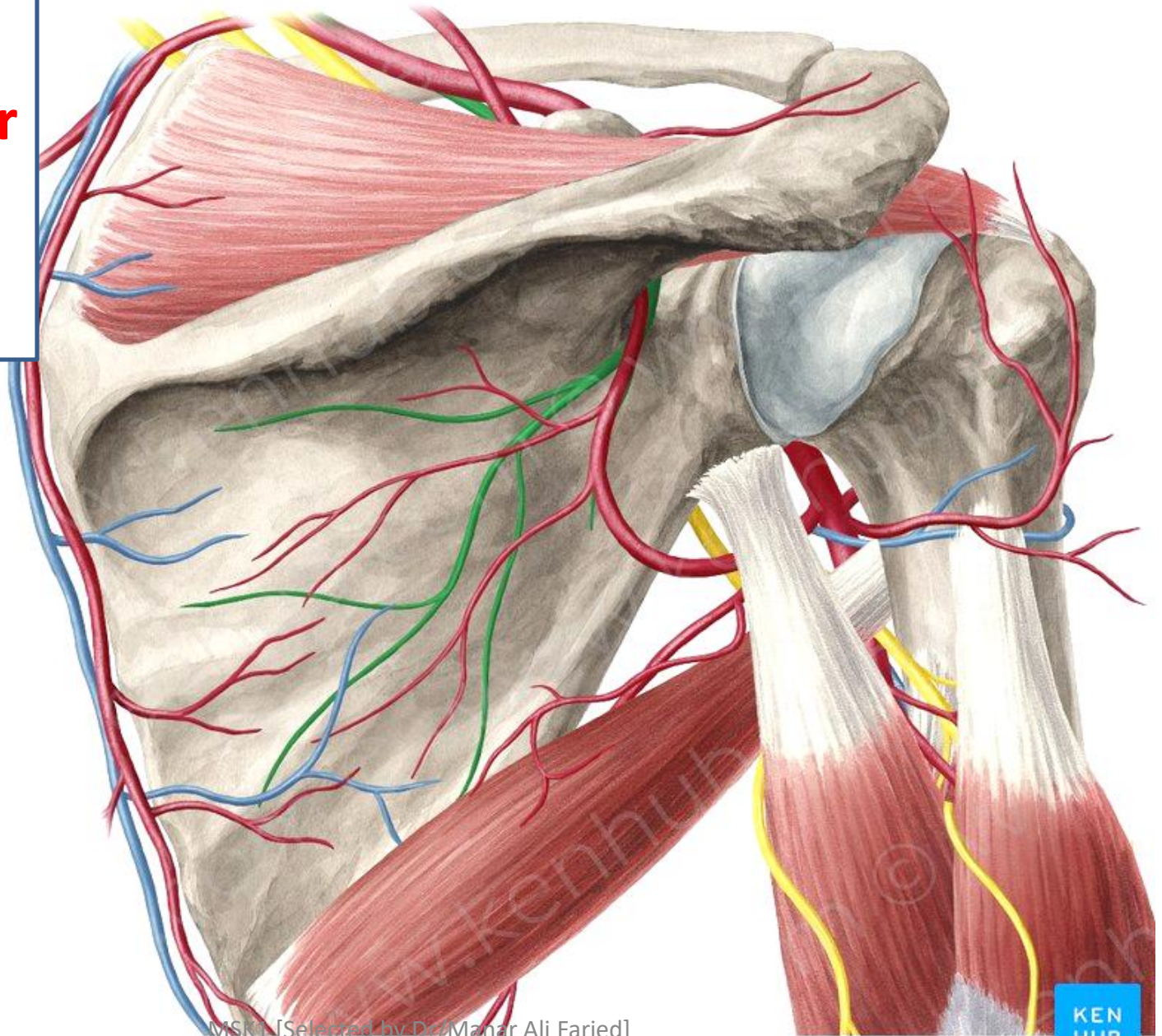
Rotator cuff muscles



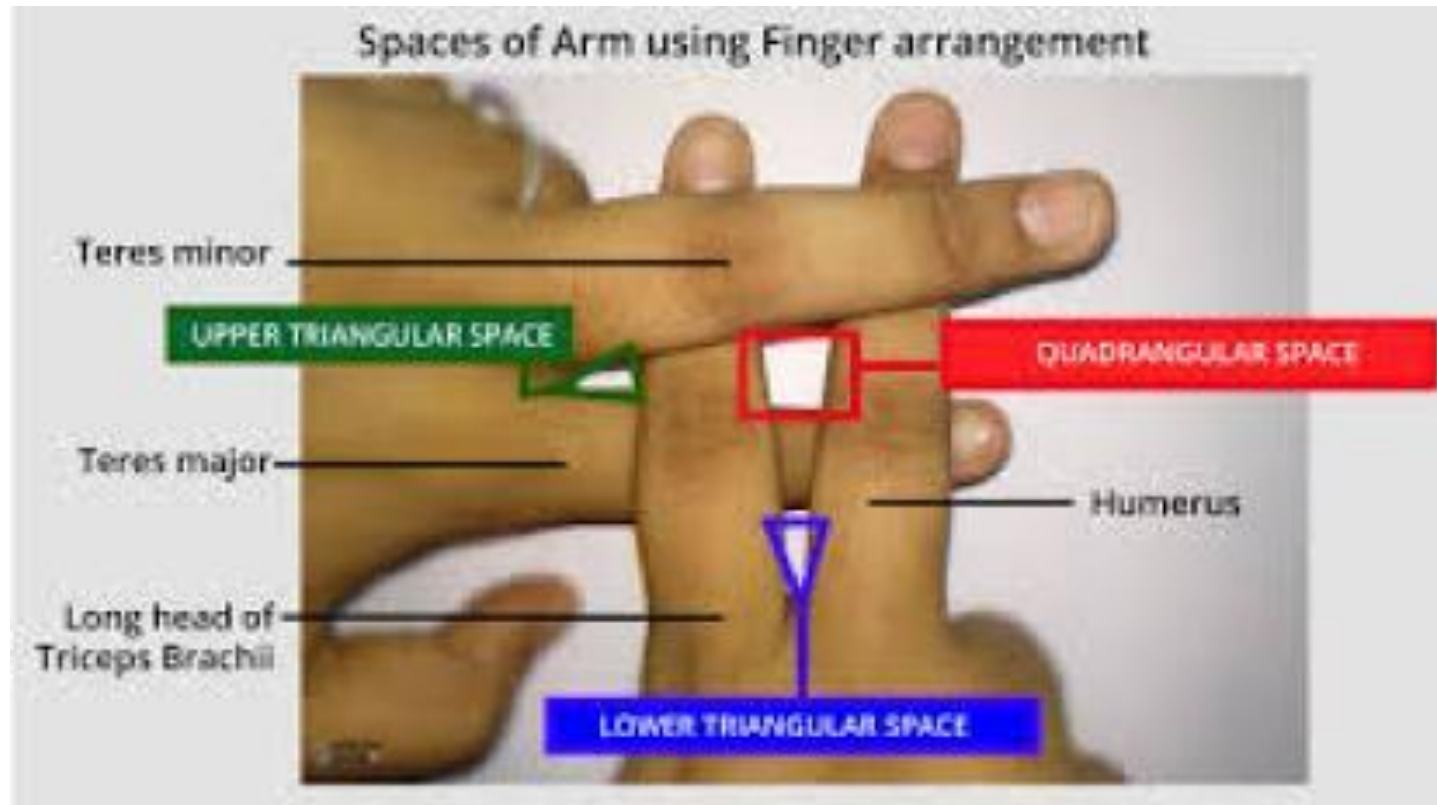
Anterior shoulder

Posterior shoulder

Intermuscular spaces

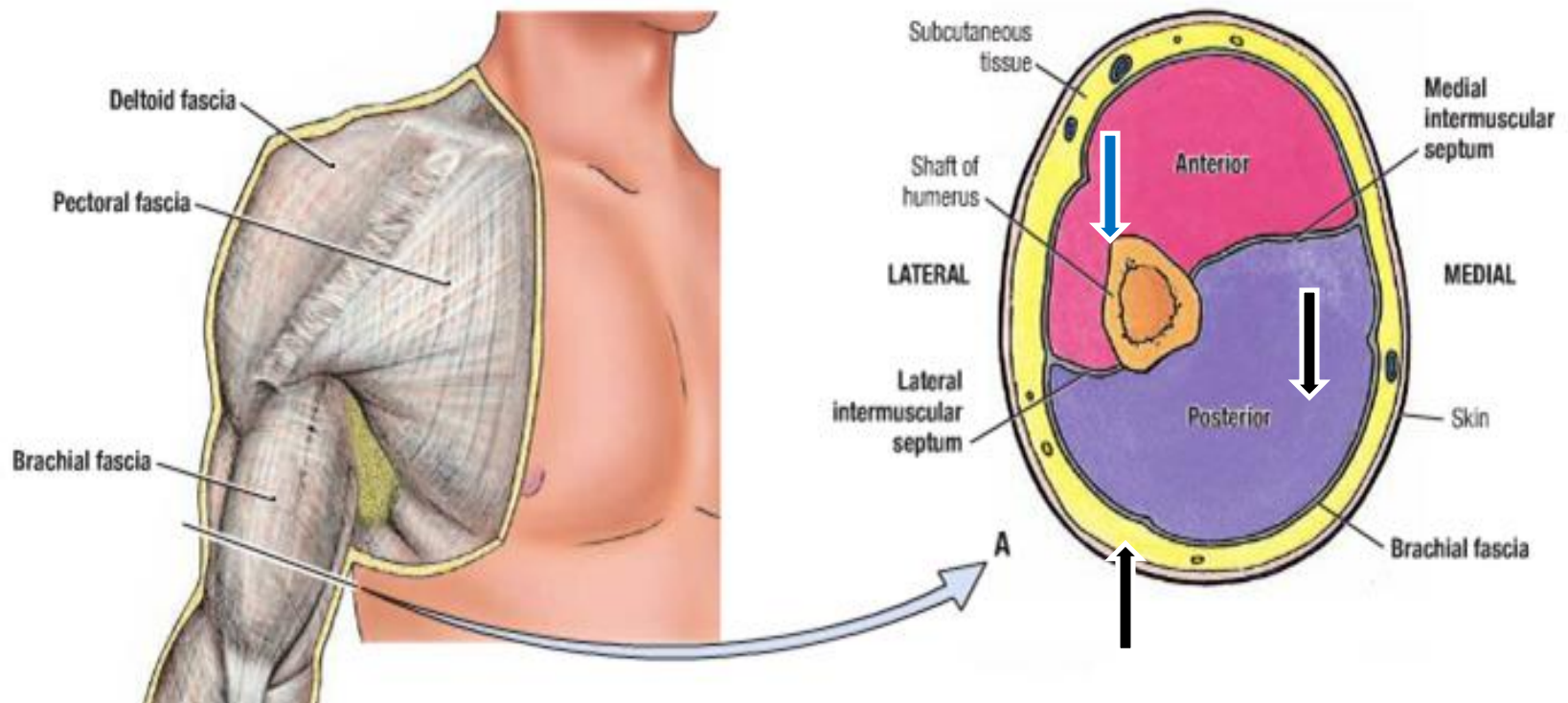


MSM [Selected by Dr/Mahar Ali Faried]

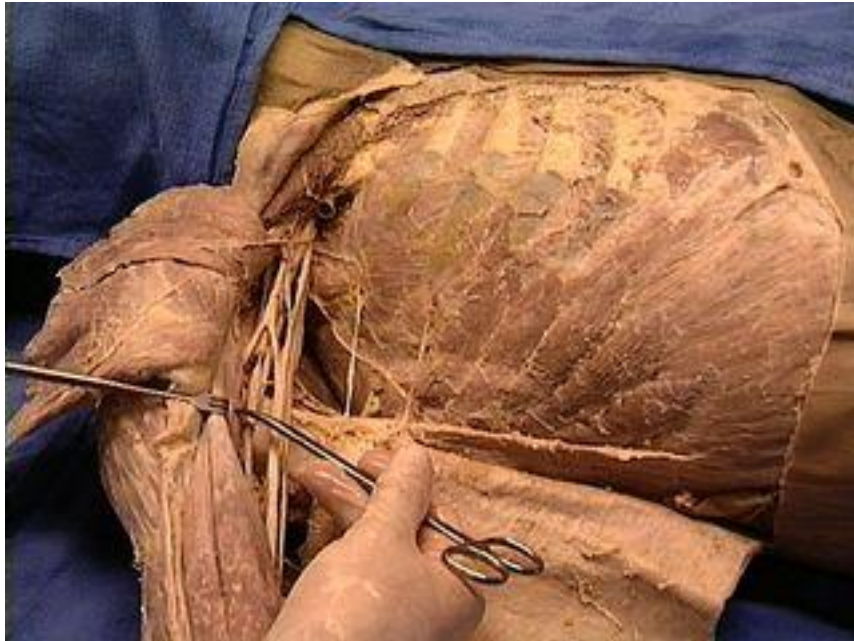

LECTURE [5]

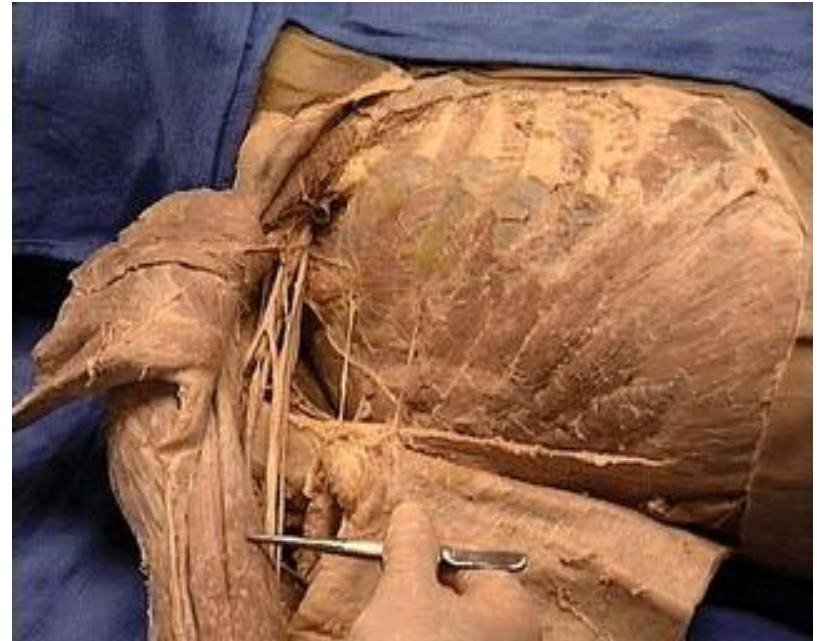ARM



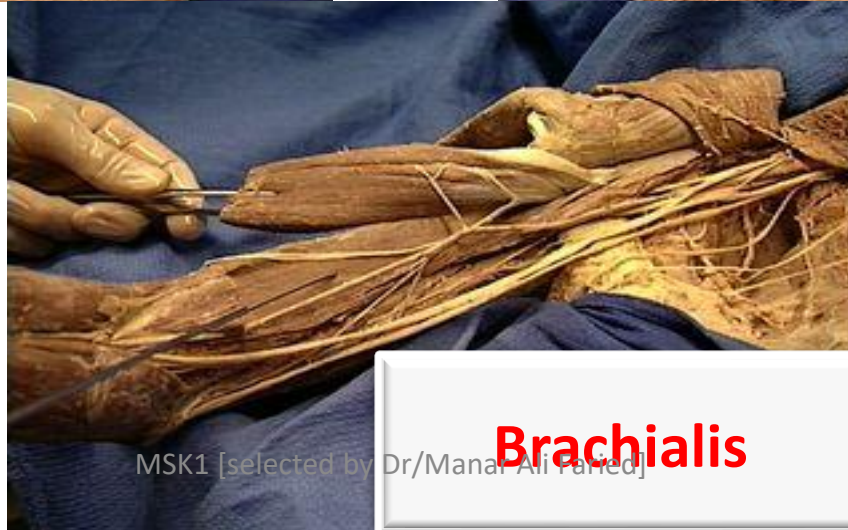{ Anterior group }



Coracobrachialis

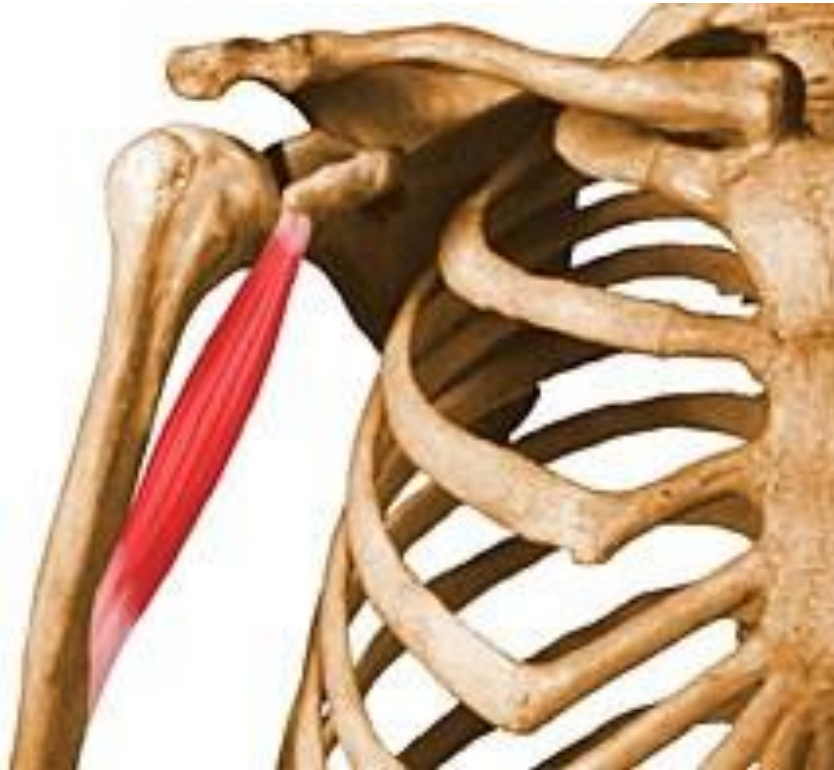

Biceps brachii

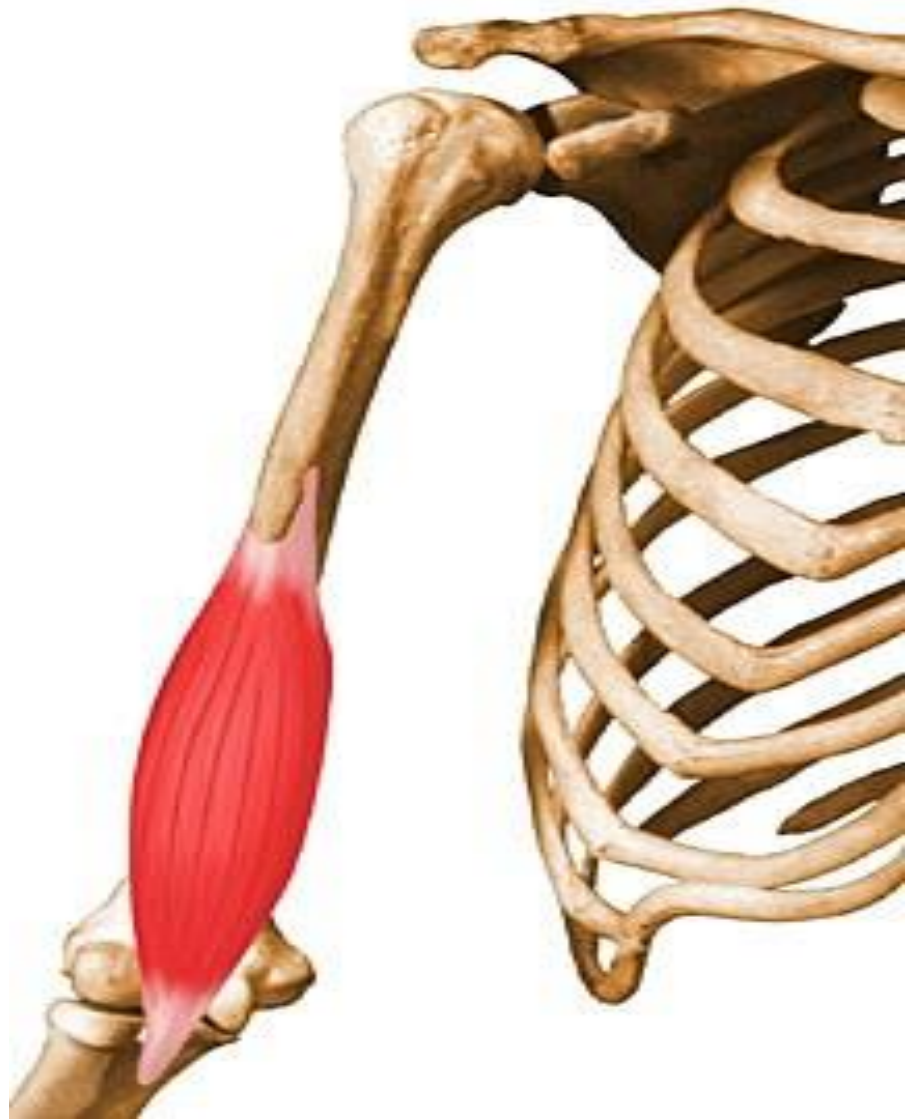

Brachialis

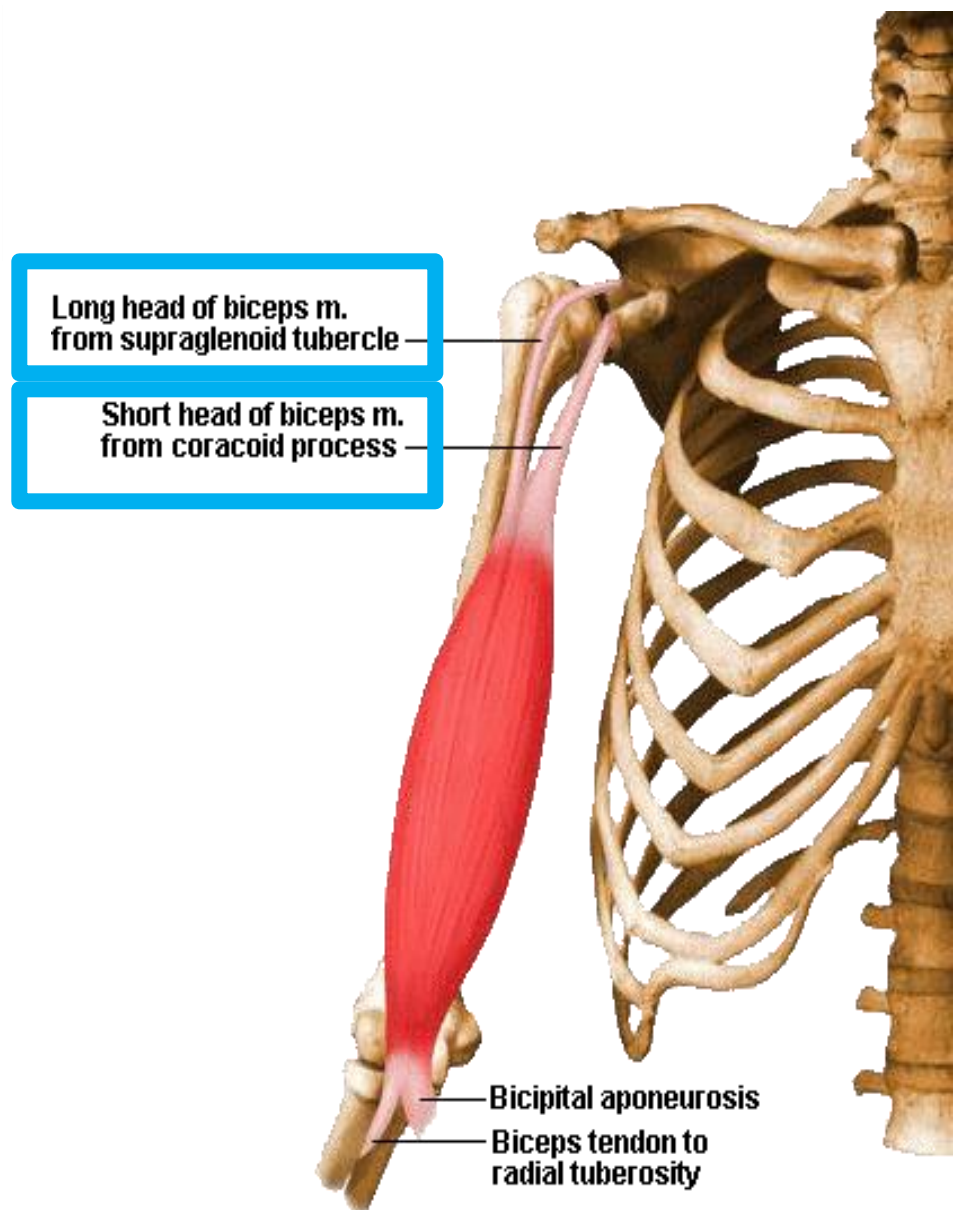
Coracobrachialis

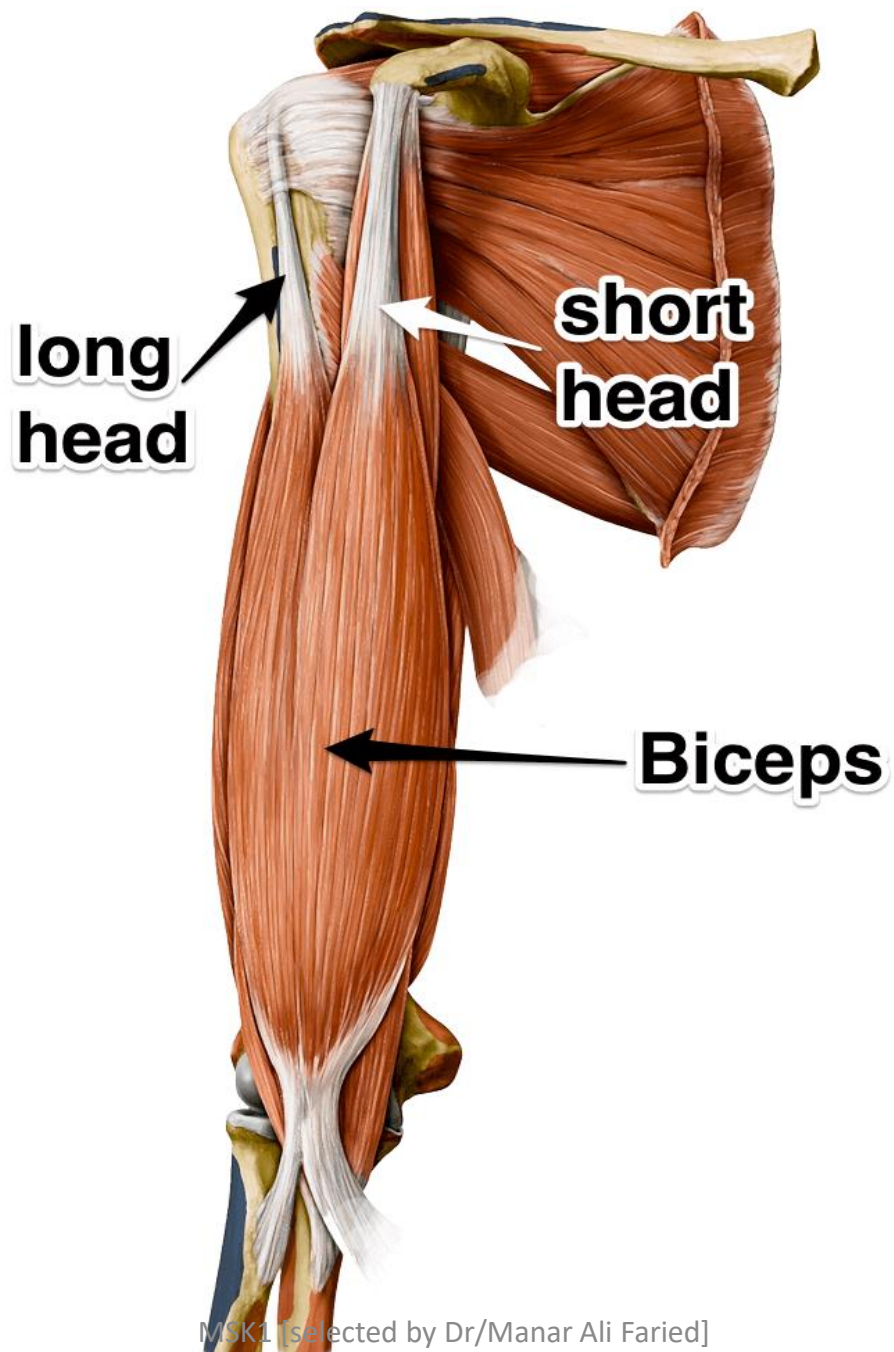


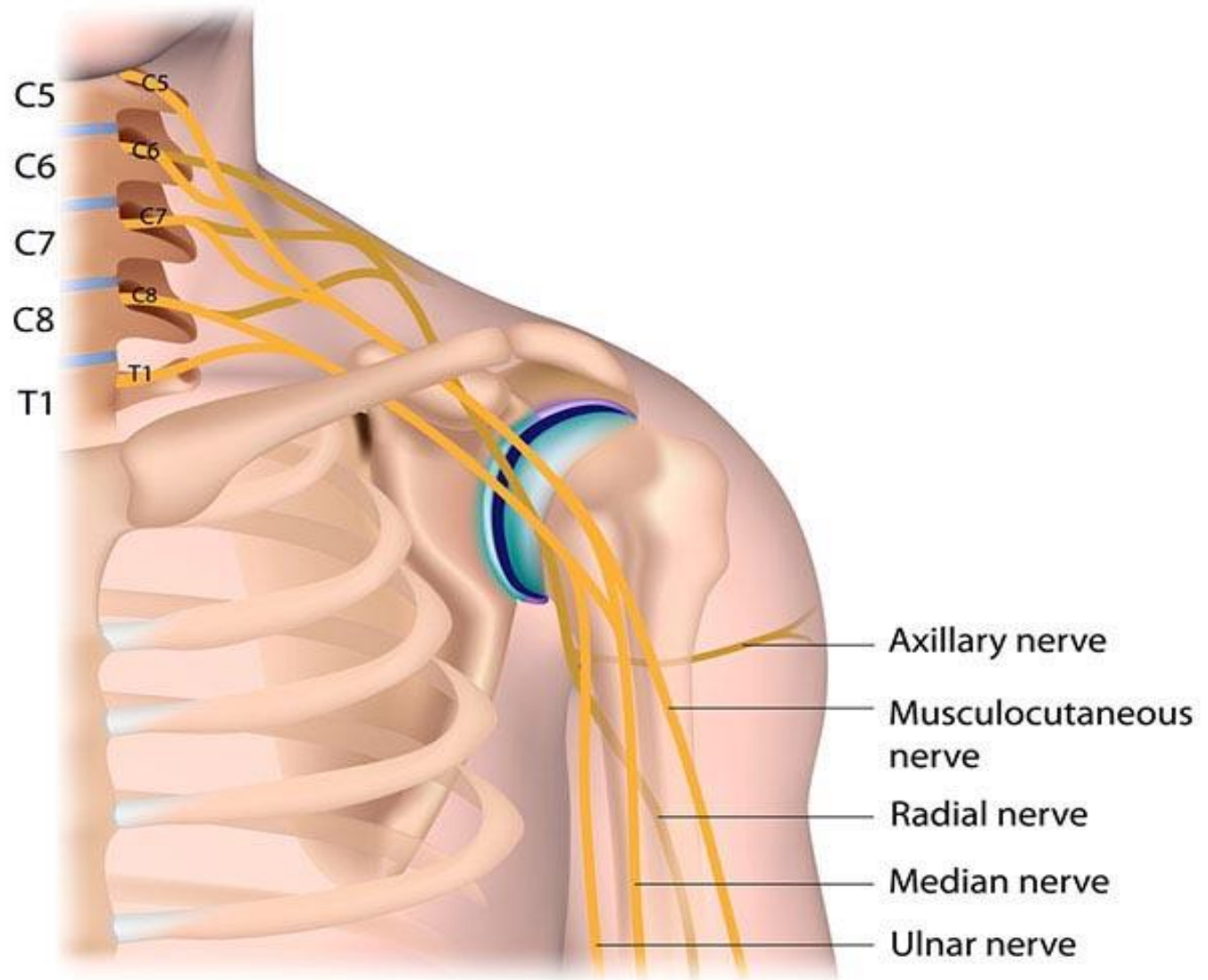
Brachialis



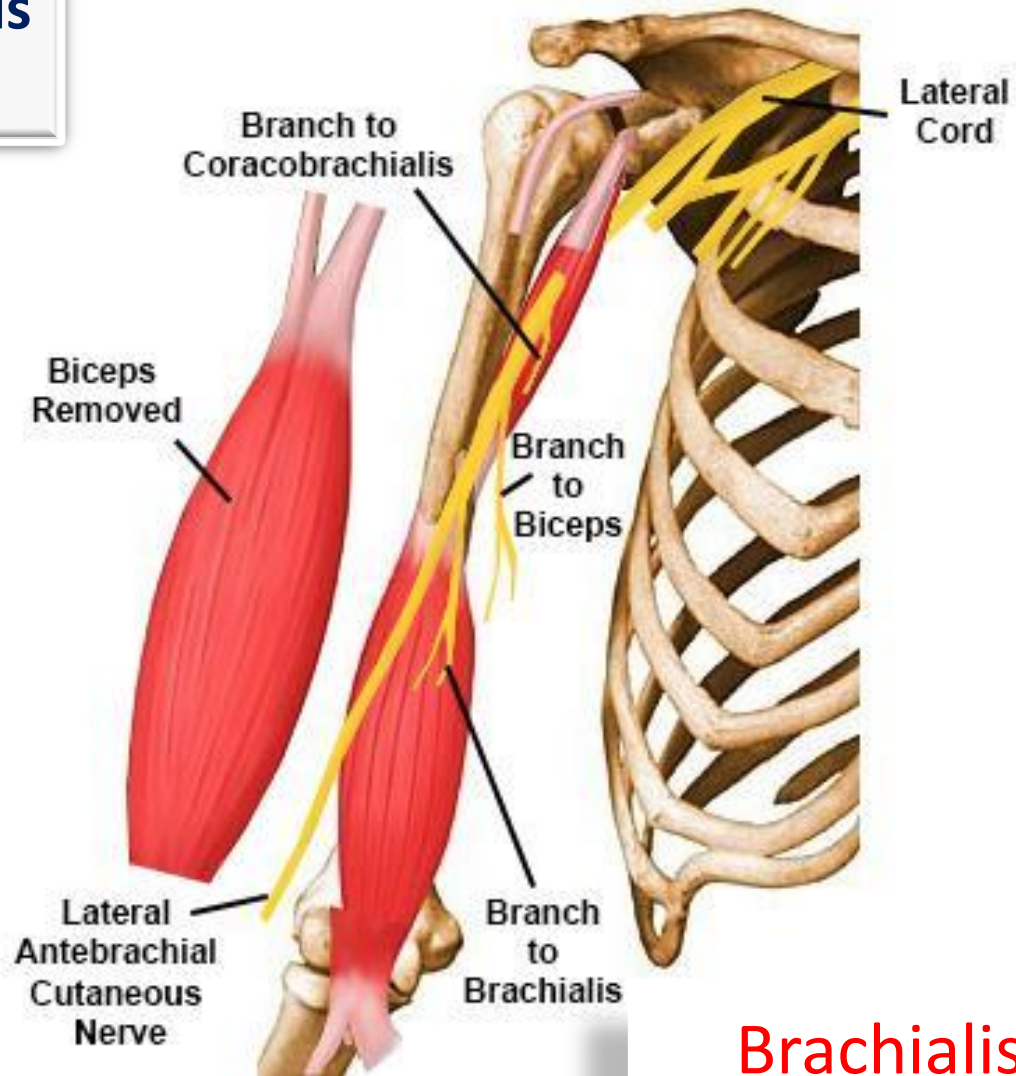
Biceps brachii





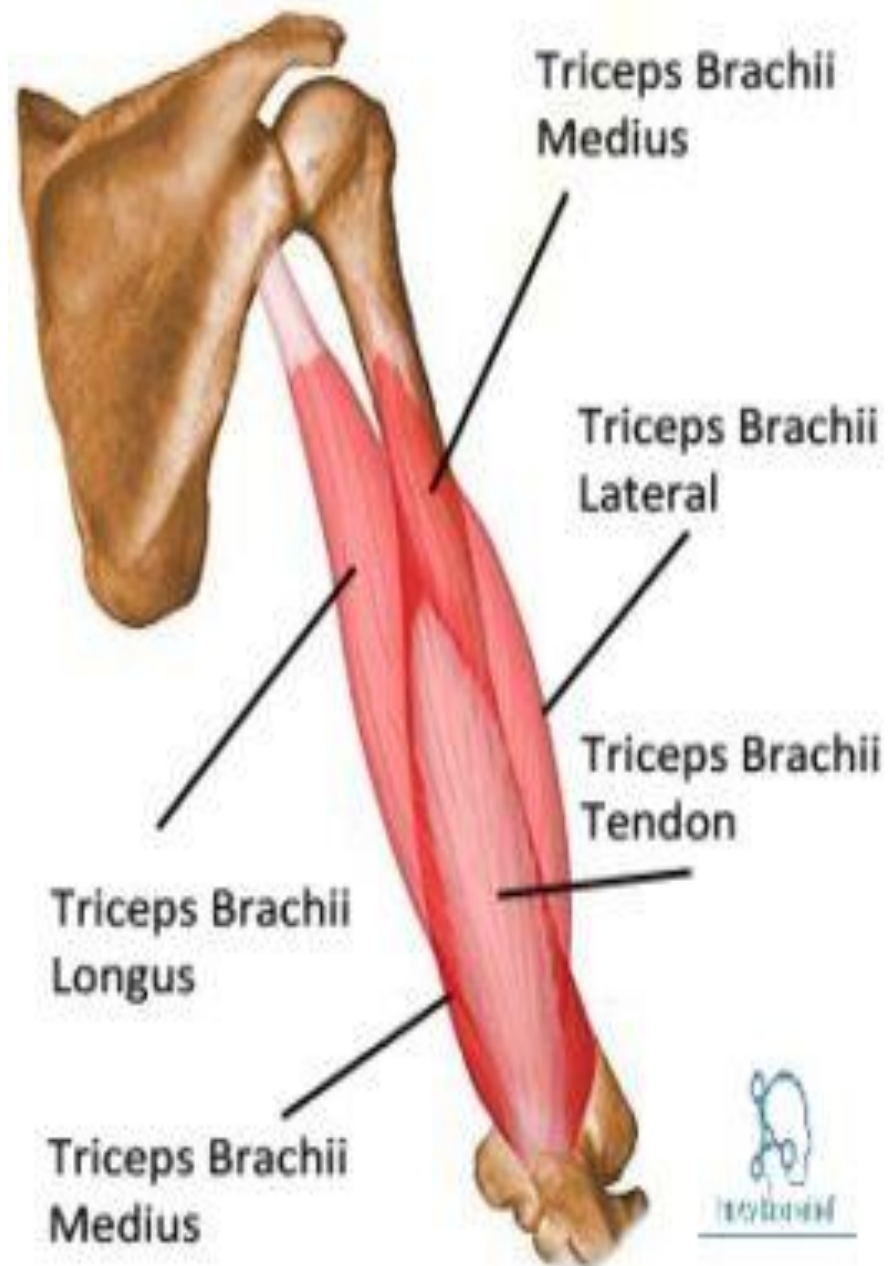


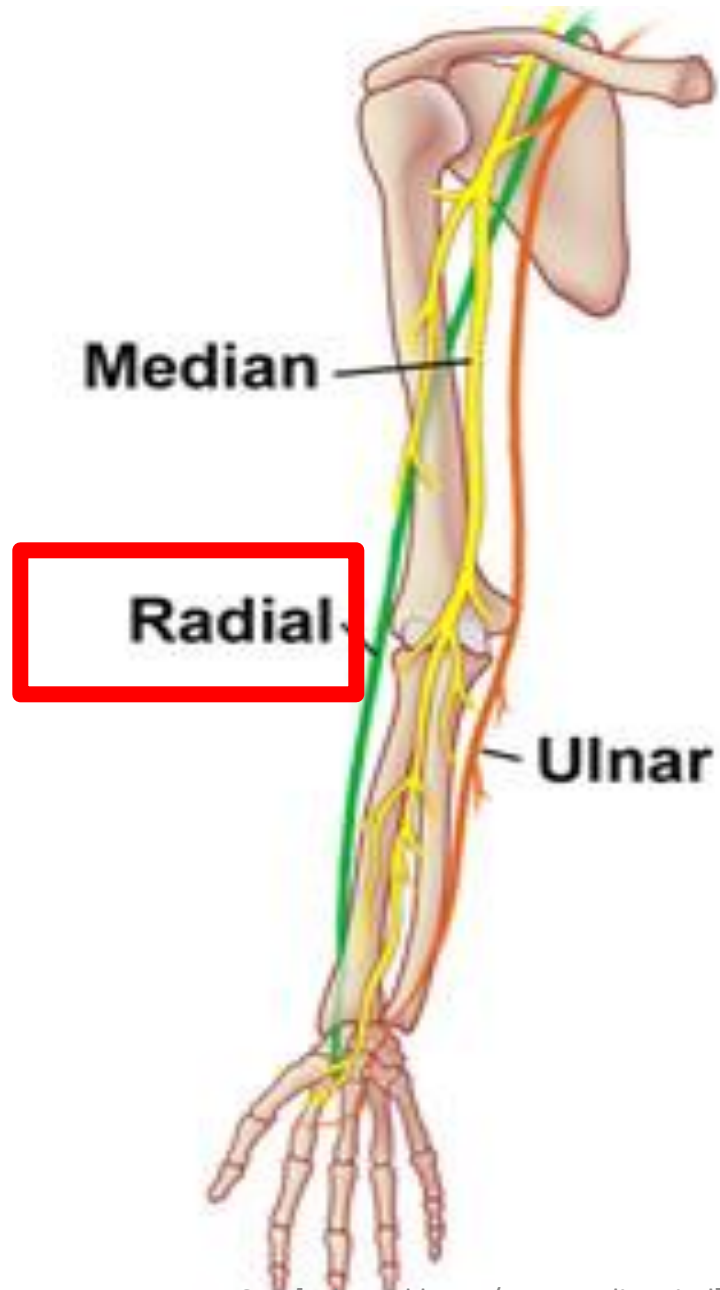
Musculocutaneous nerve



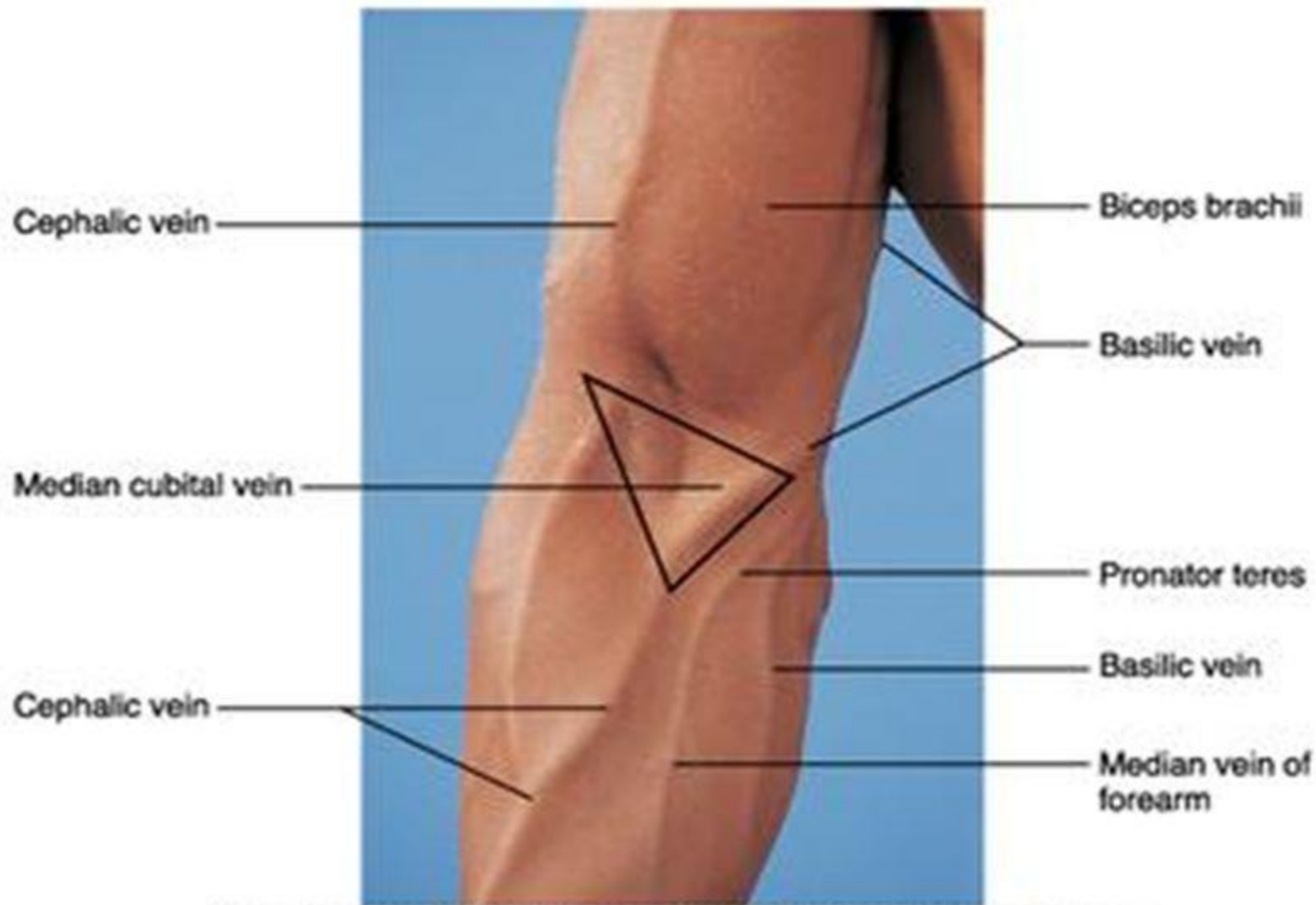
**Brachialis has
double nerve
supply**

Posterior group

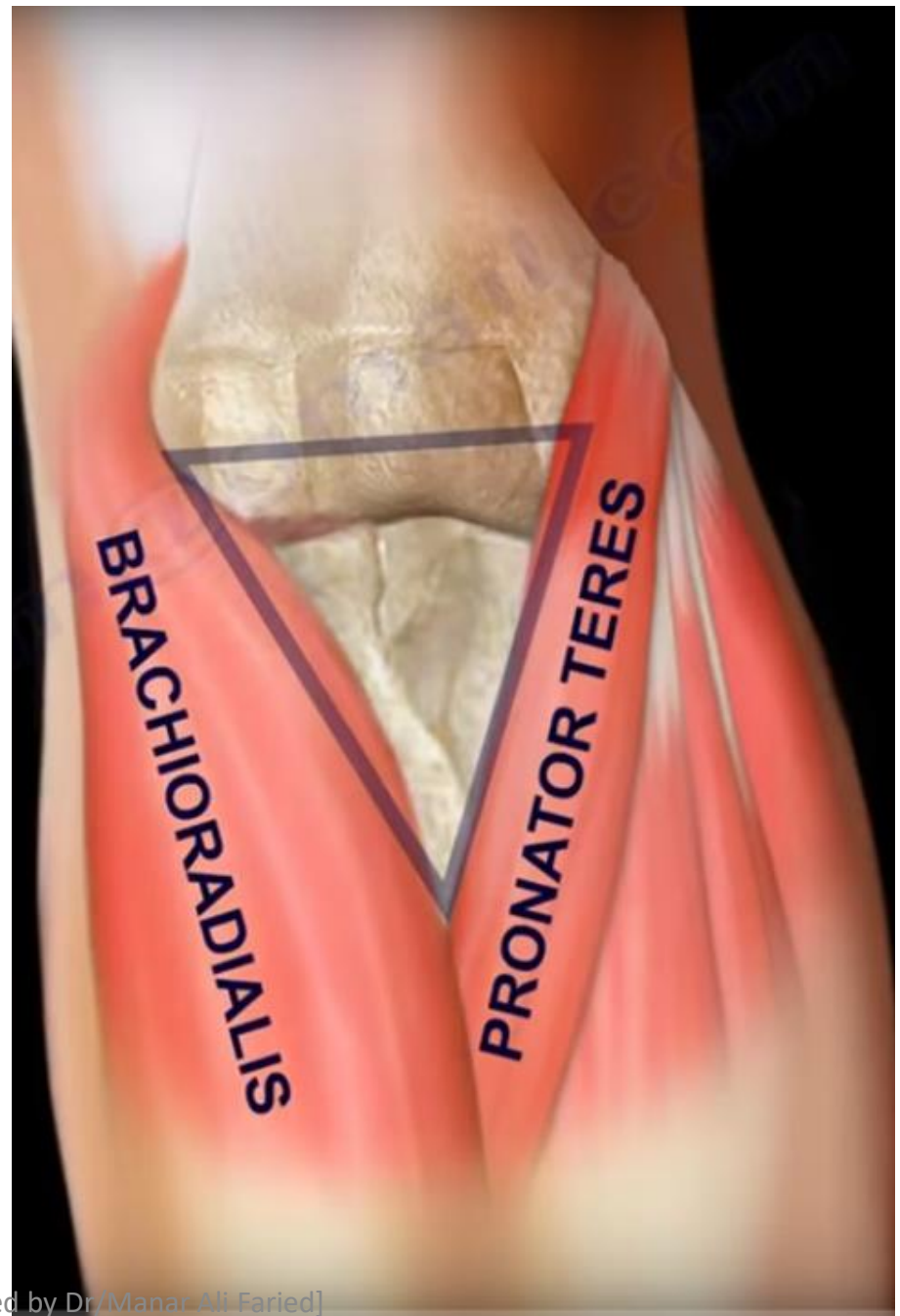
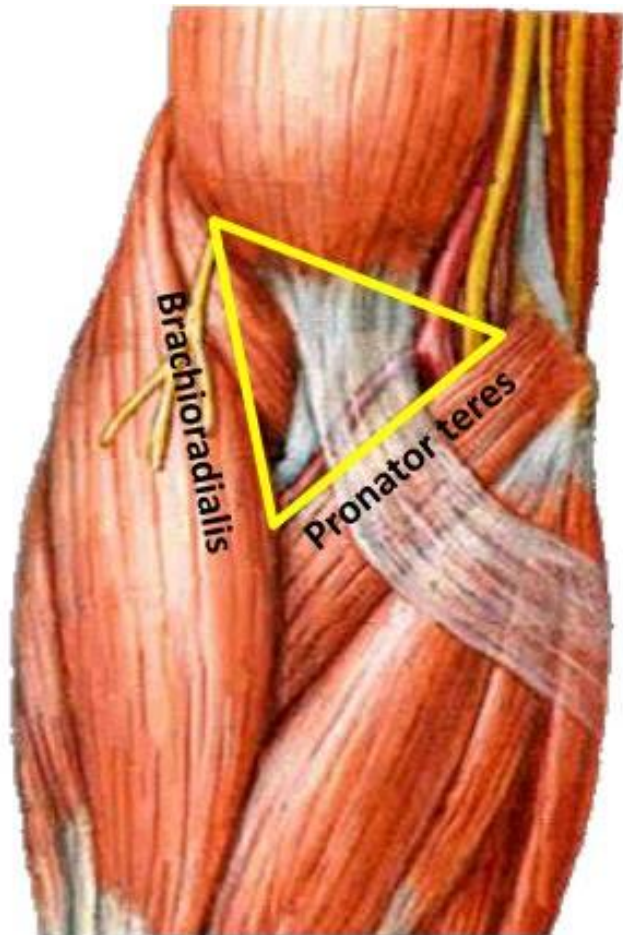




Cubital Fossa (Site for IV injection)



Copyright © 2001 Benjamin Cummings, an imprint of Addison Wesley Longman, Inc.



Musculocutaneous n.

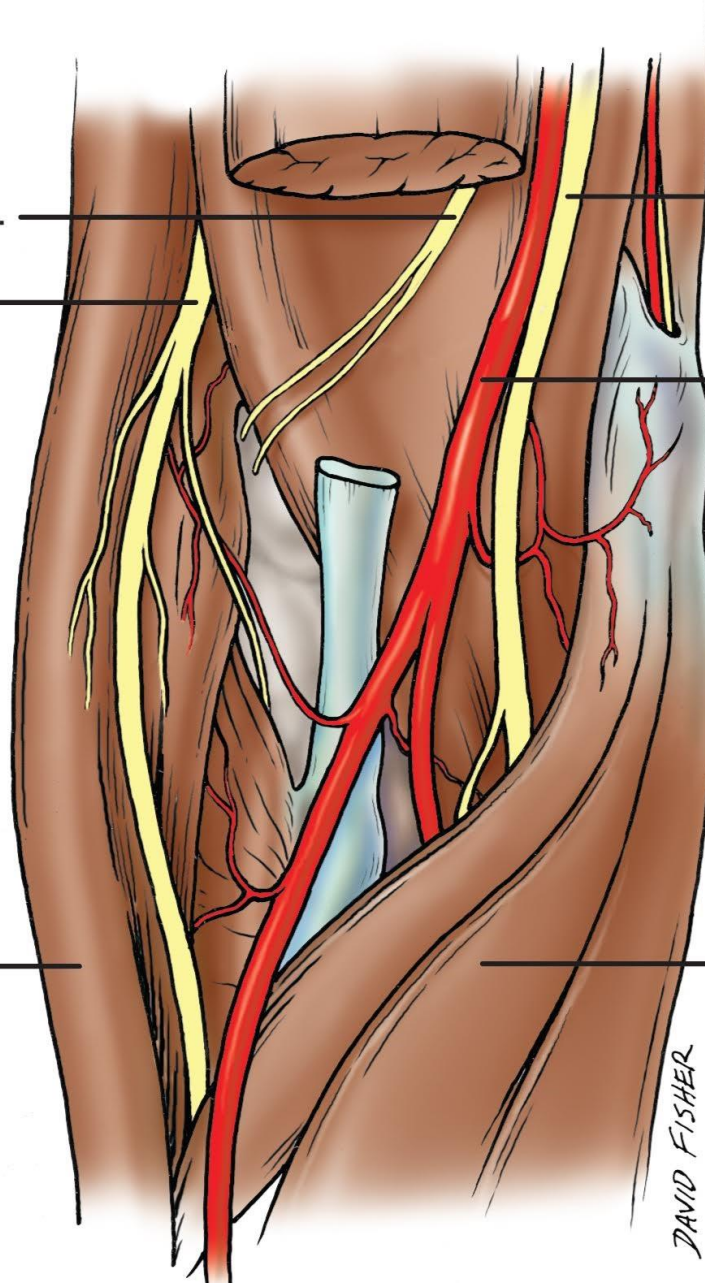
Radial n.

Brachioradialis

Median n.

Brachial a.

Pronator teres



LECTURE [6]



MUSCLES OF THE FOREARM

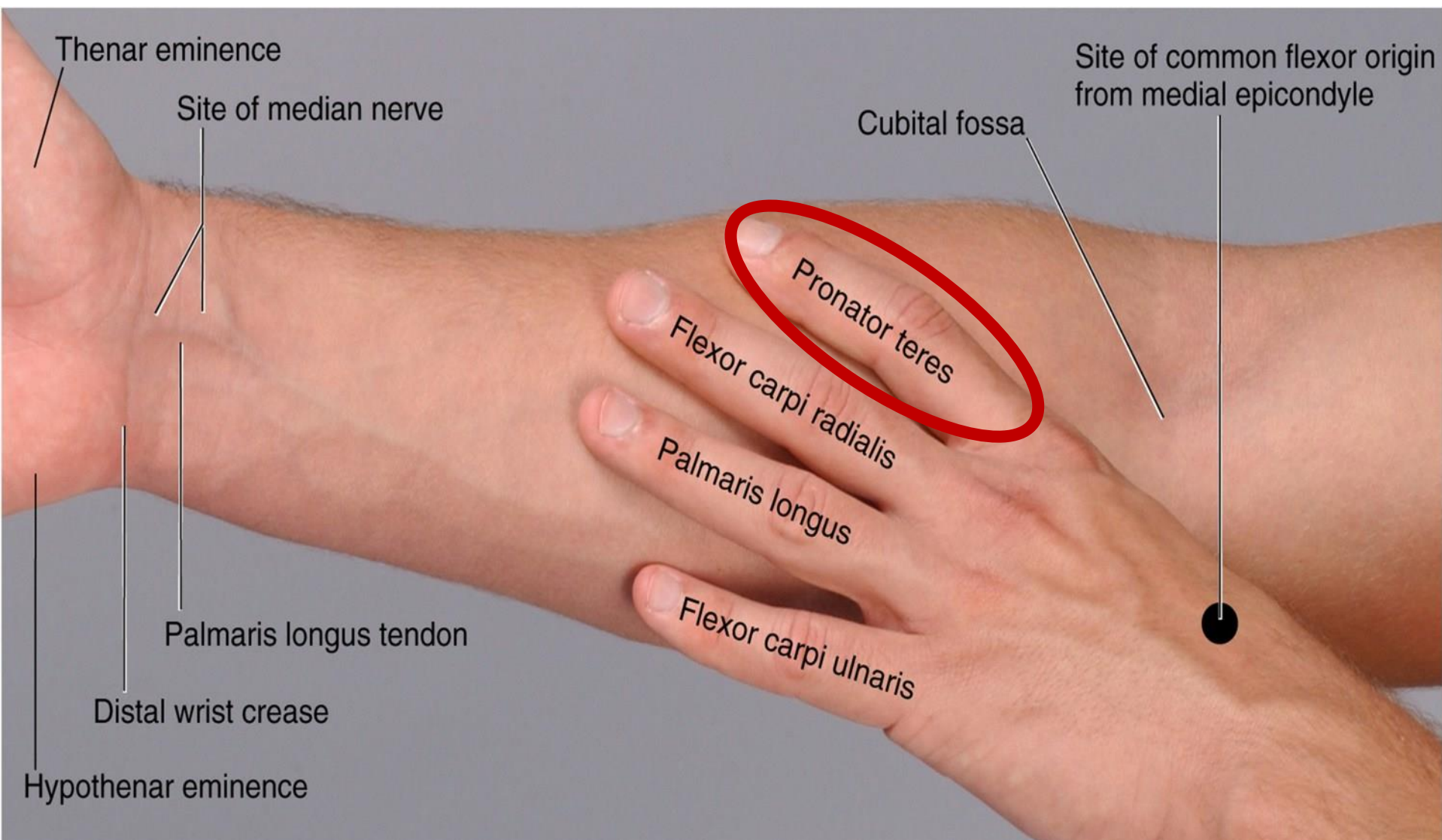
**Anterior
compartment**

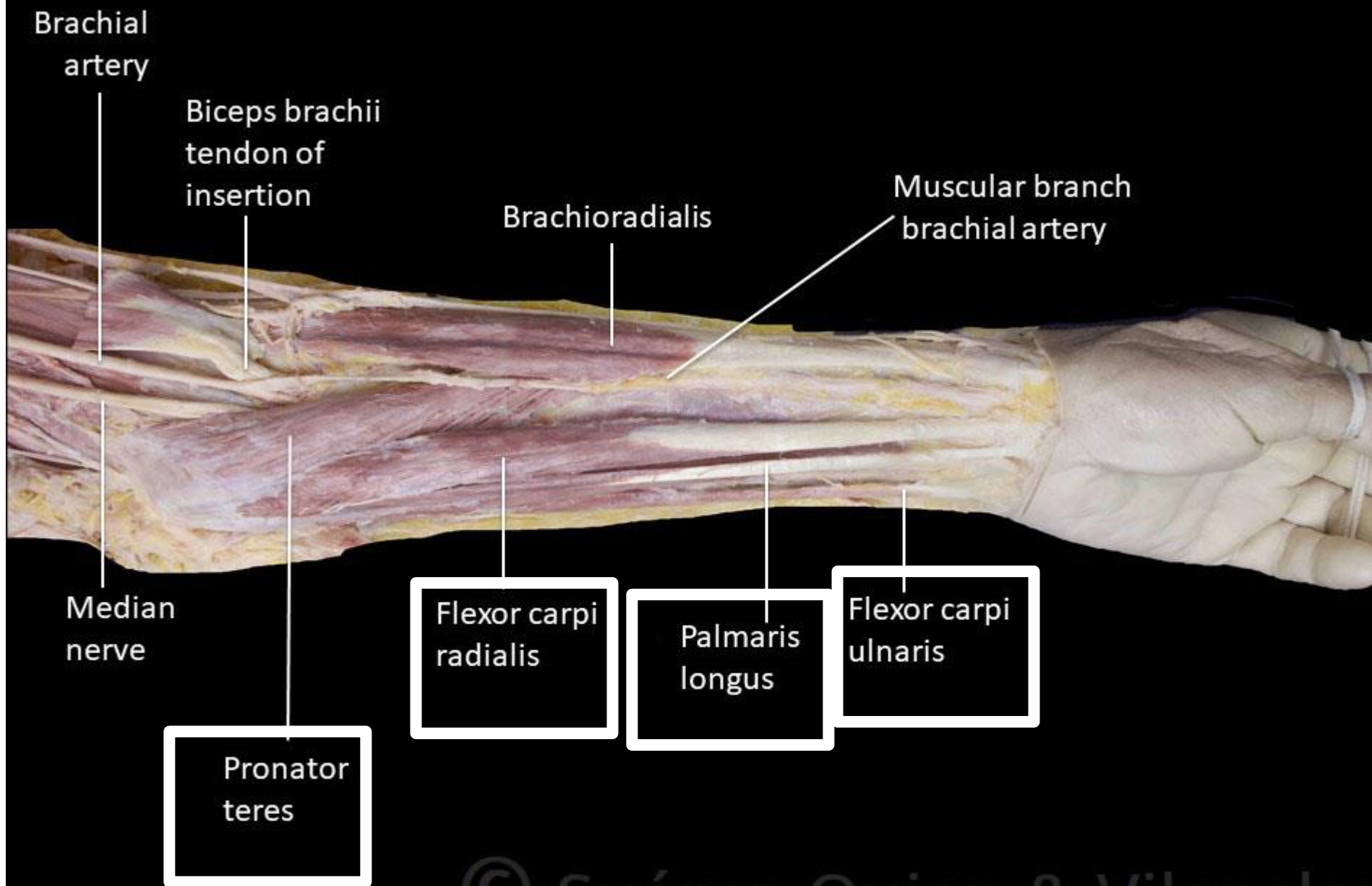
A diagram illustrating a three-compartment model. It consists of three horizontal rectangular boxes stacked vertically, separated by thick grey lines. The top box is labeled 'SUPERFICIAL', the middle box is labeled 'INTERMEDIATE', and the bottom box is labeled 'DEEP'. All labels are in bold red capital letters. To the left of the boxes, the text 'Anterior compartment' is written in bold red. A grey arrow points from this text towards the 'DEEP' compartment. The entire diagram is set against a light grey background.

SUPERFICIAL

INTERMEDIATE

DEEP

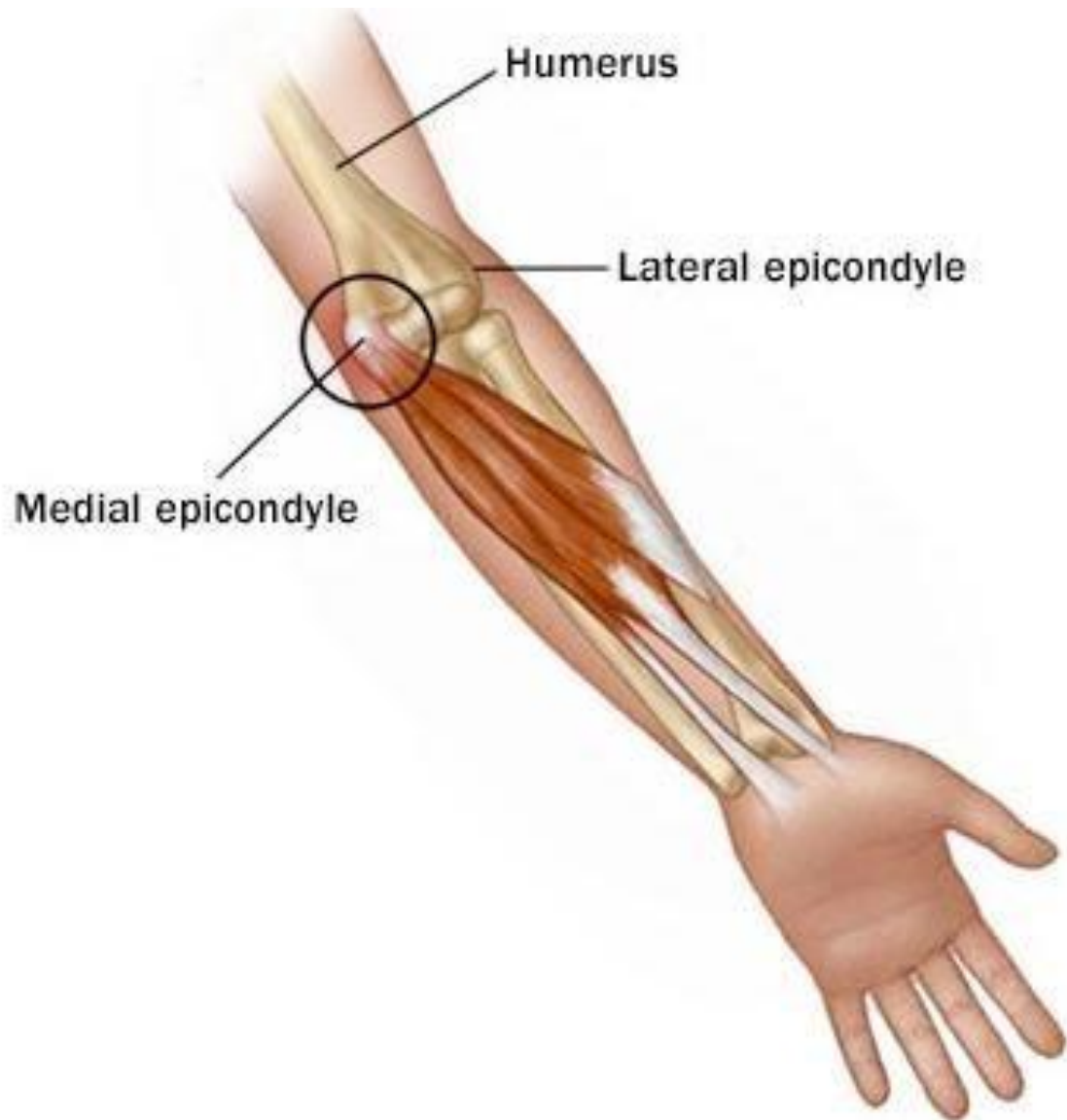



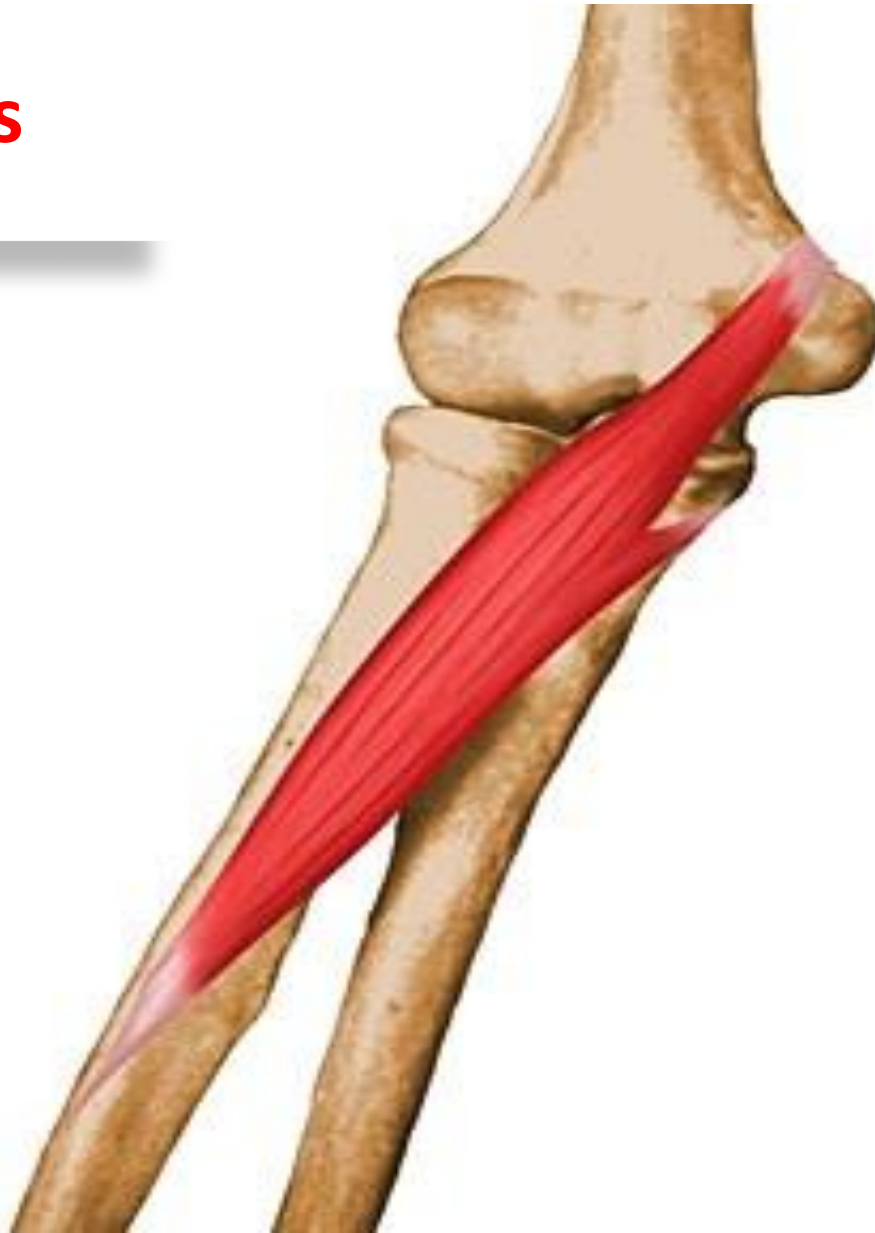**Common
Origin**

**Common
Flexor
Origin**

**Front of
the medial
epicondyle**



Pronator teres

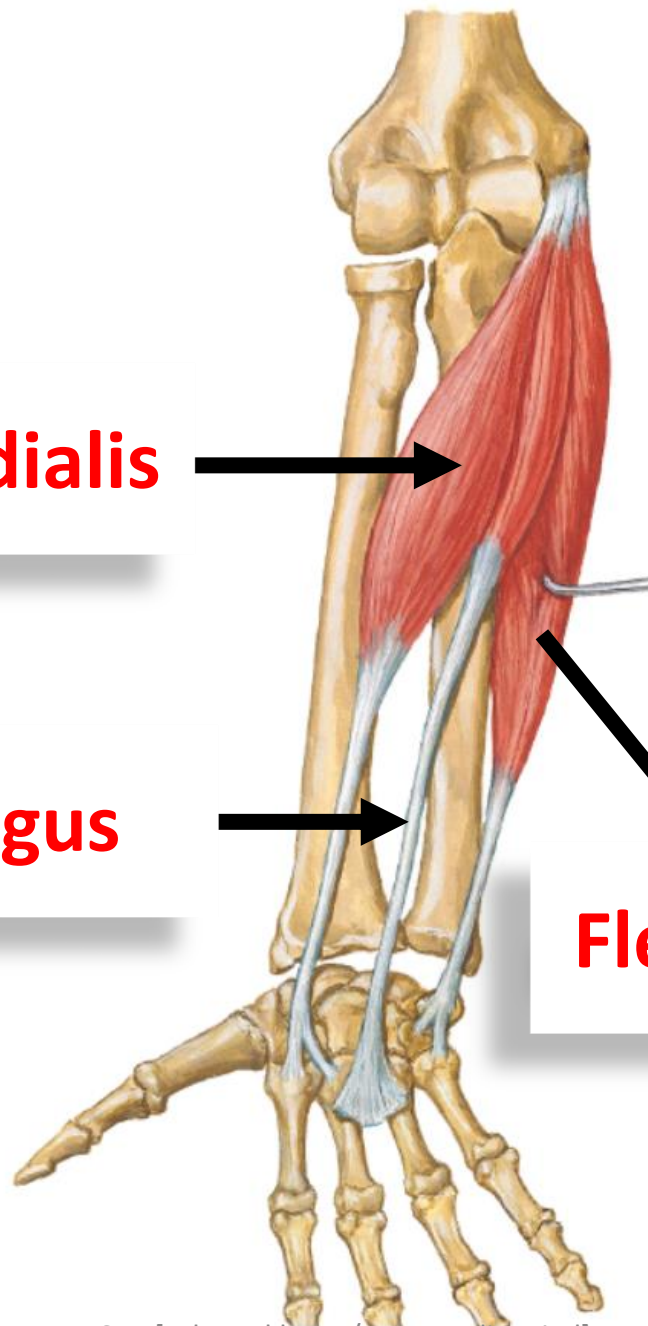


MSK1 [selected by Dr/ Manar Ali Faried]

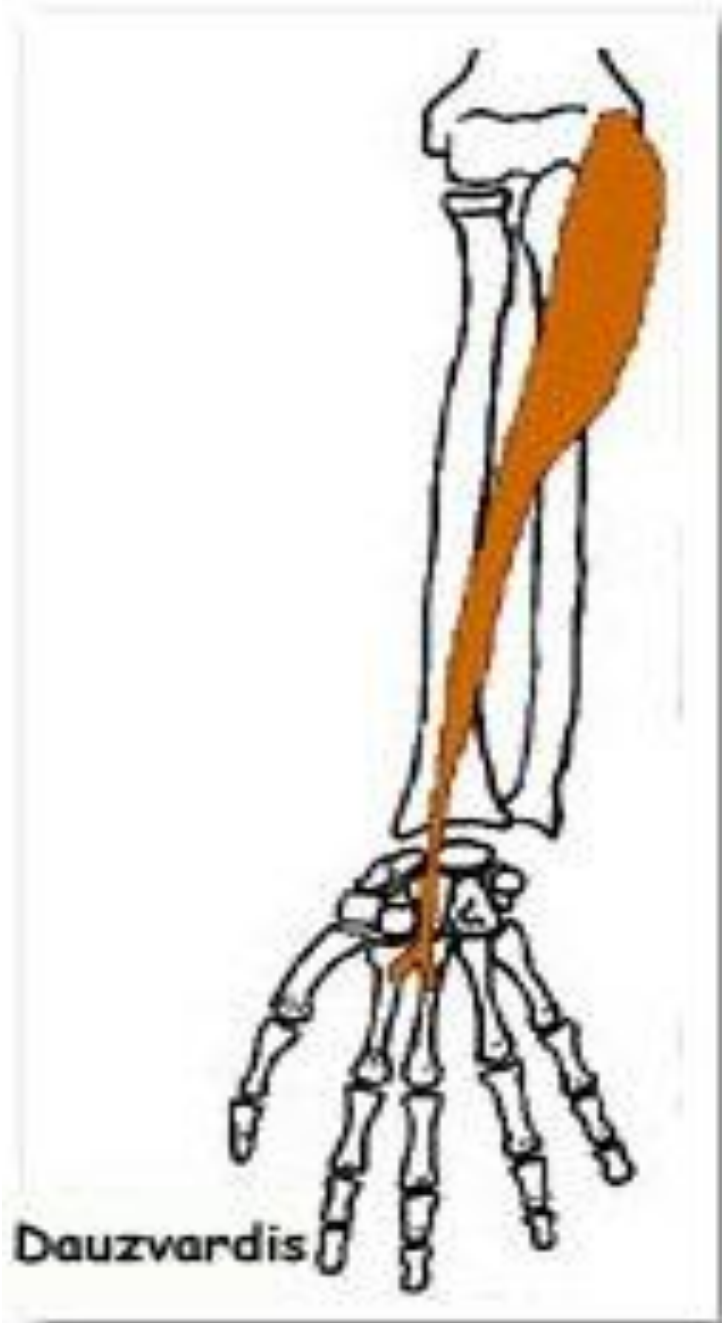
Flexor carpi radialis

Palmaris longus

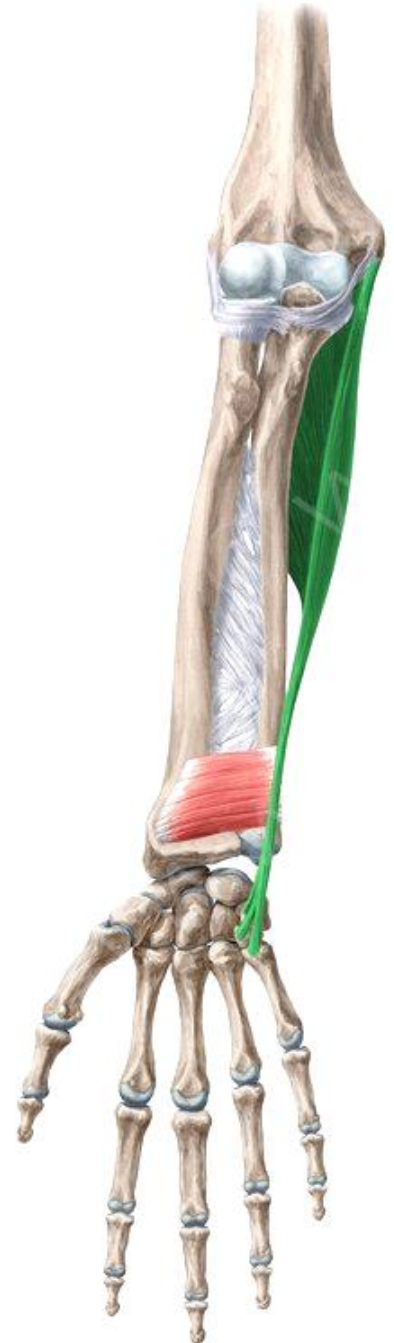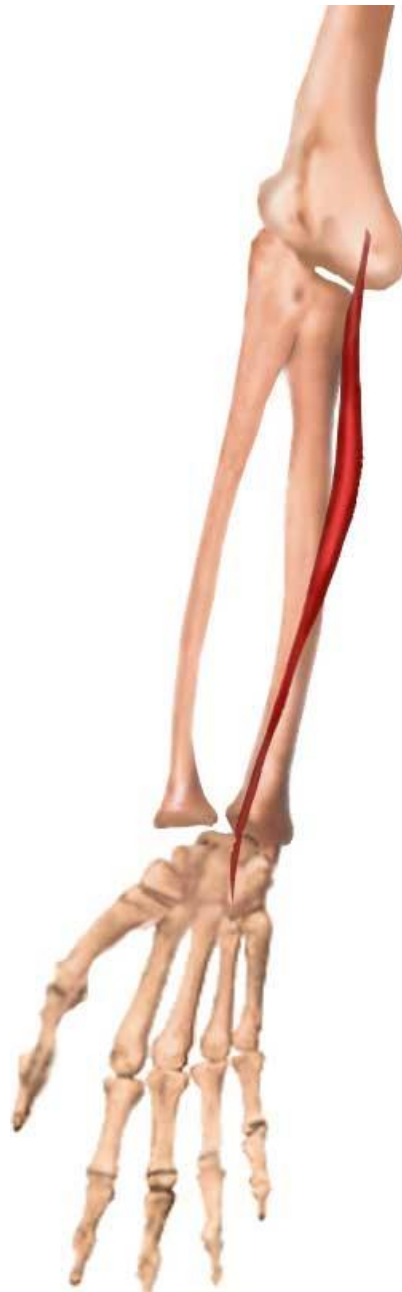Flexor carpi ulnaris



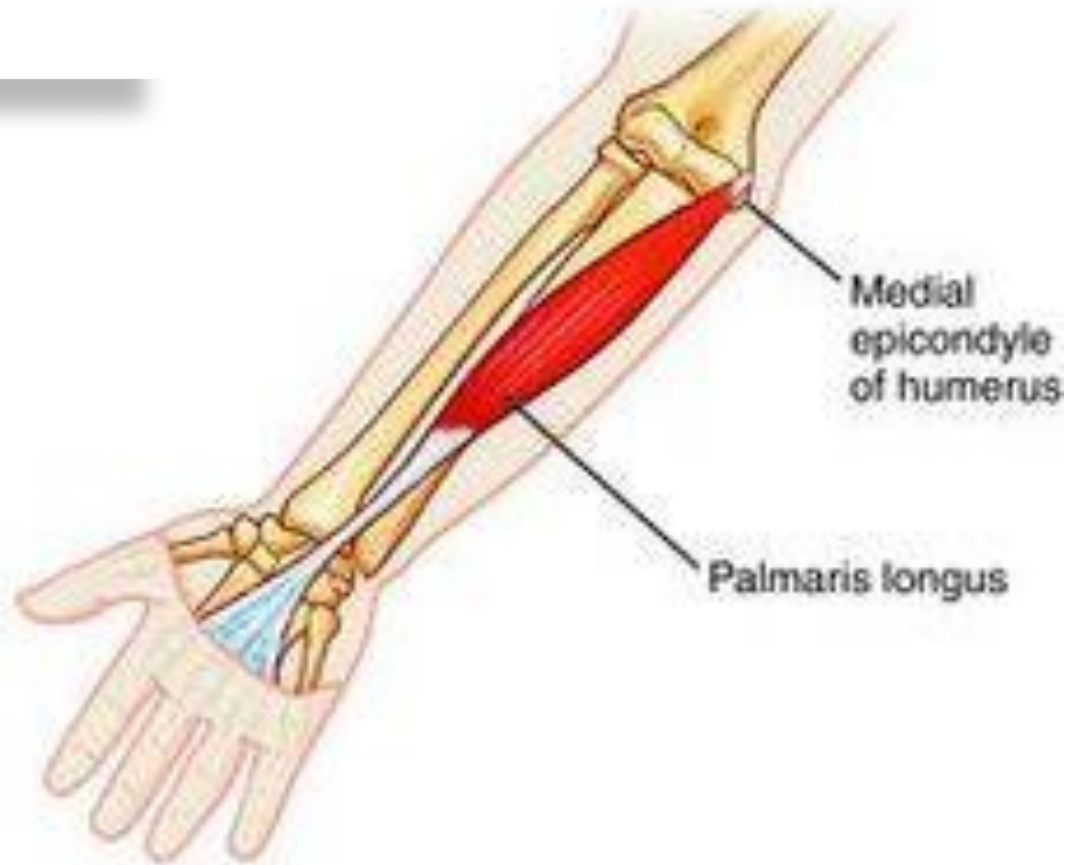Flexor carpi radialis



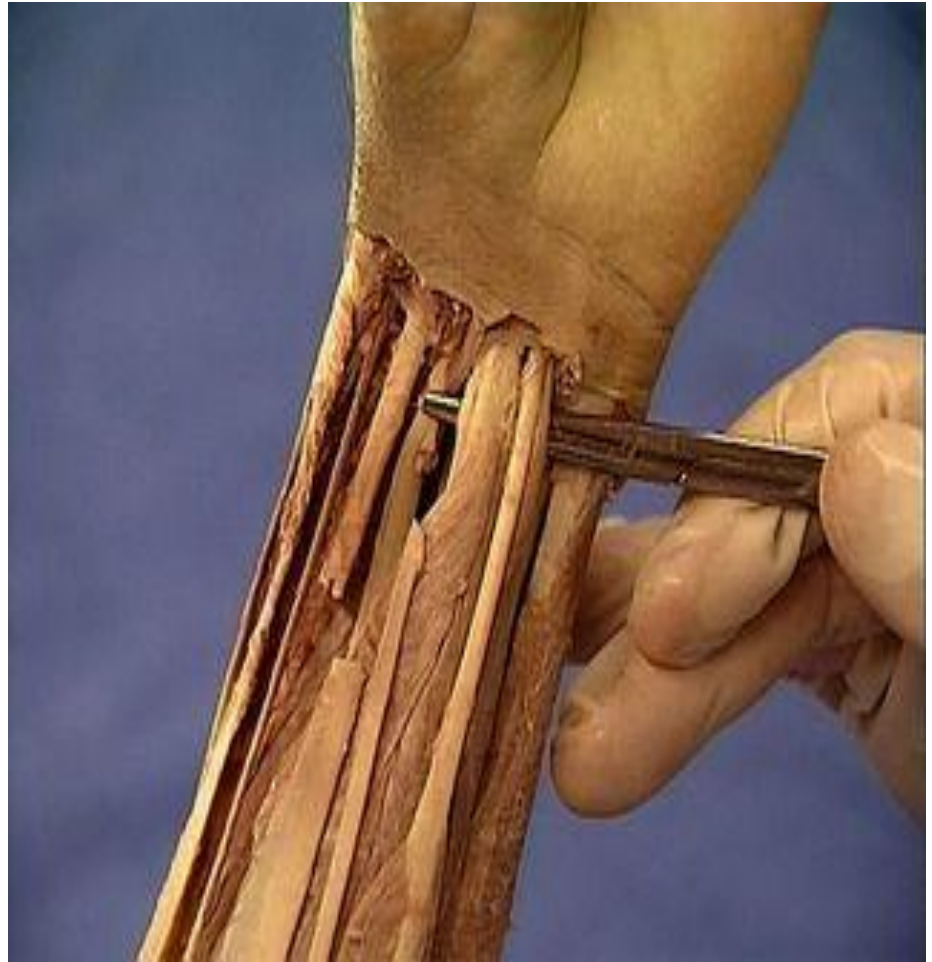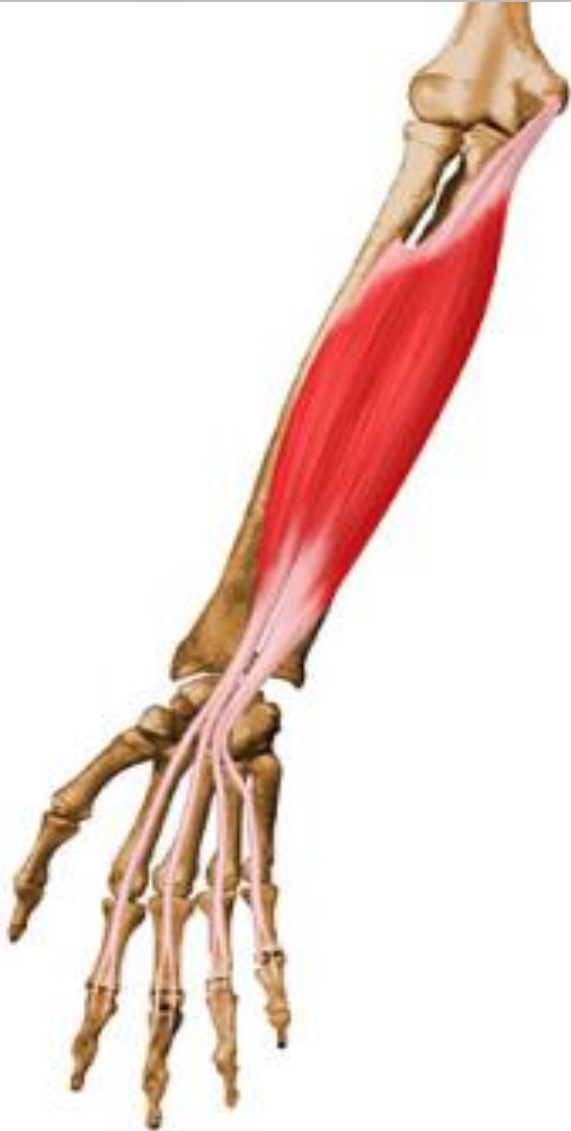Flexor carpi ulnaris

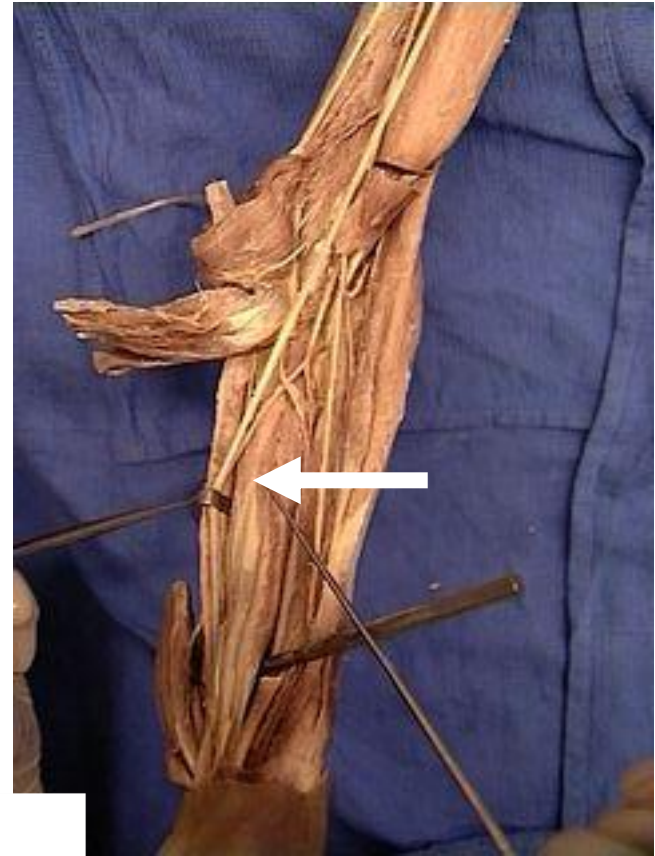

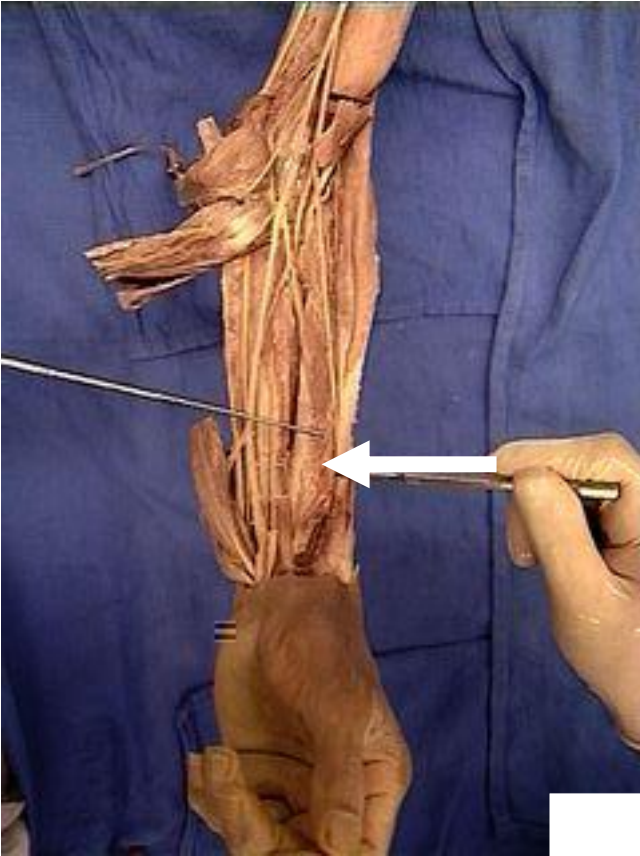


Palmaris Longus



Flexor digitorum superficialis





Deep Group

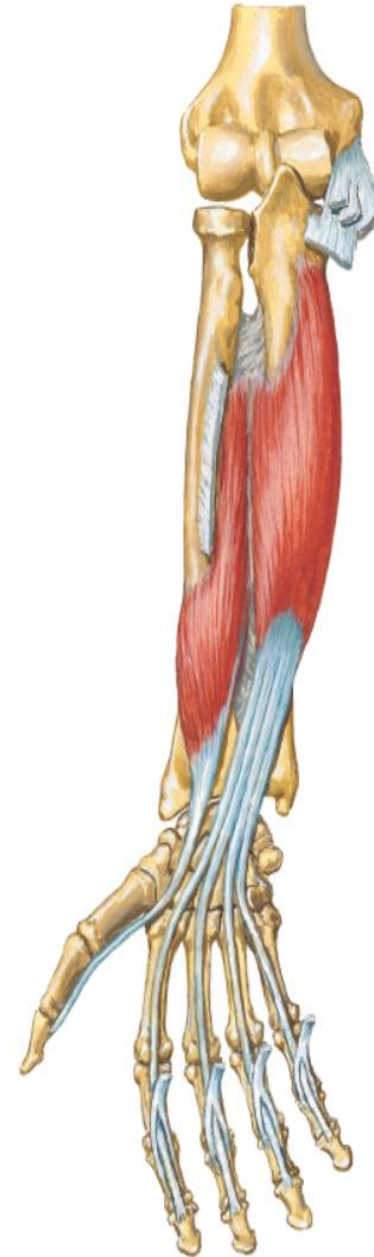**Flexor
policis
longus**

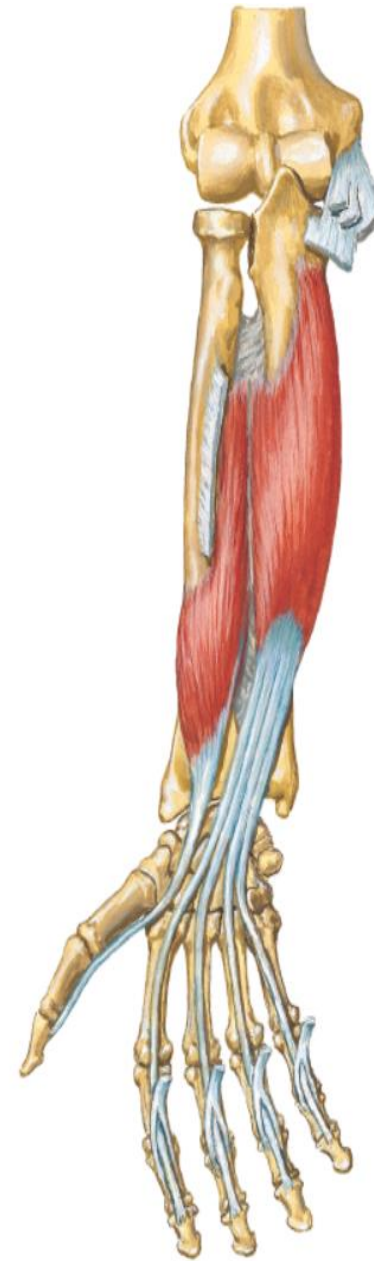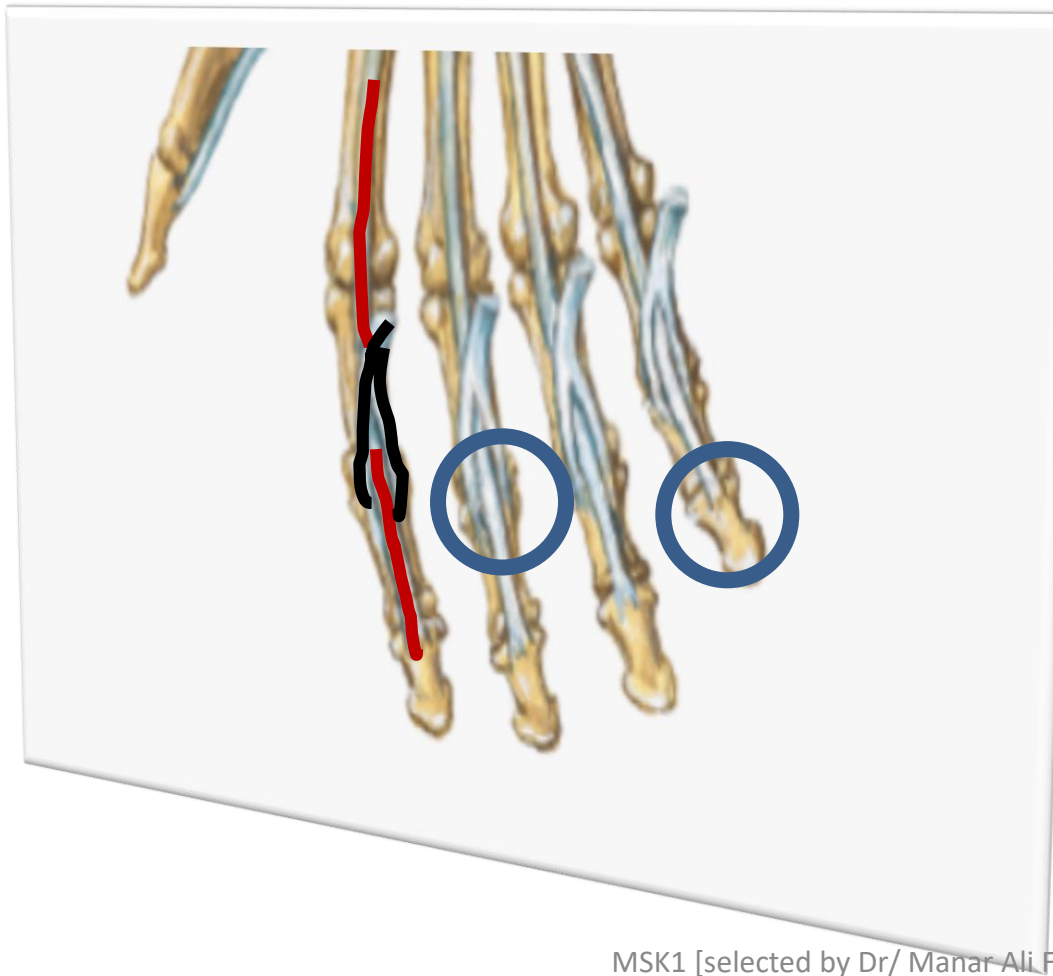
**Pronator
quadratus**

**Flexor
digitorum
profundus**

**Flexor digitorum
profundus**

Flexor pollicis longus





Pronator quadratus



All are supplied by the median nerve (or its branch)

EXCEPT

FCU

Medial half of FDP

By ulnar N

LECTURE [7]

MUSCLES OF THE FOREARM

SUPERFICIAL

**POSTERIOR
COMPARTMENT**

DEEP

Lateral aspect

Brachioradialis

Ex C. R. L

Ex C. R. Br

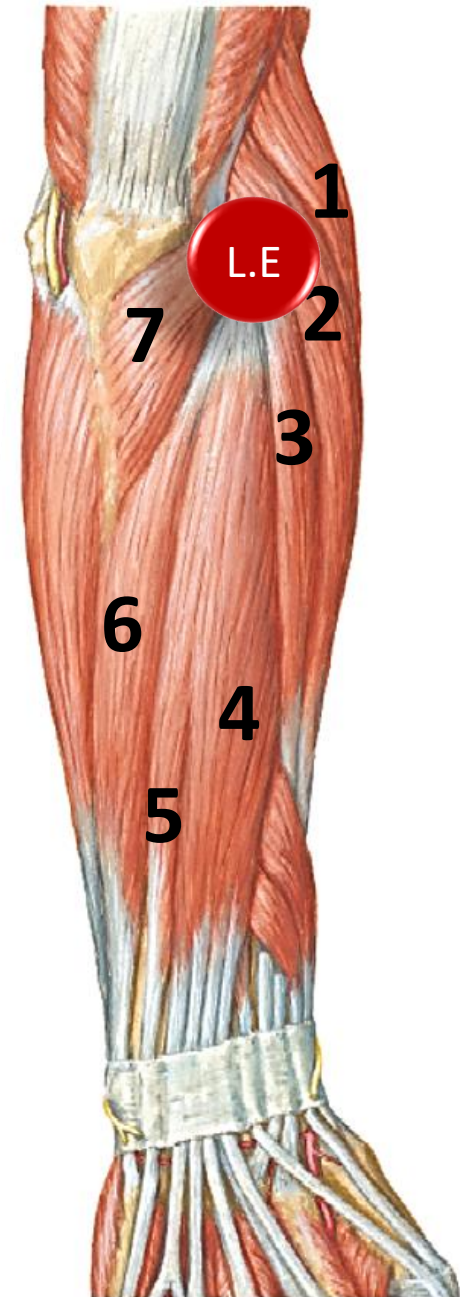
Dorsal aspect

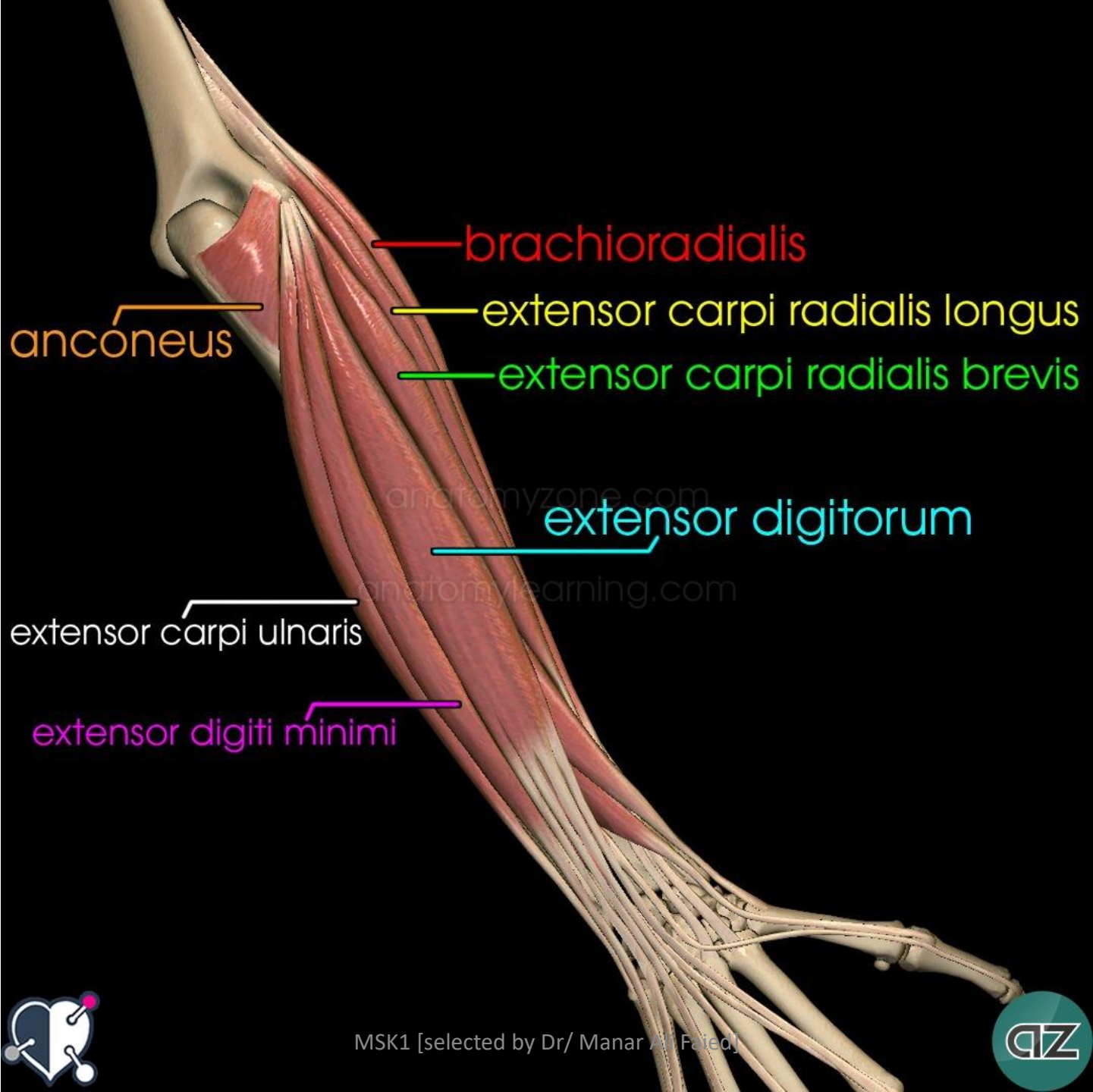
Ex Digitorum

Ex Digiti minimi

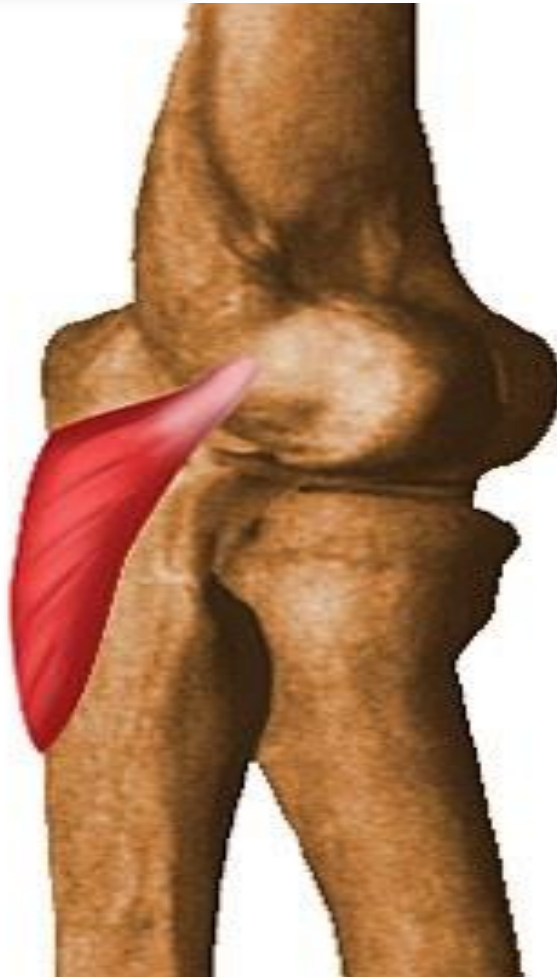Ex. C. U

Anconeus





Anconeus

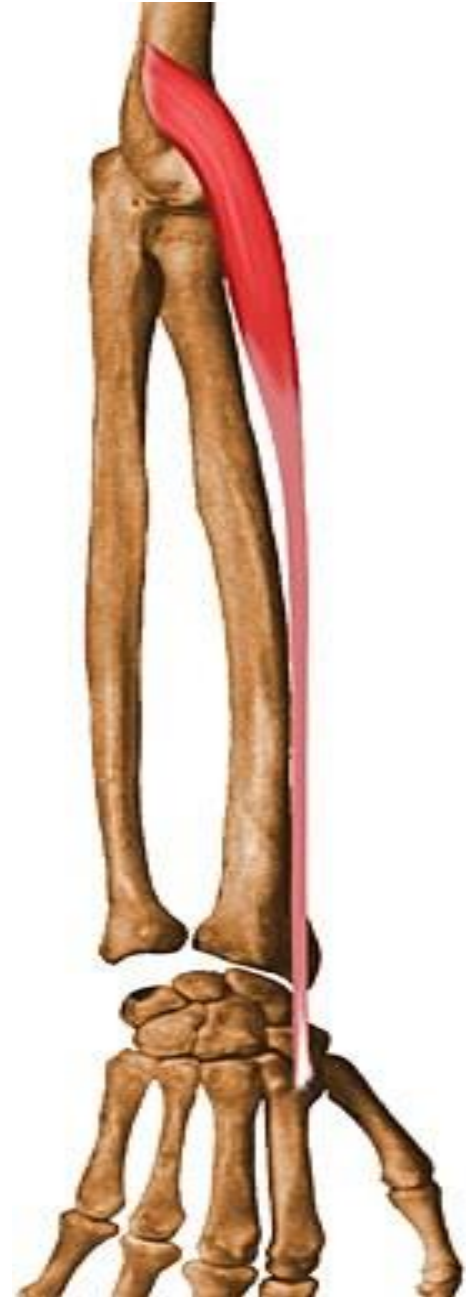

MSK1 [selected by Dr/ Manar Ali Faied]

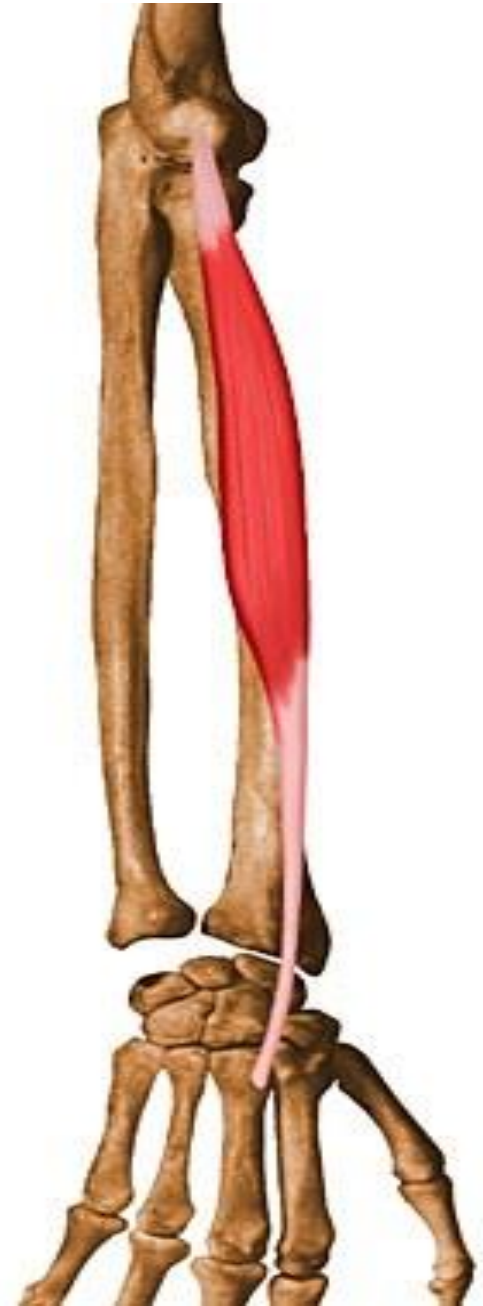Brachioradialis



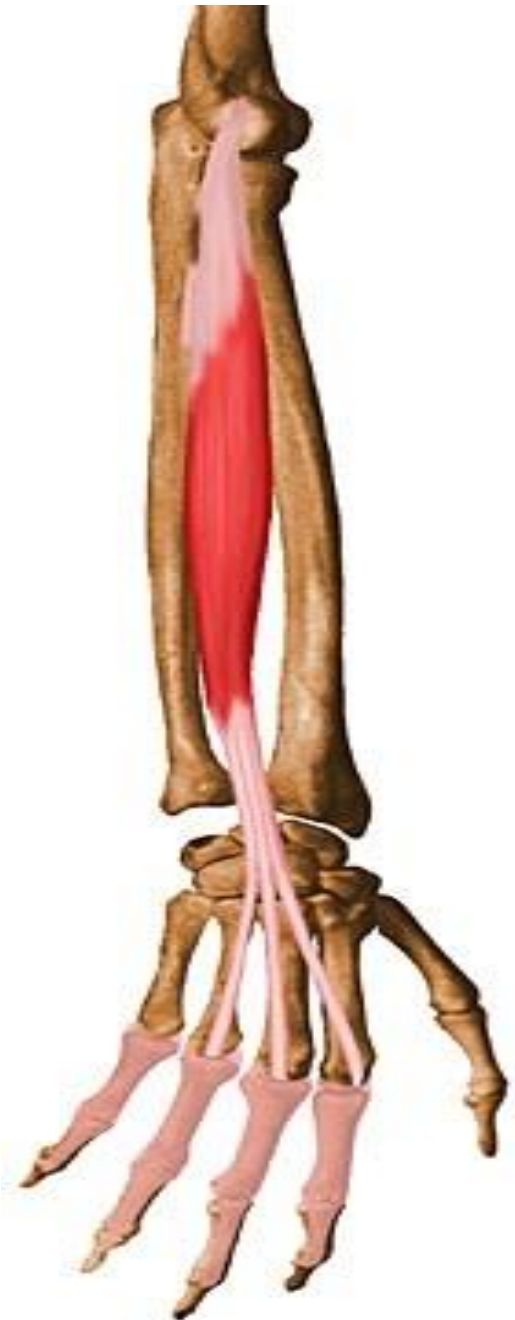Extensor Carpi Radialis Longus

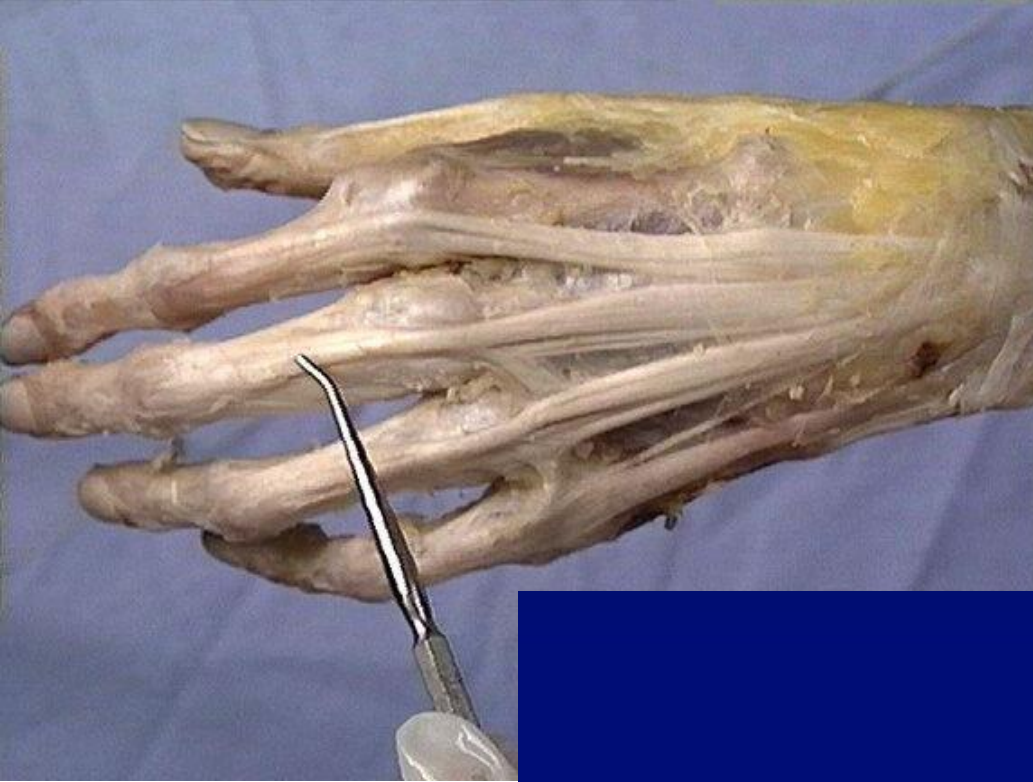

Extensor Carpi Radialis Brevis

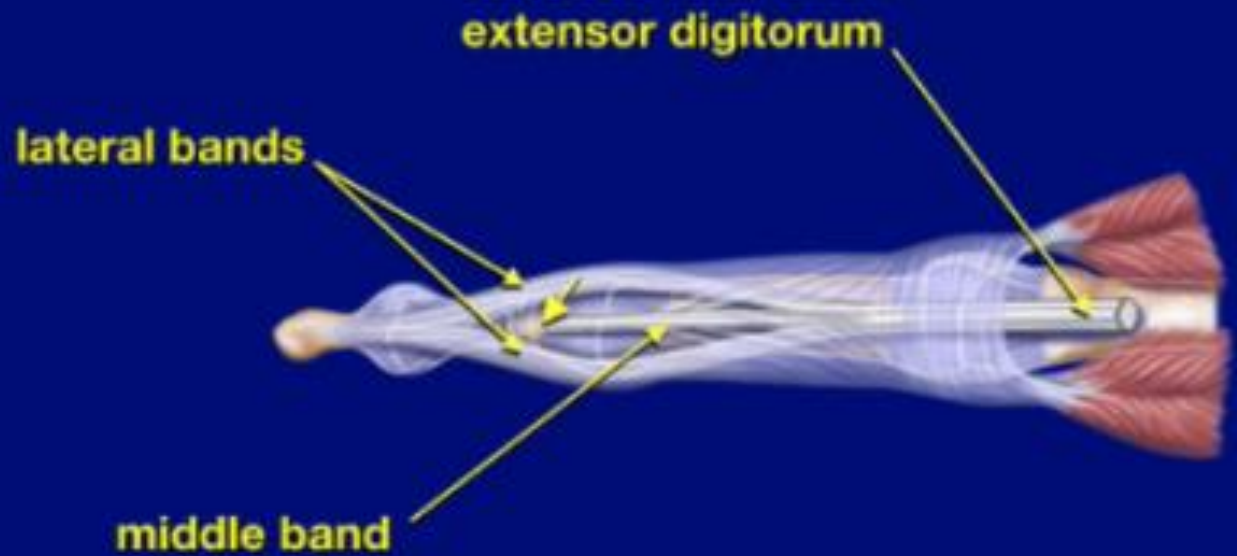


Extensor Digitorum



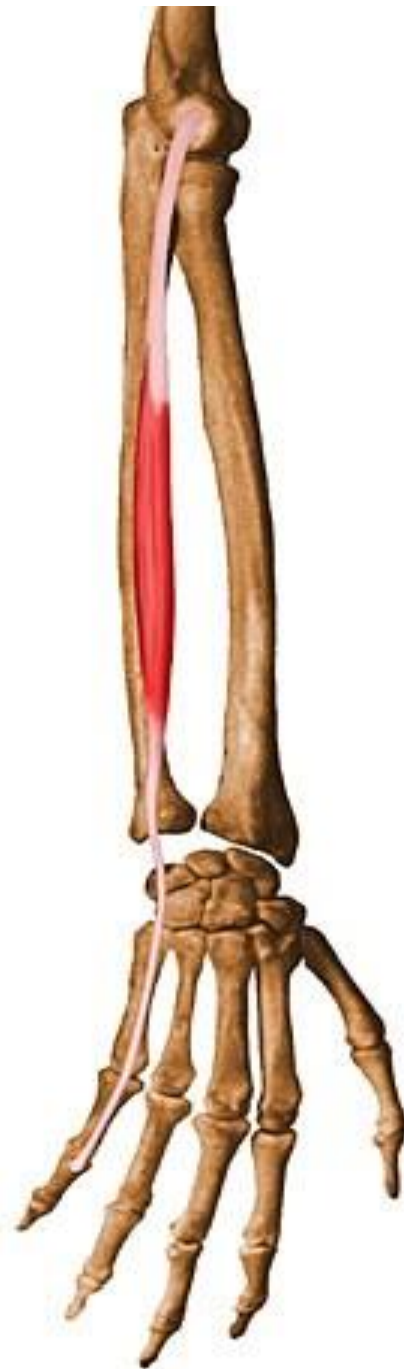

Extensor Expansion

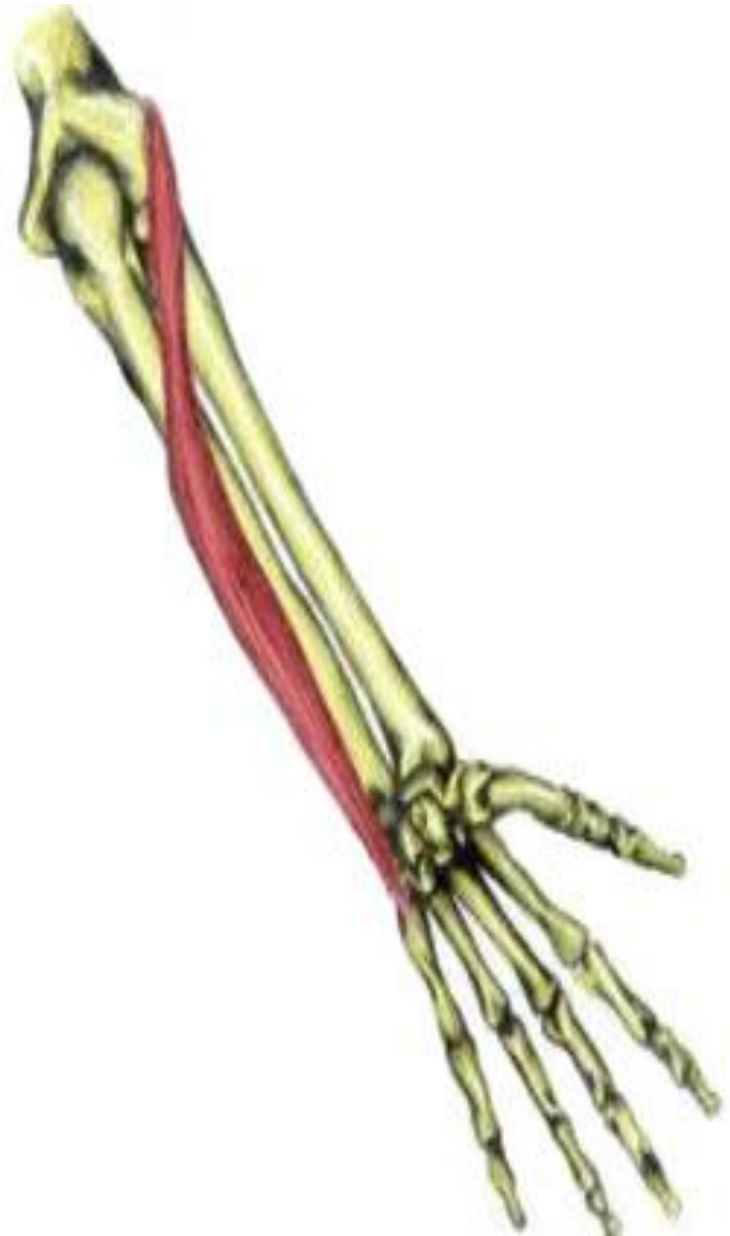


MSK1 [selected by Dr/ Manar Ali Faied]

Extensor Digiti Minimi

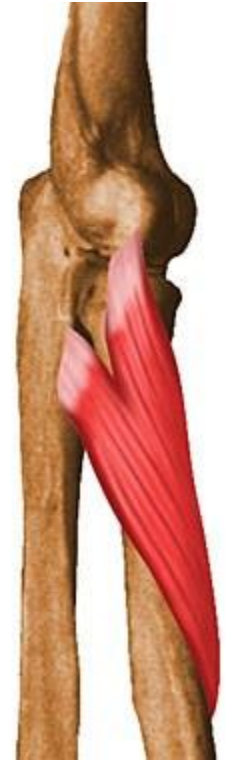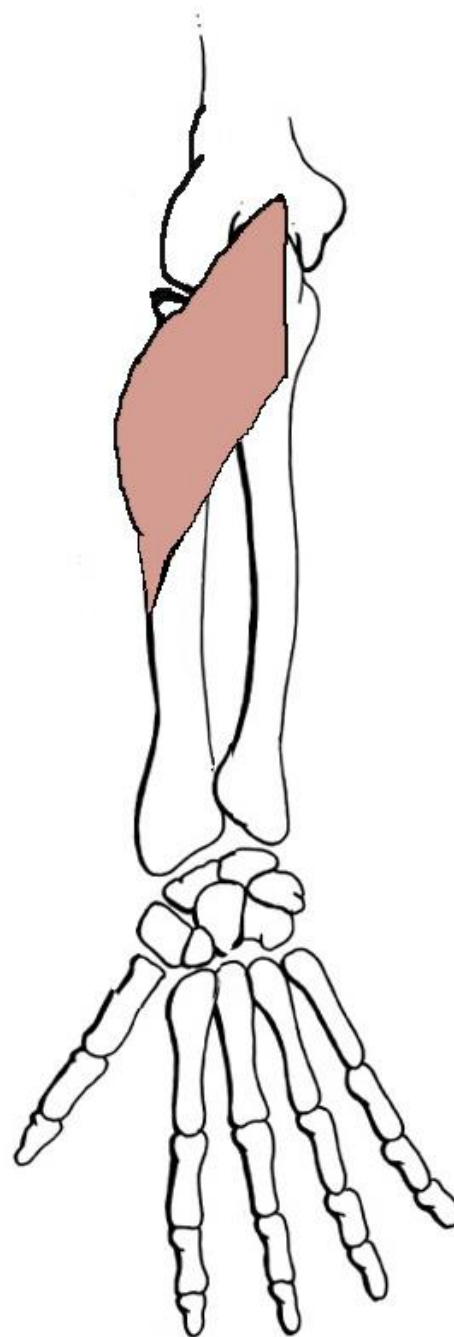


Extensor Carpi Ulnaris

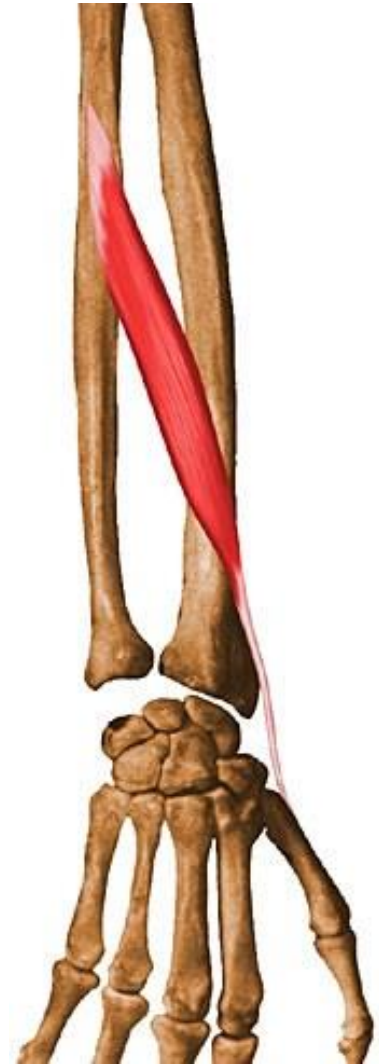

Deep group

Supinator



Abductor pollicis longus

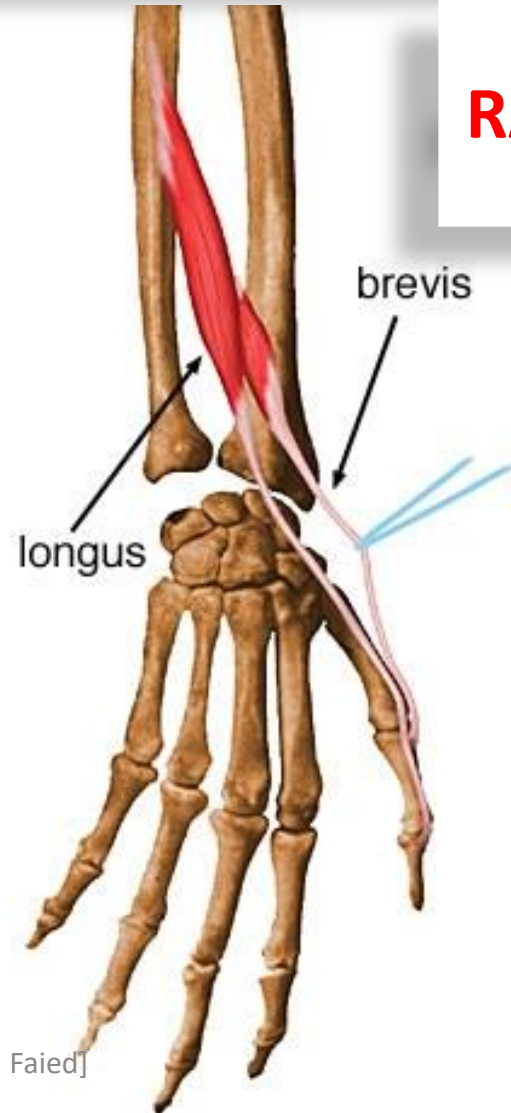


Extensor Policis Longus

ULNA

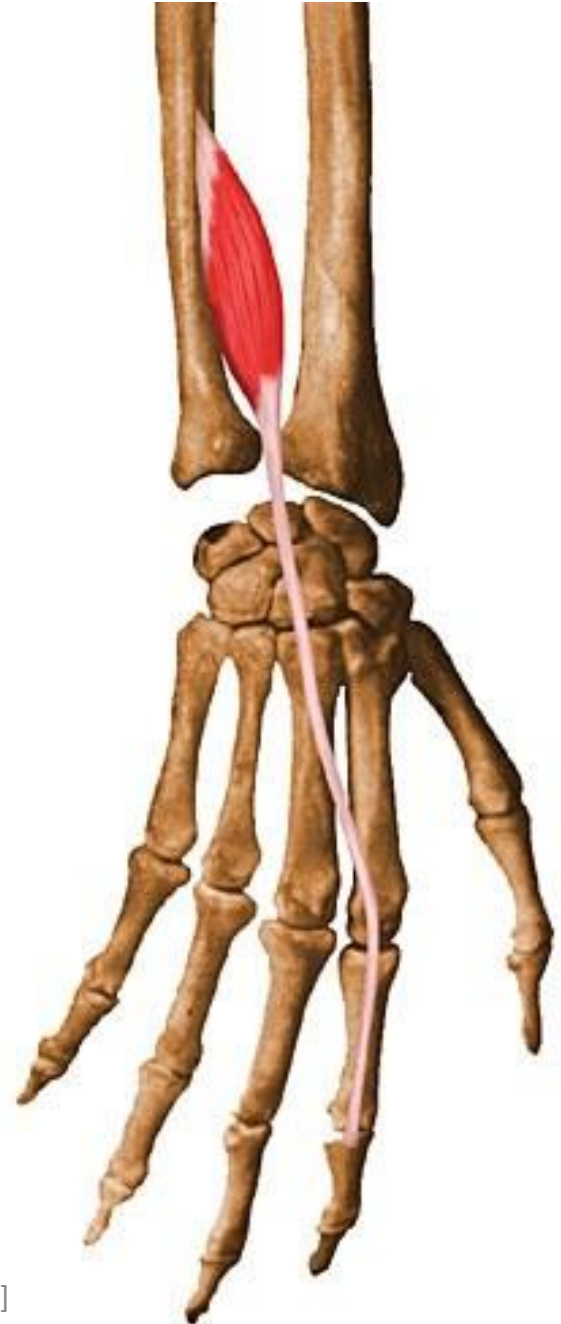
Extensor Policis Brevis

RADIUS



Extensor indicis

ULNA

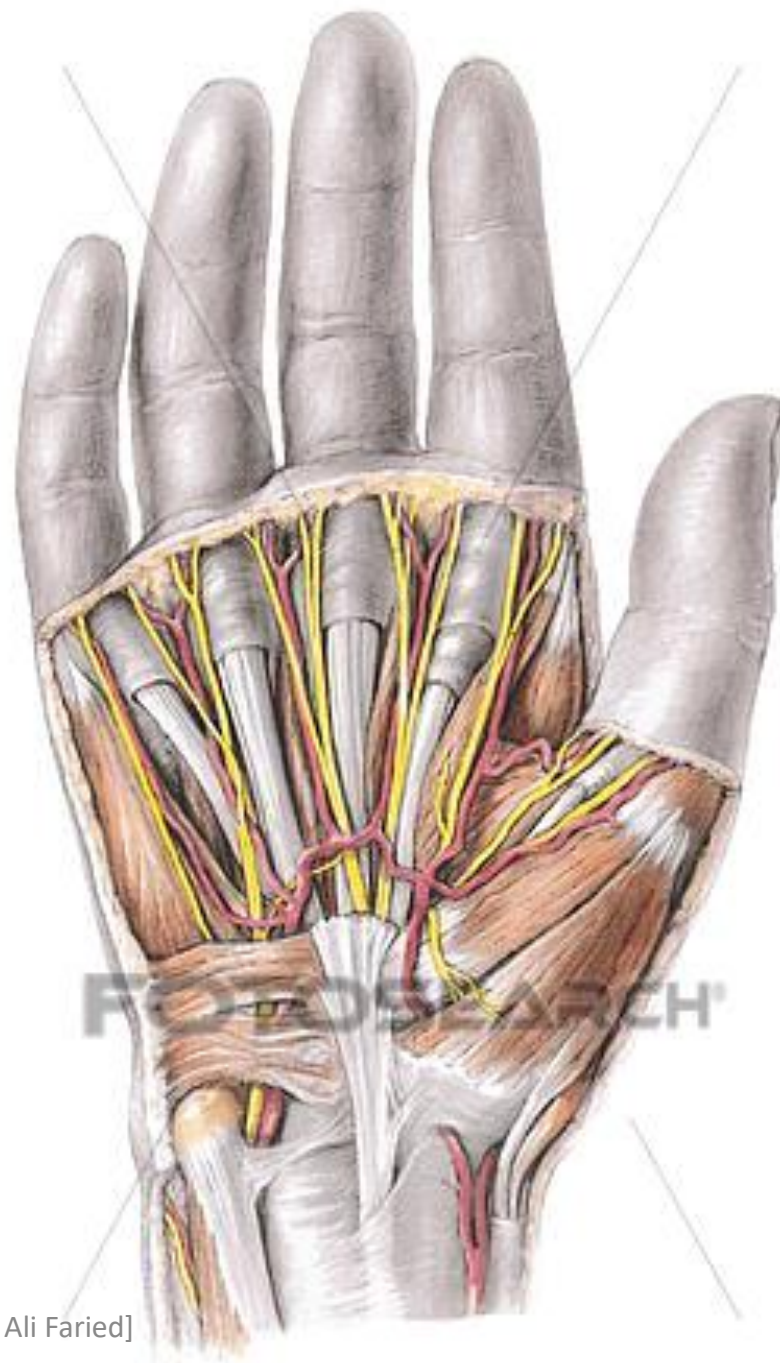
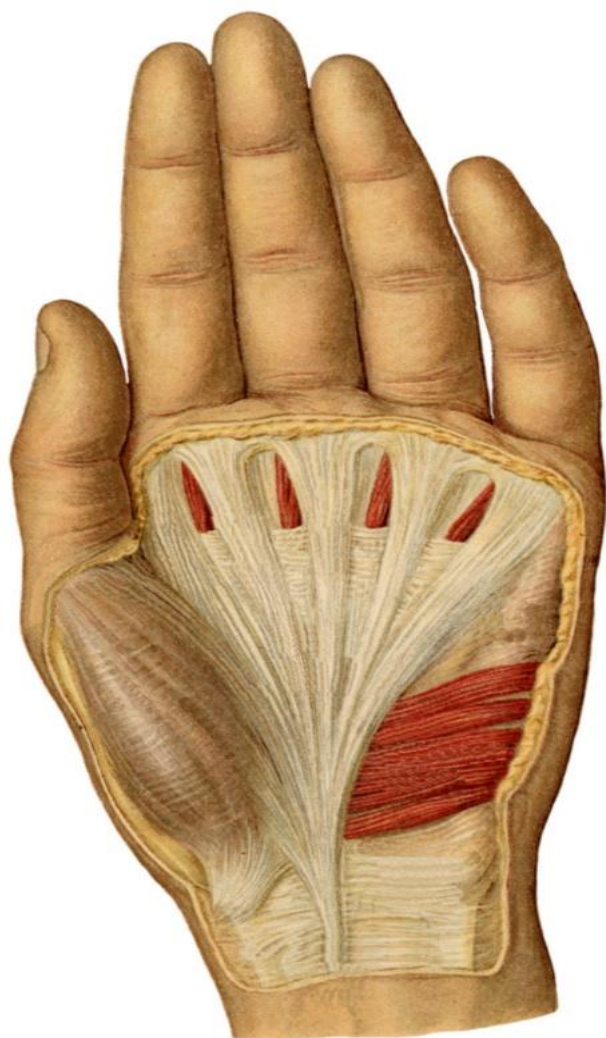

N. Supply ***Radial nerve***

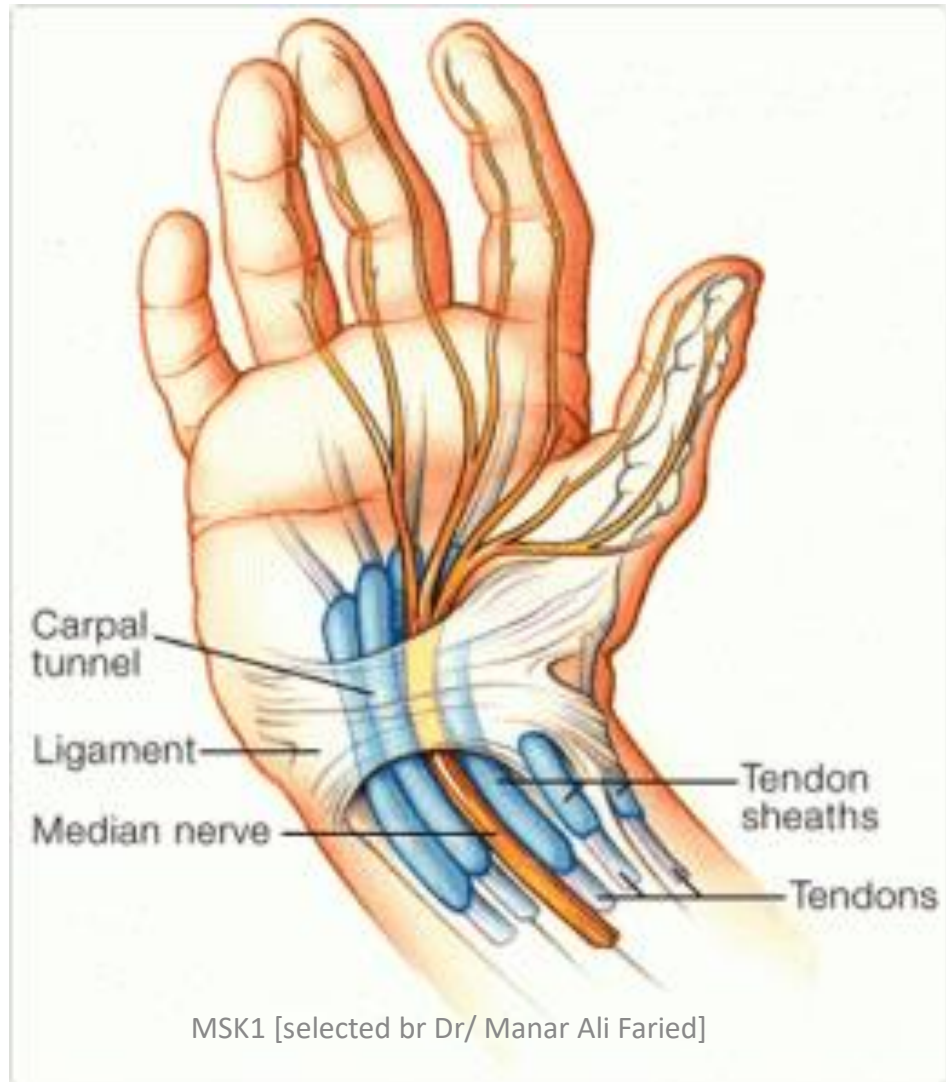
LECTURE [8]

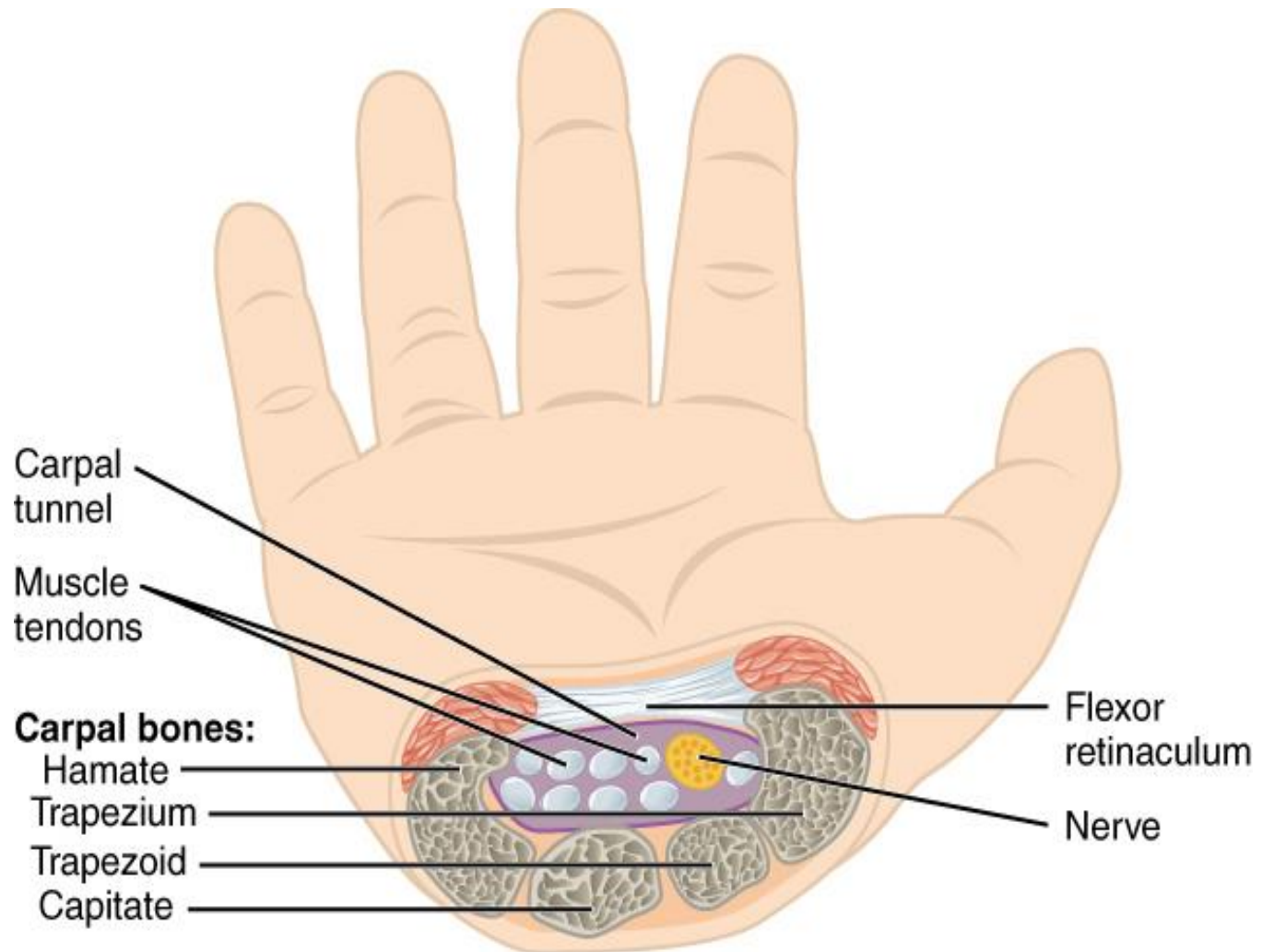


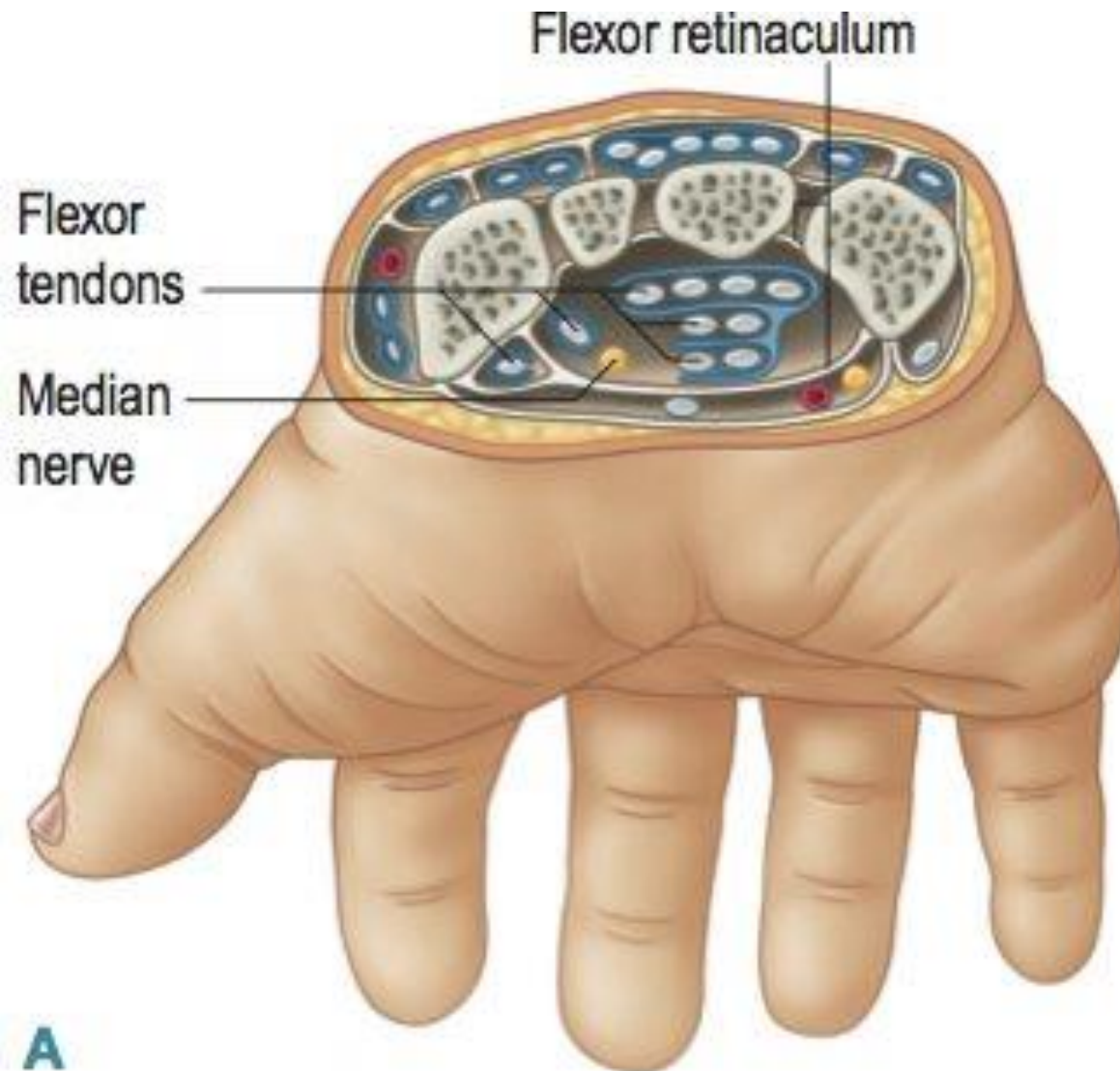
THE HAND

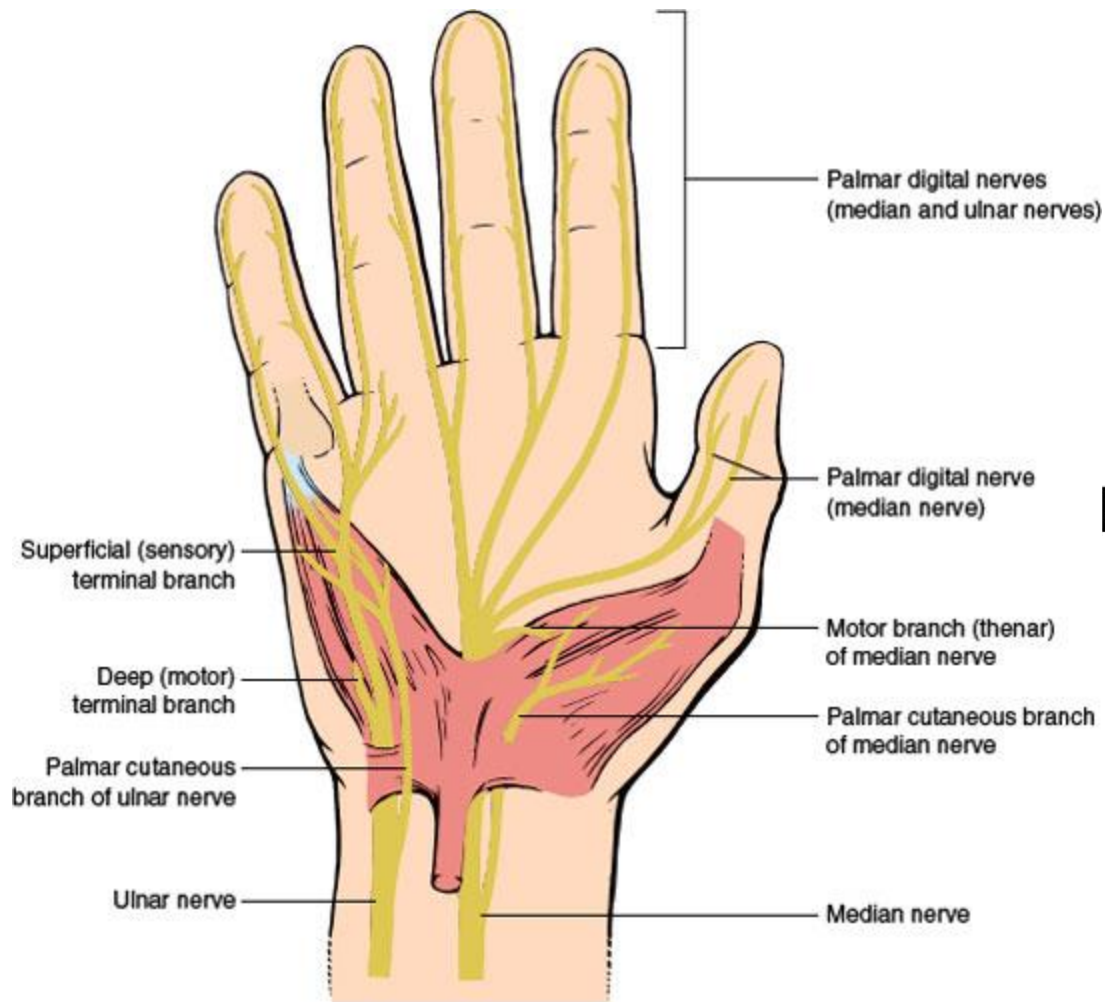


FLEXOR RETINACULUM



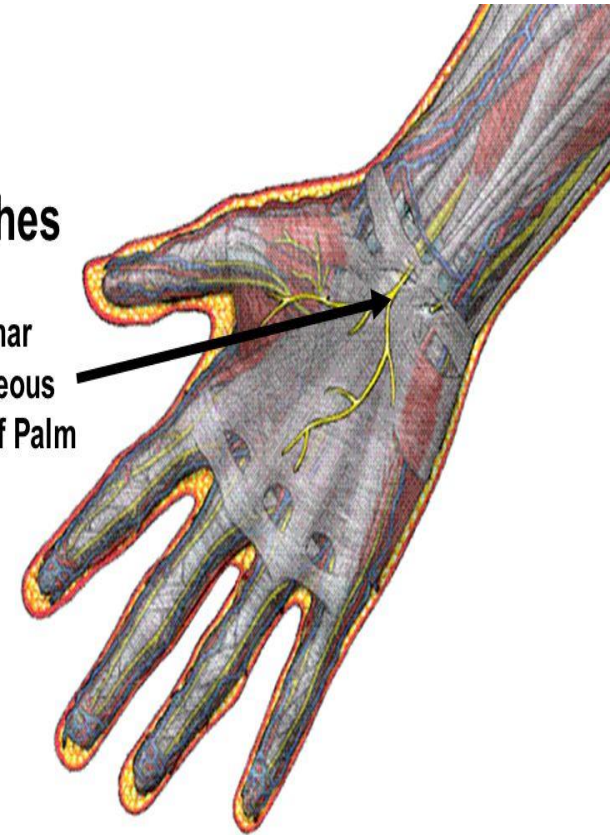


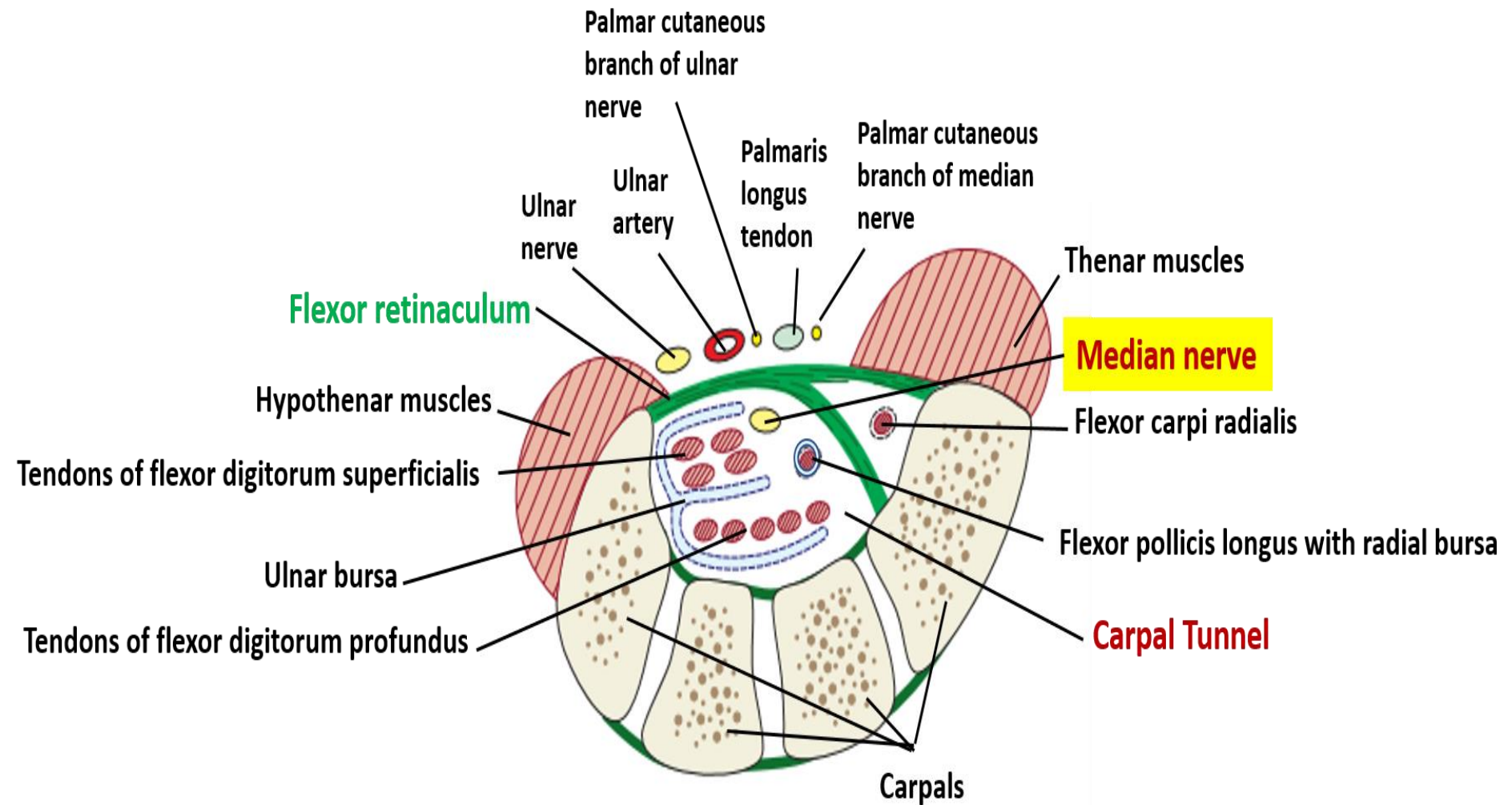




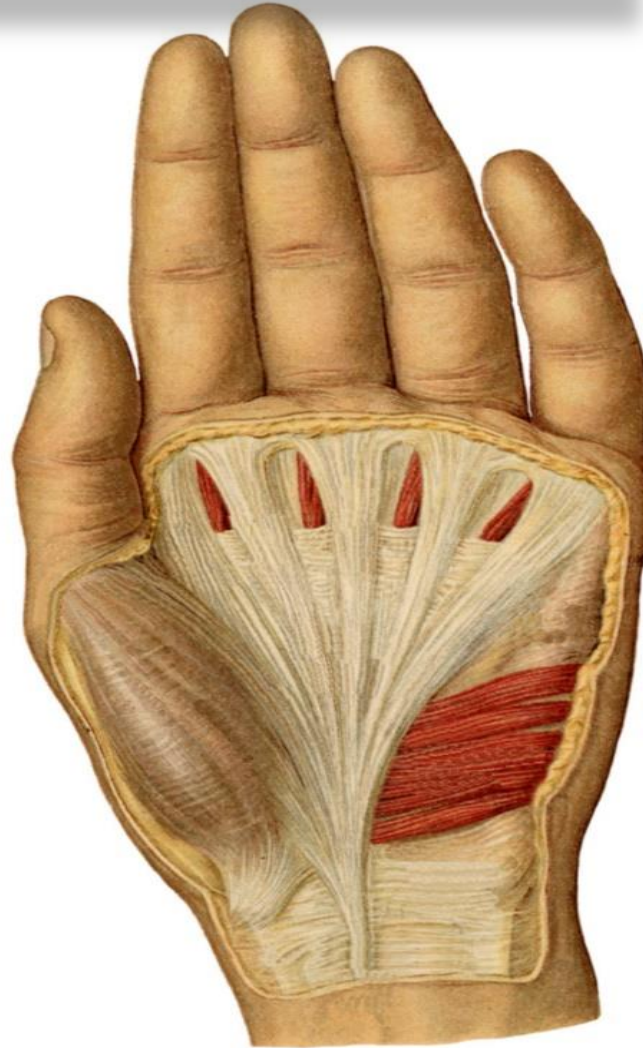Branches

Palmar
Cutaneous
Nerve of Palm

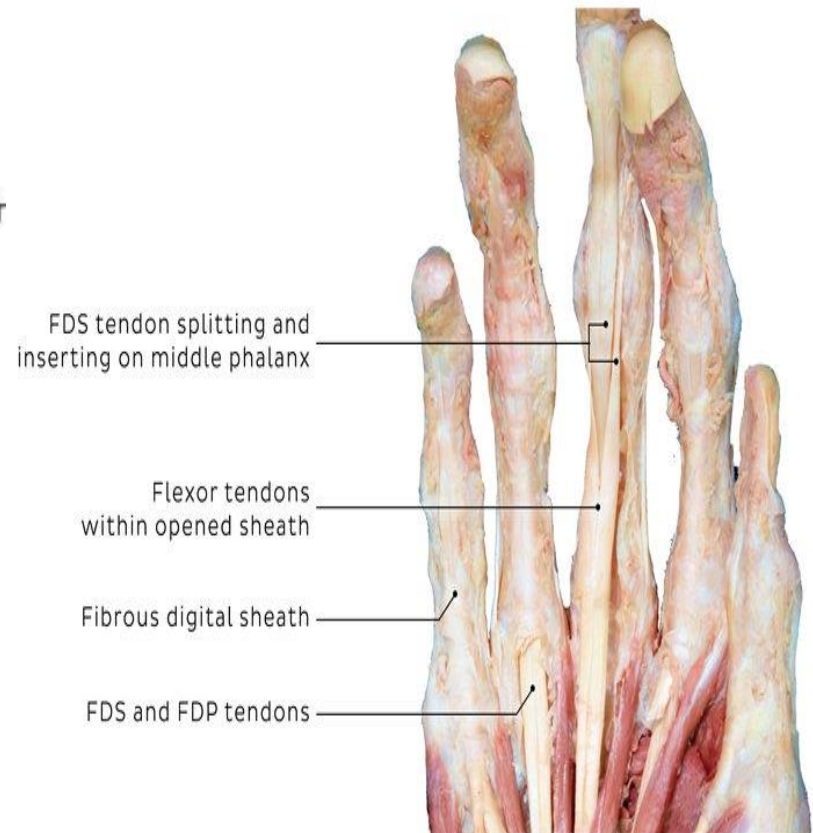
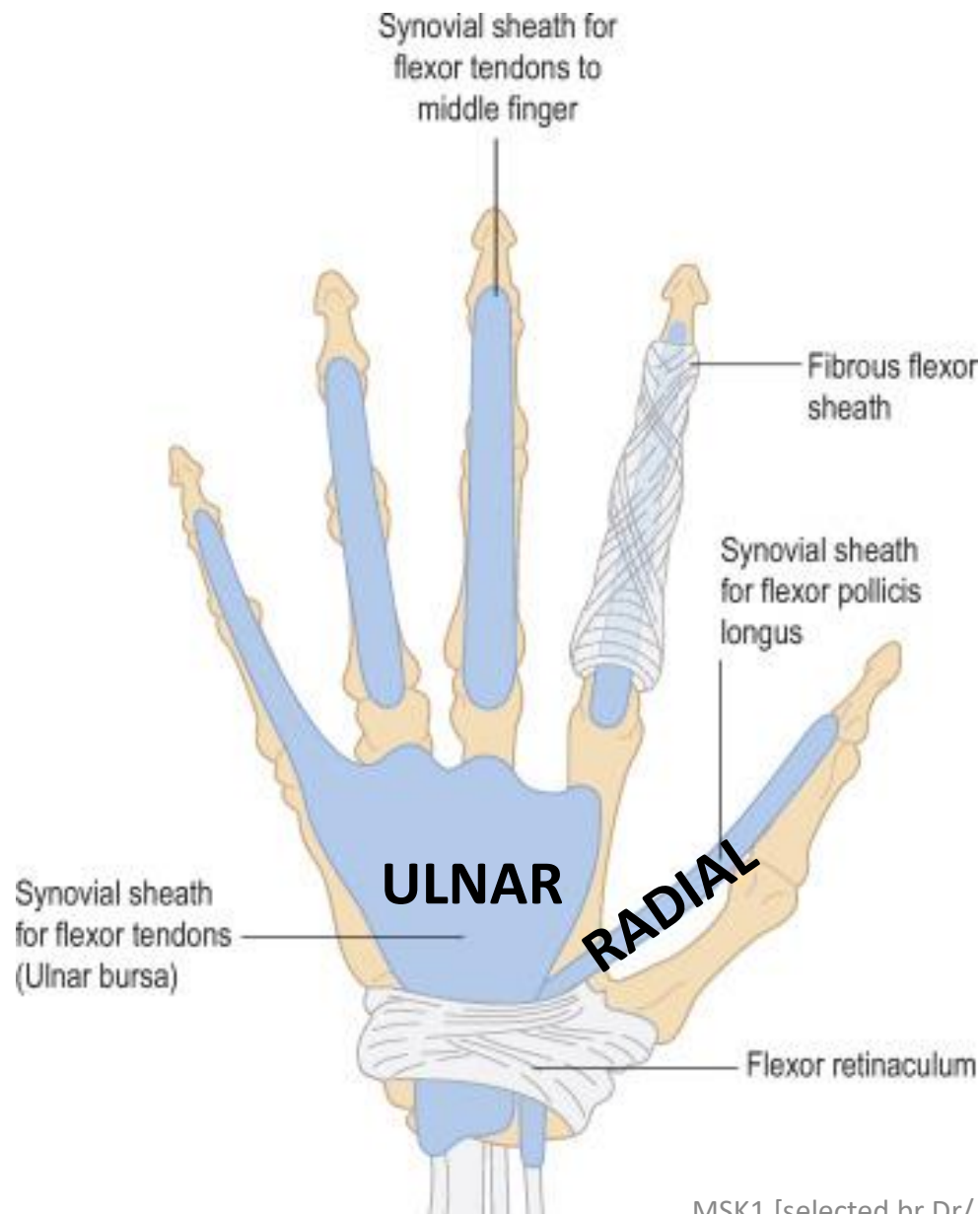




PALMAR APONEUOSIS



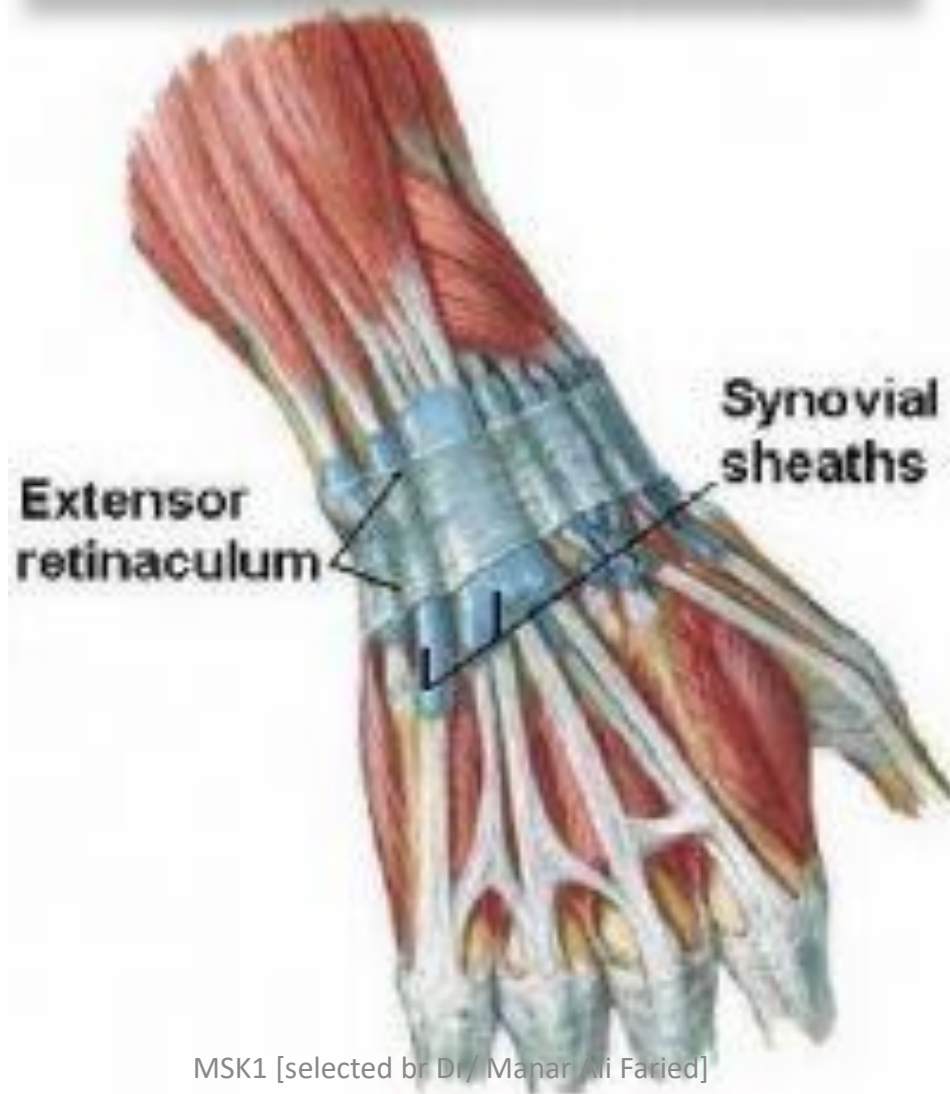
MSK1 [selected by Dr/ Manar Ali Faried]



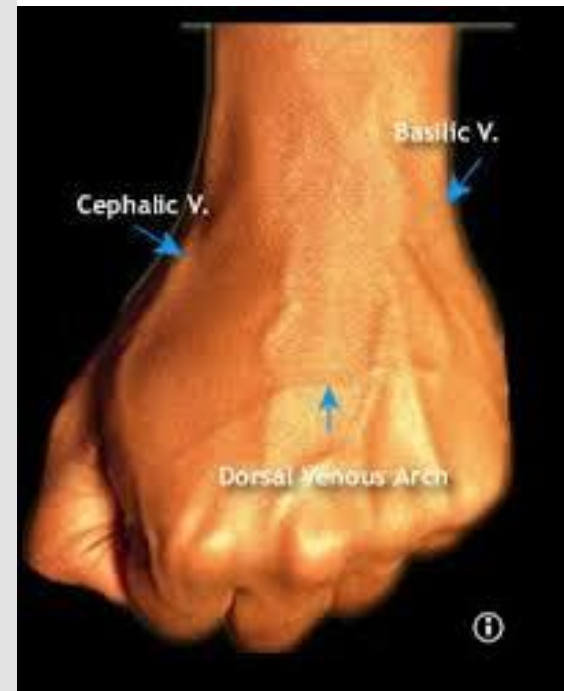
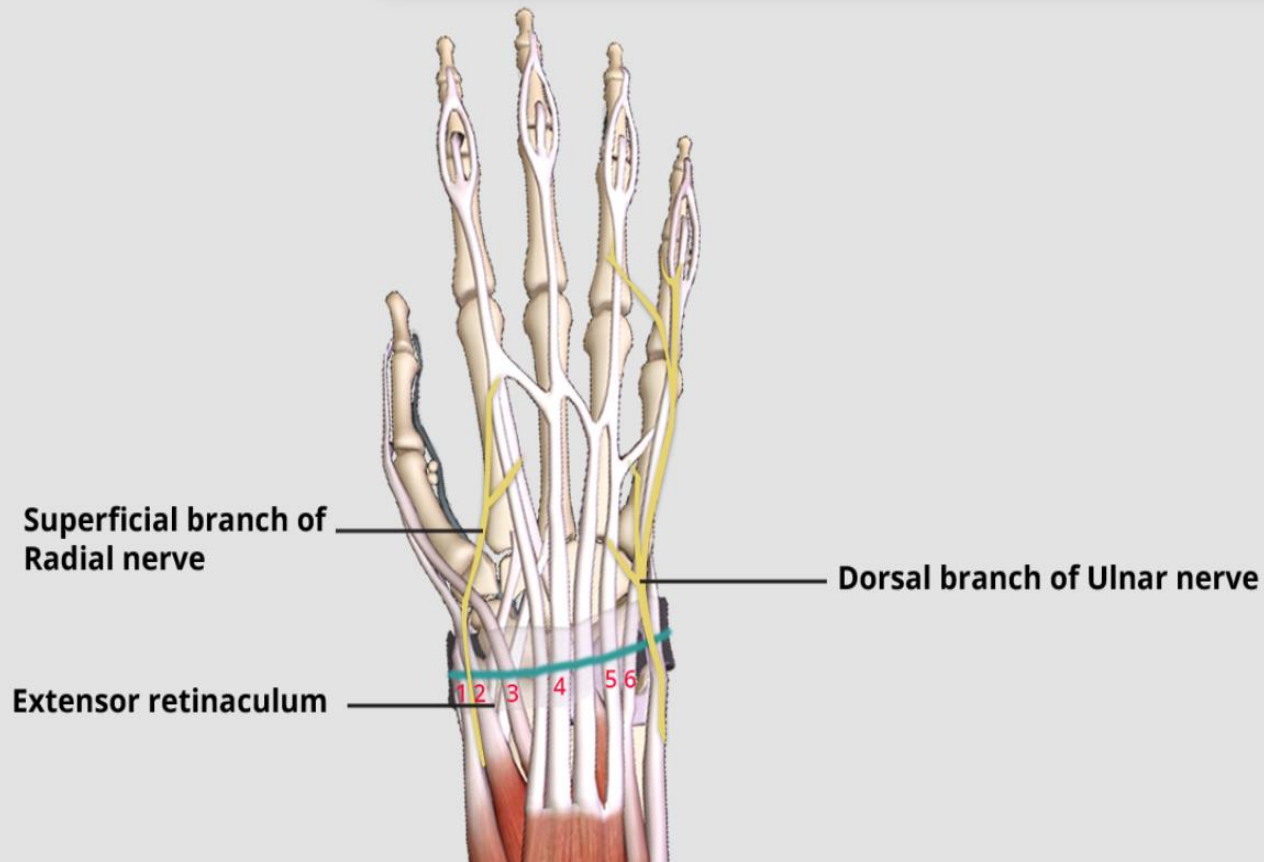
© www.kenhub.com

KEN
HUB

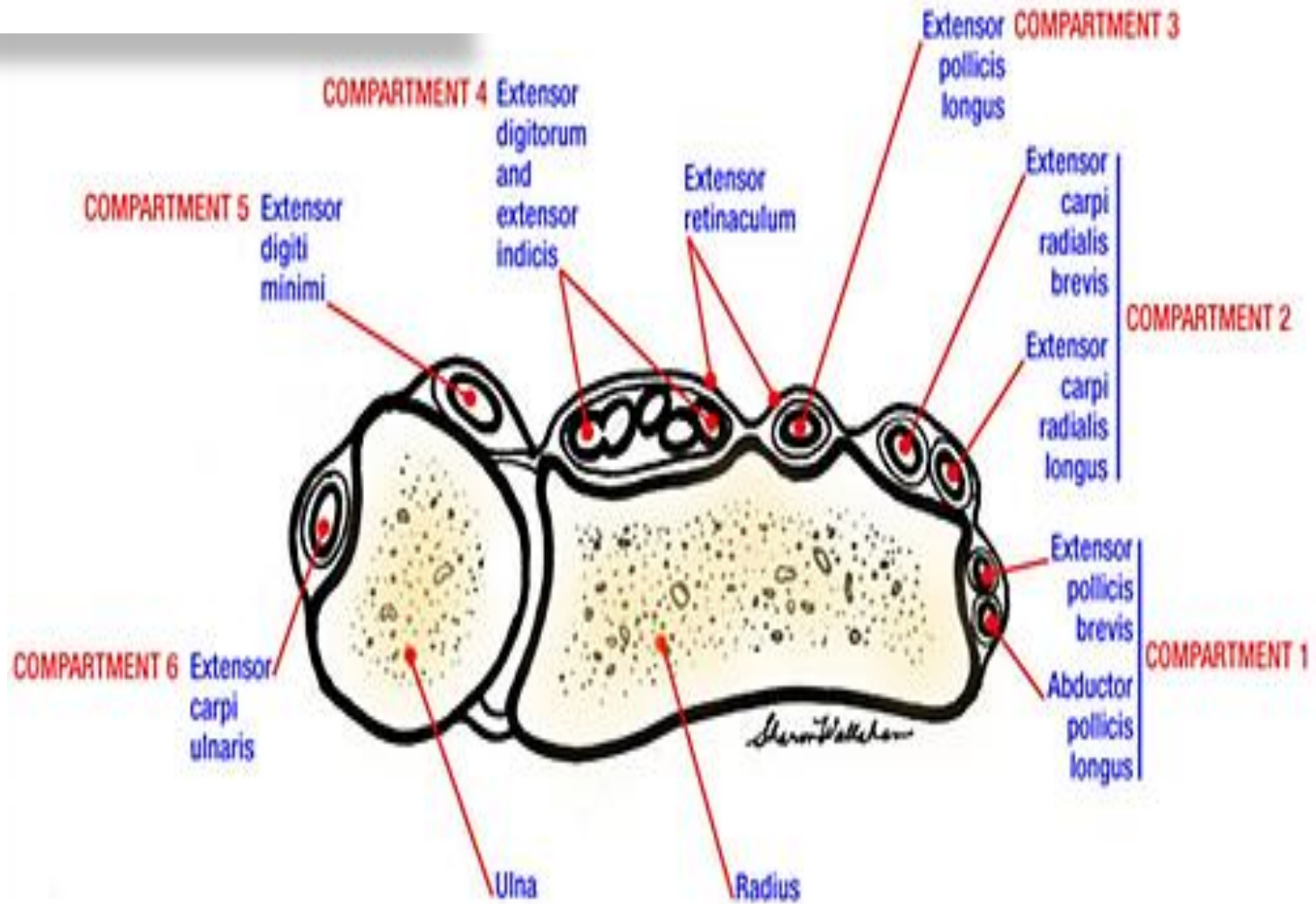
EXTENSOR RETINACULUM



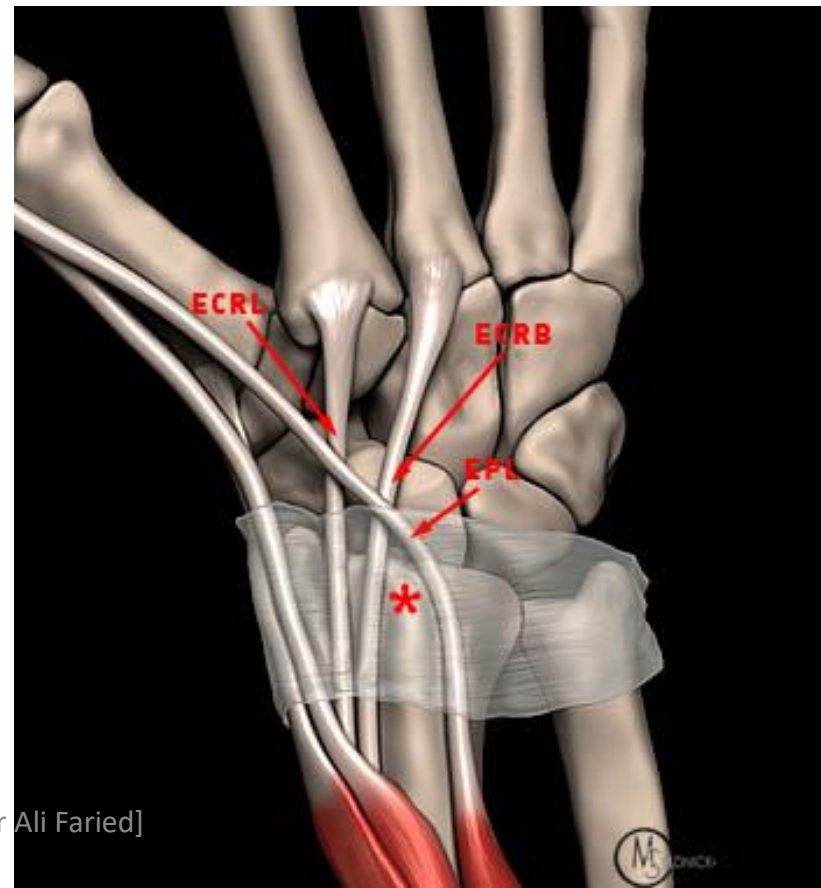
Structures superficial to it

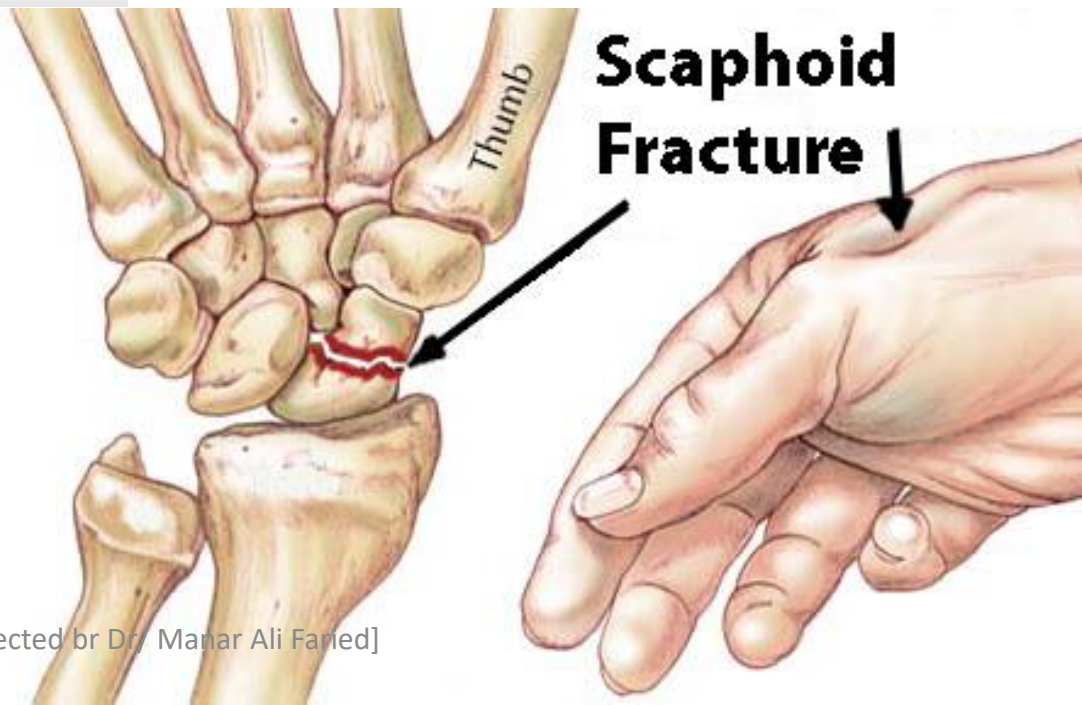
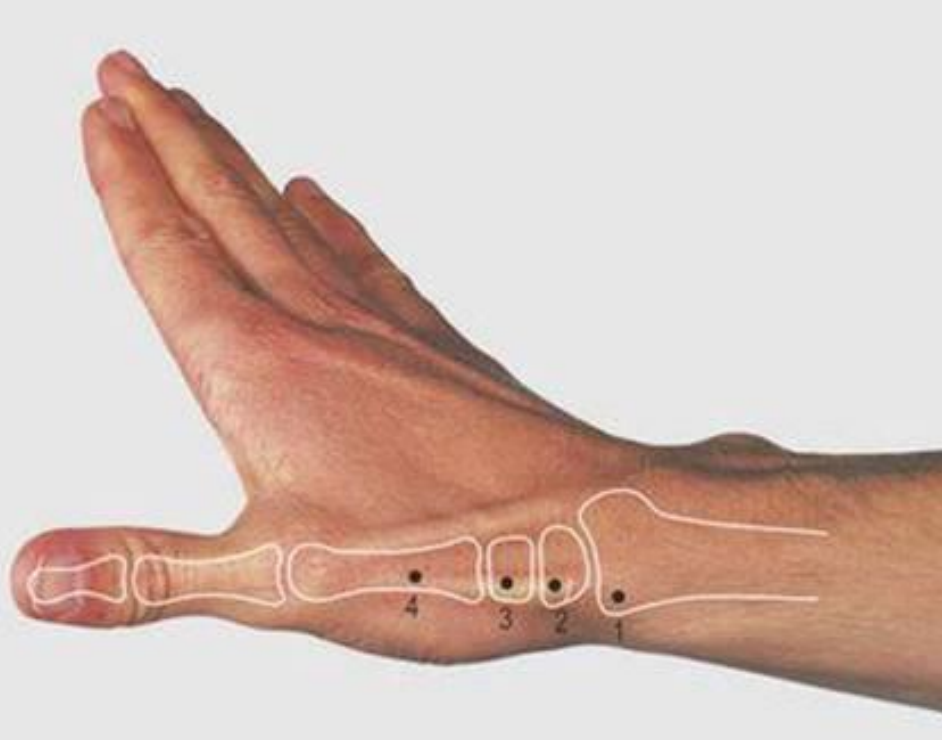


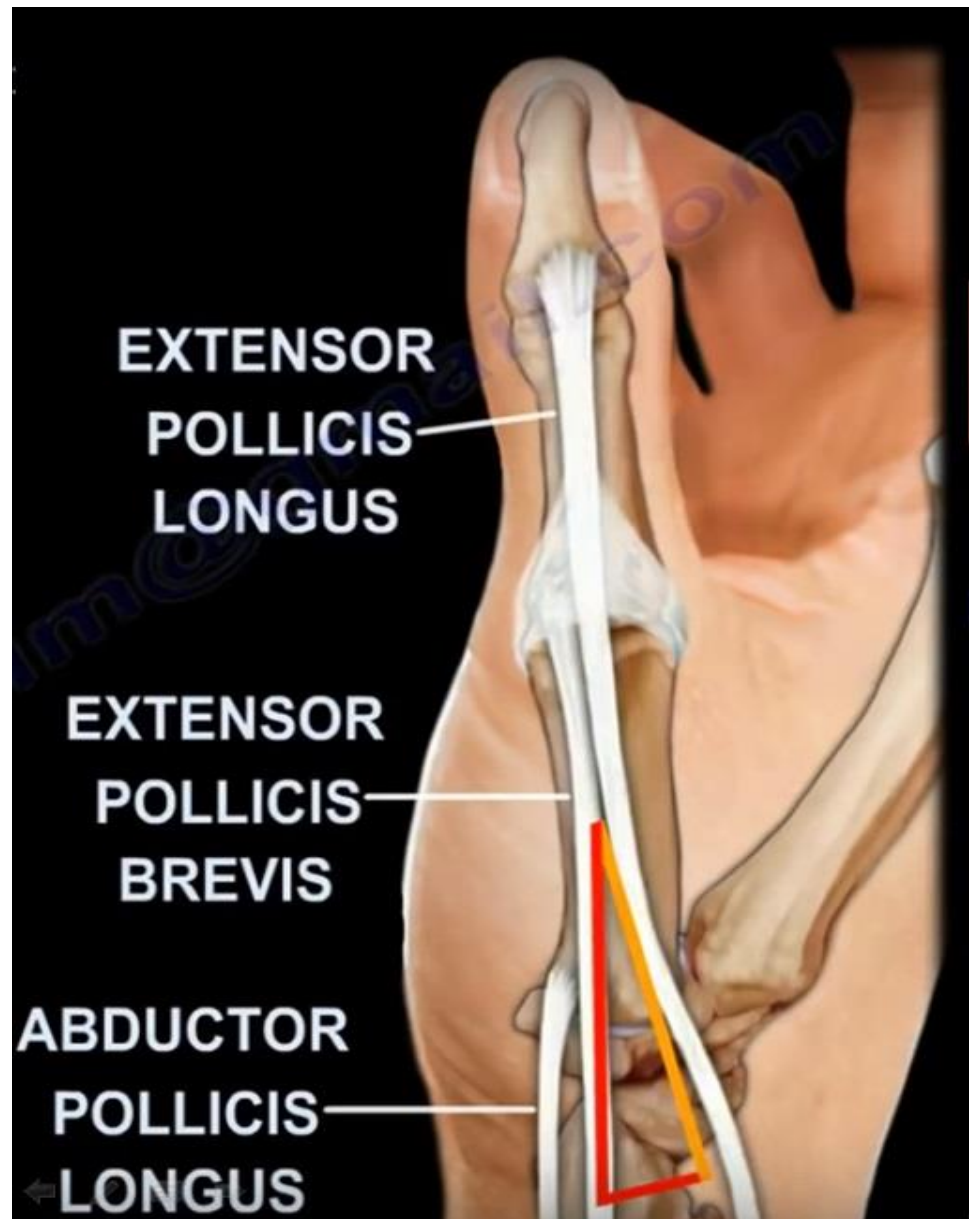
Structures deep to it

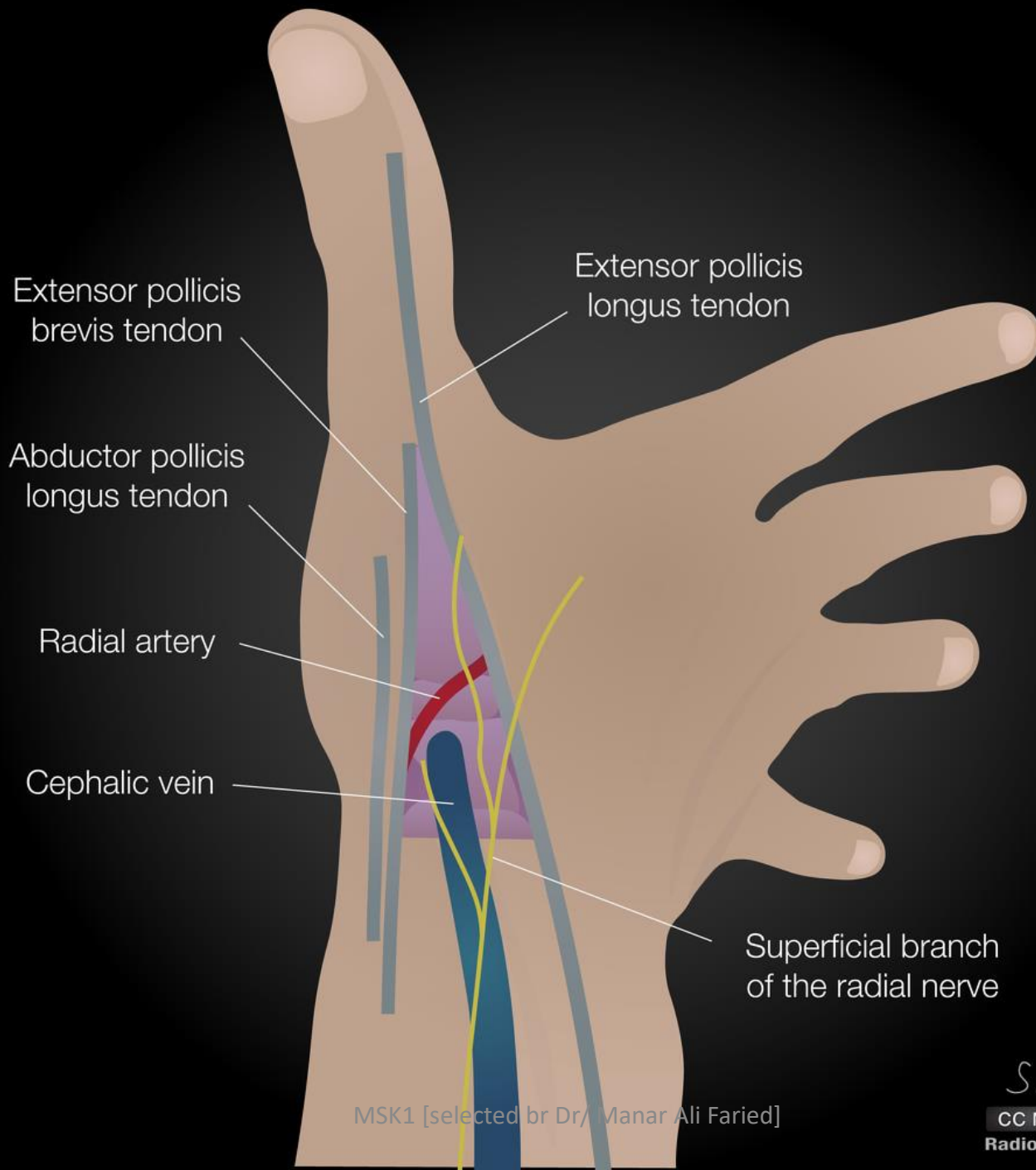


ANATOMICAL SNUFF BOX

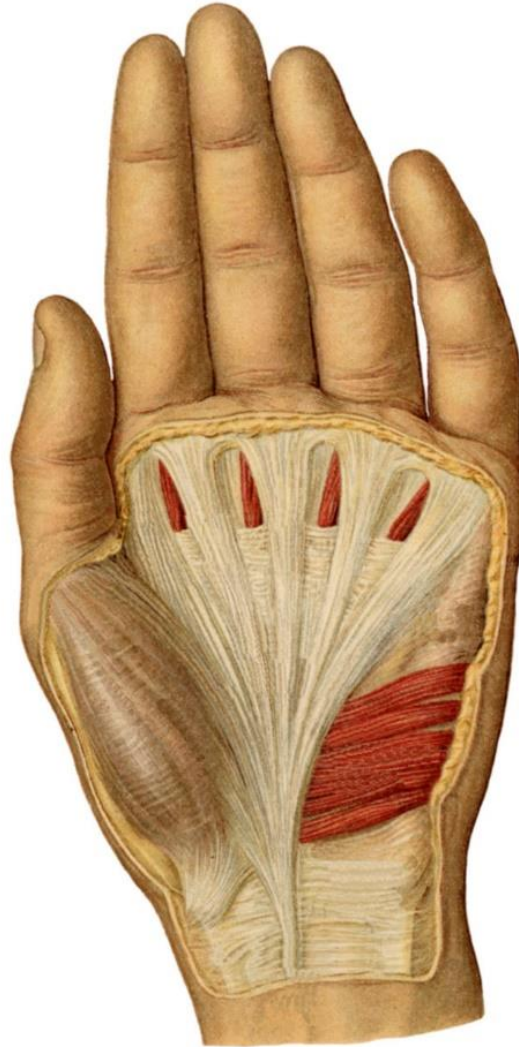




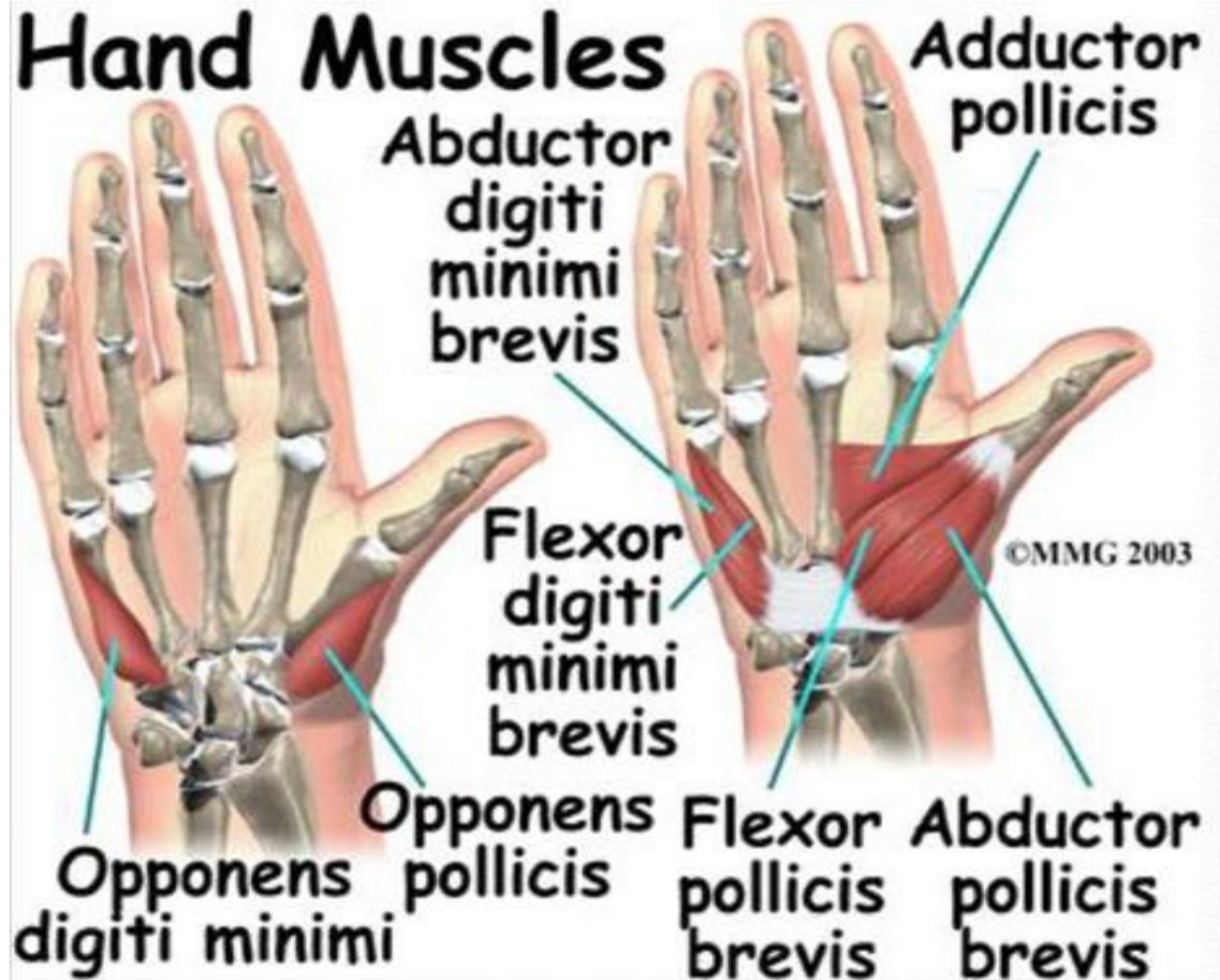


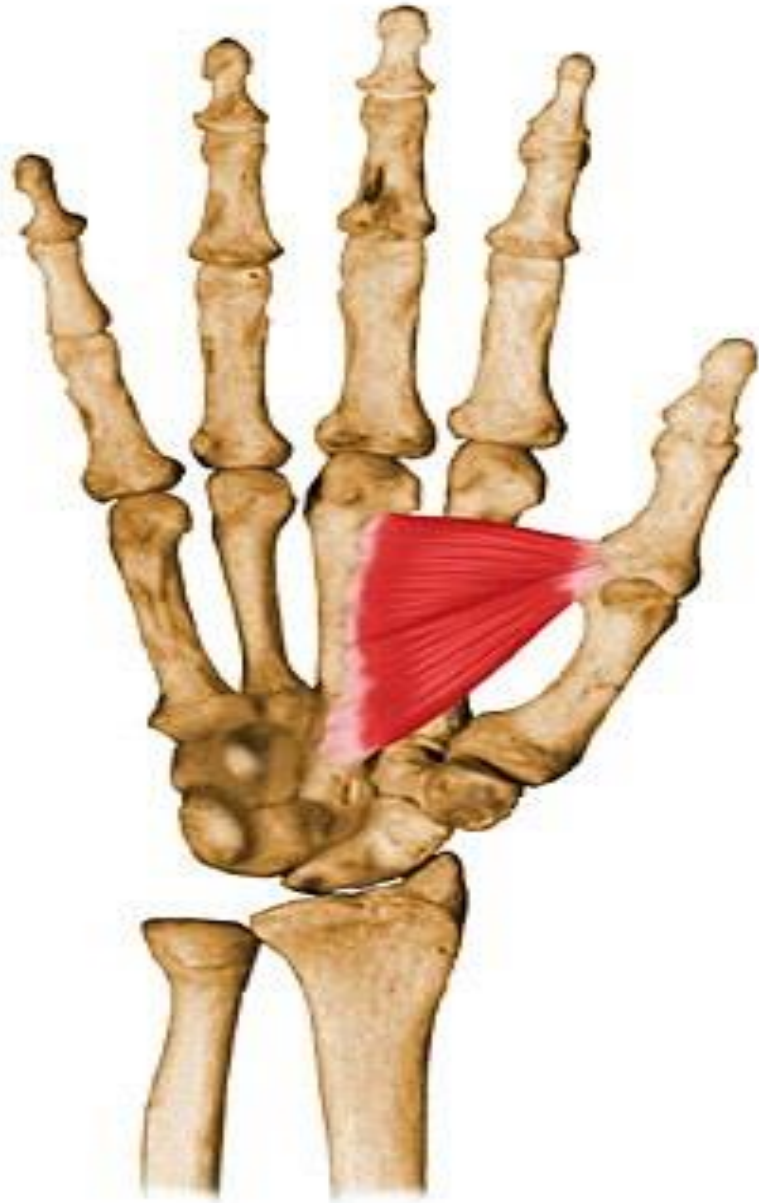MUSCLES



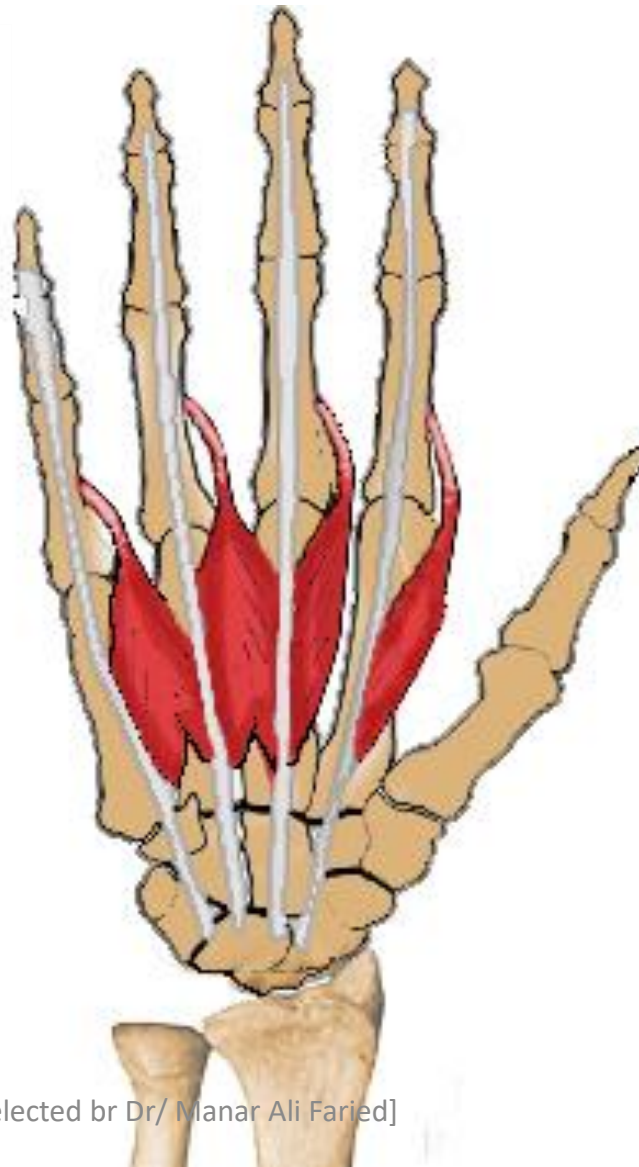
Palmaris
brevis



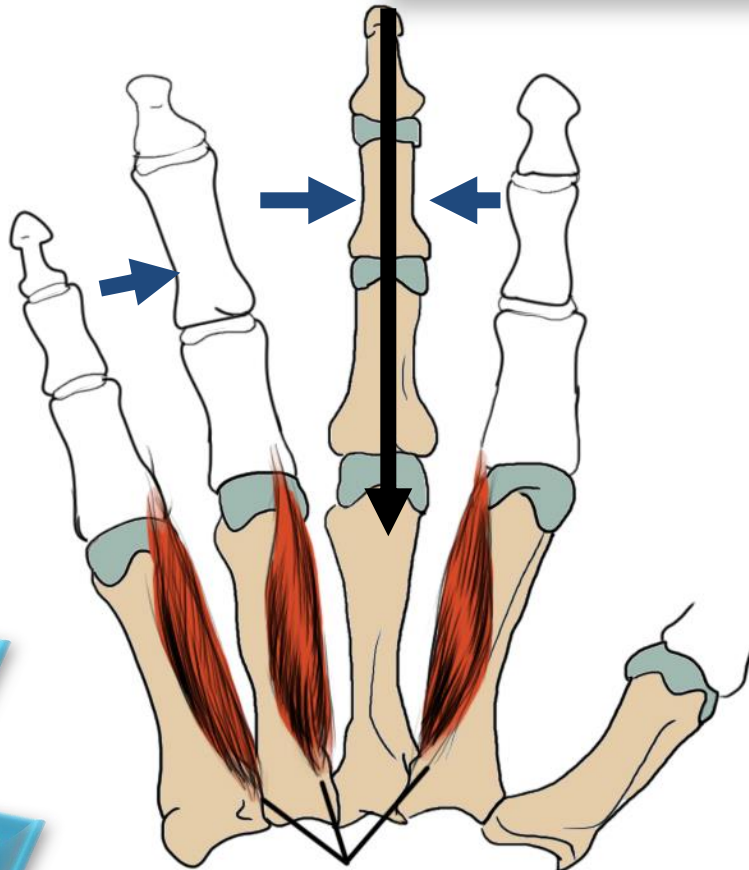
Adductor pollicis



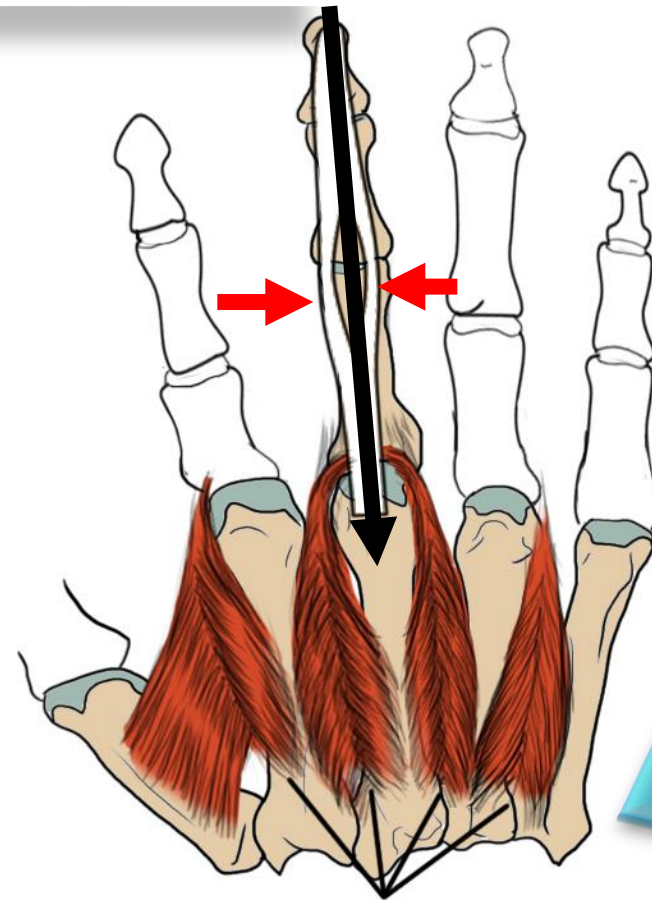
Lumbricals



Interossei

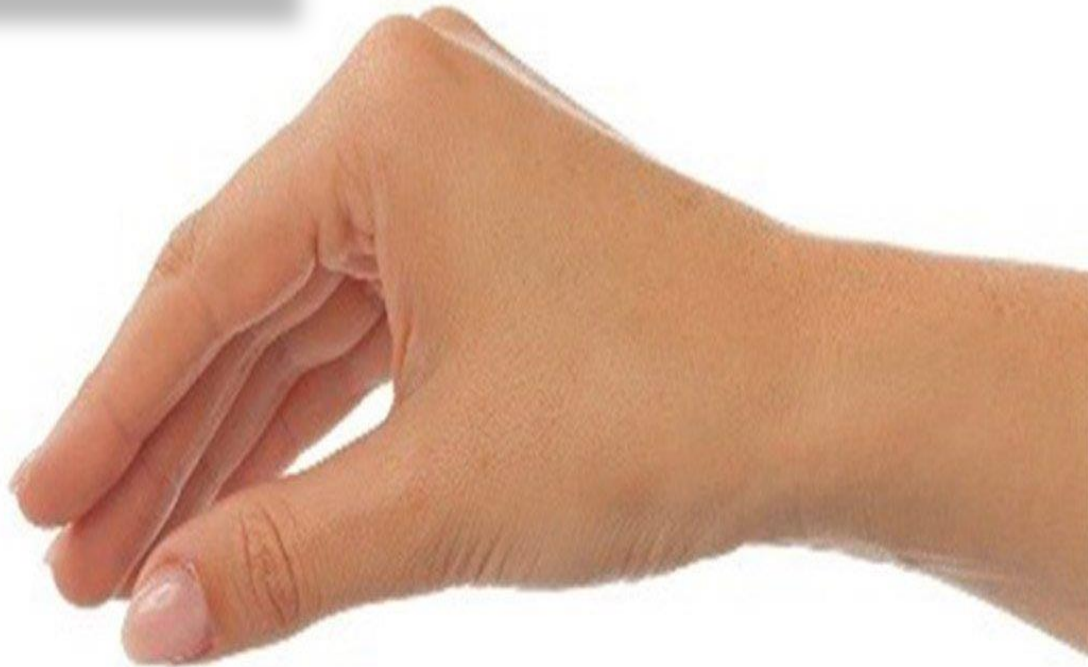

Palmar interossei



Dorsal interossei

writing position



**All are supplied by the ulnar nerve
EXCEPT**

Thenar

**Lateral 2
lumbricals**

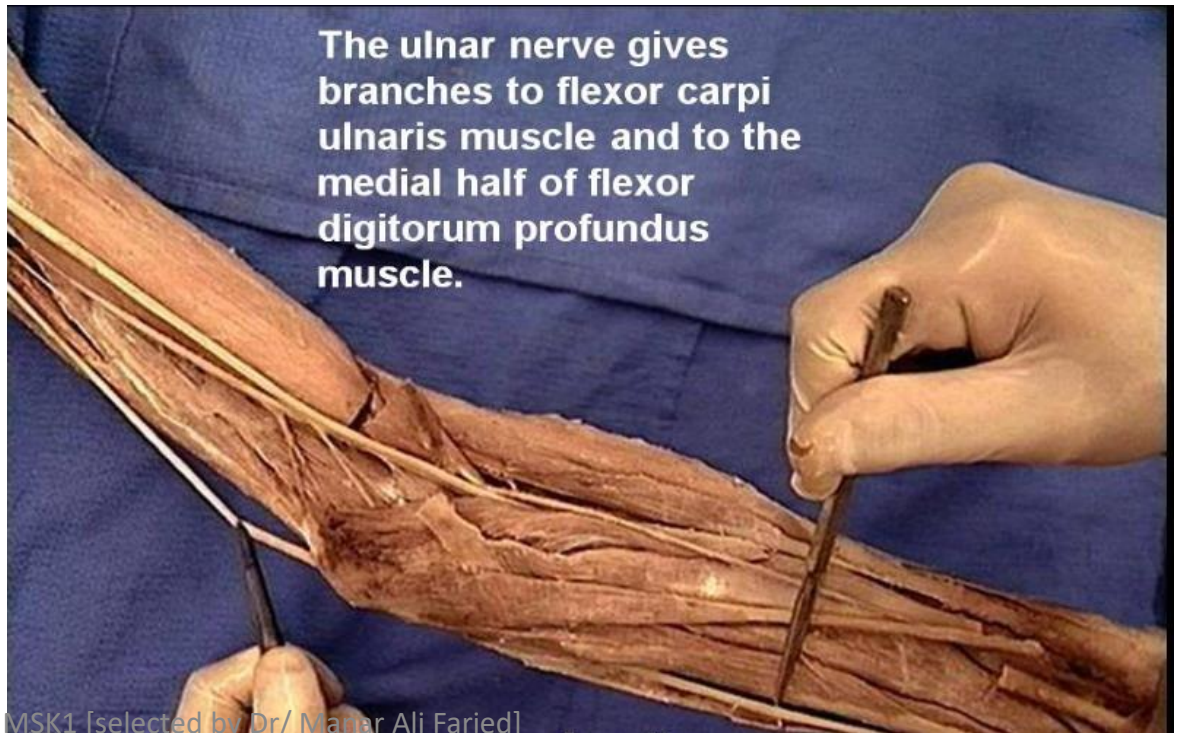
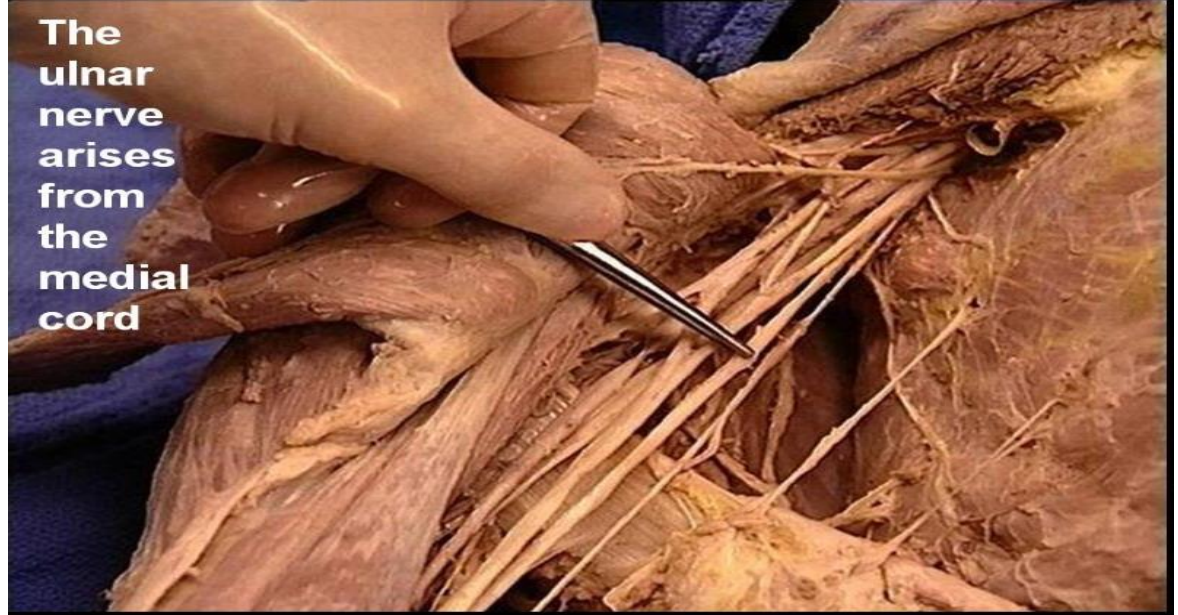
By median nerve

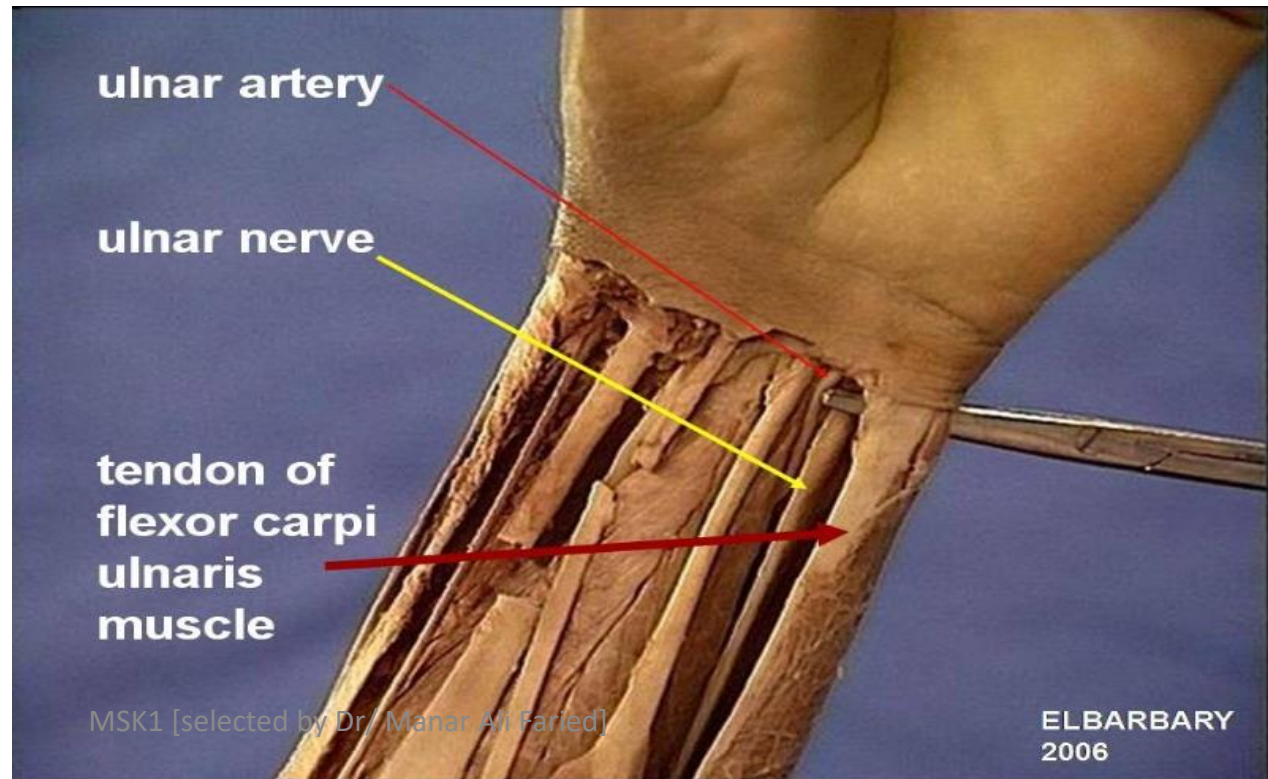
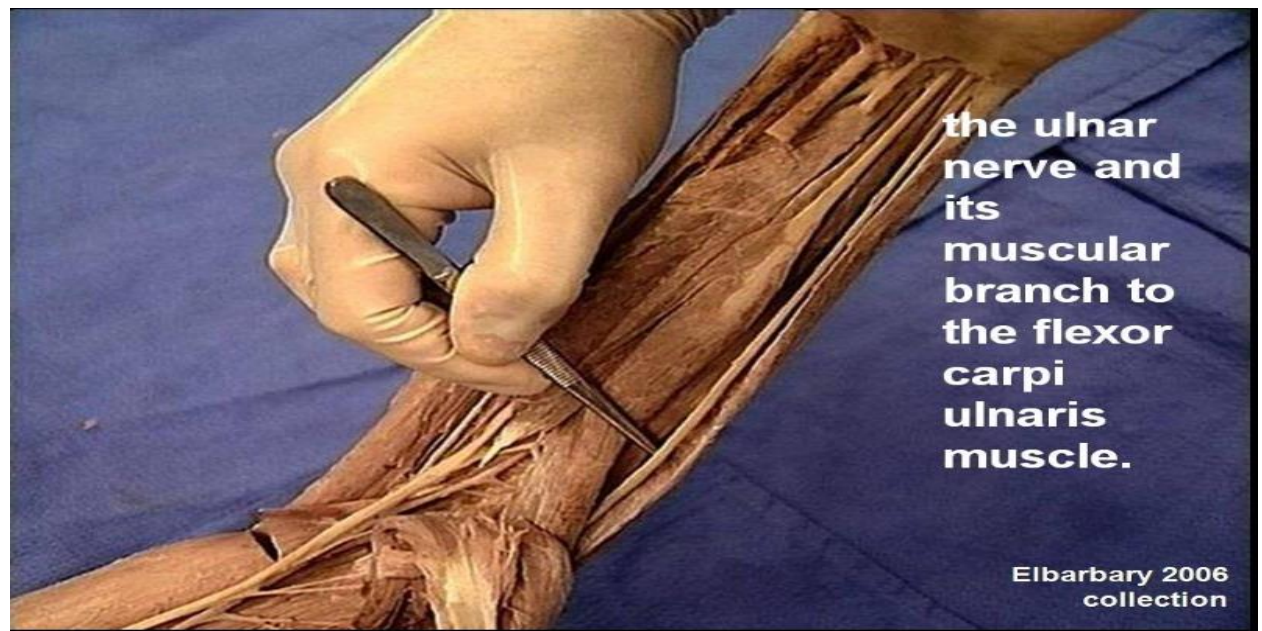
LECTURE [9]



PERIPHERAL NERVES OF THE UPPER LIMB

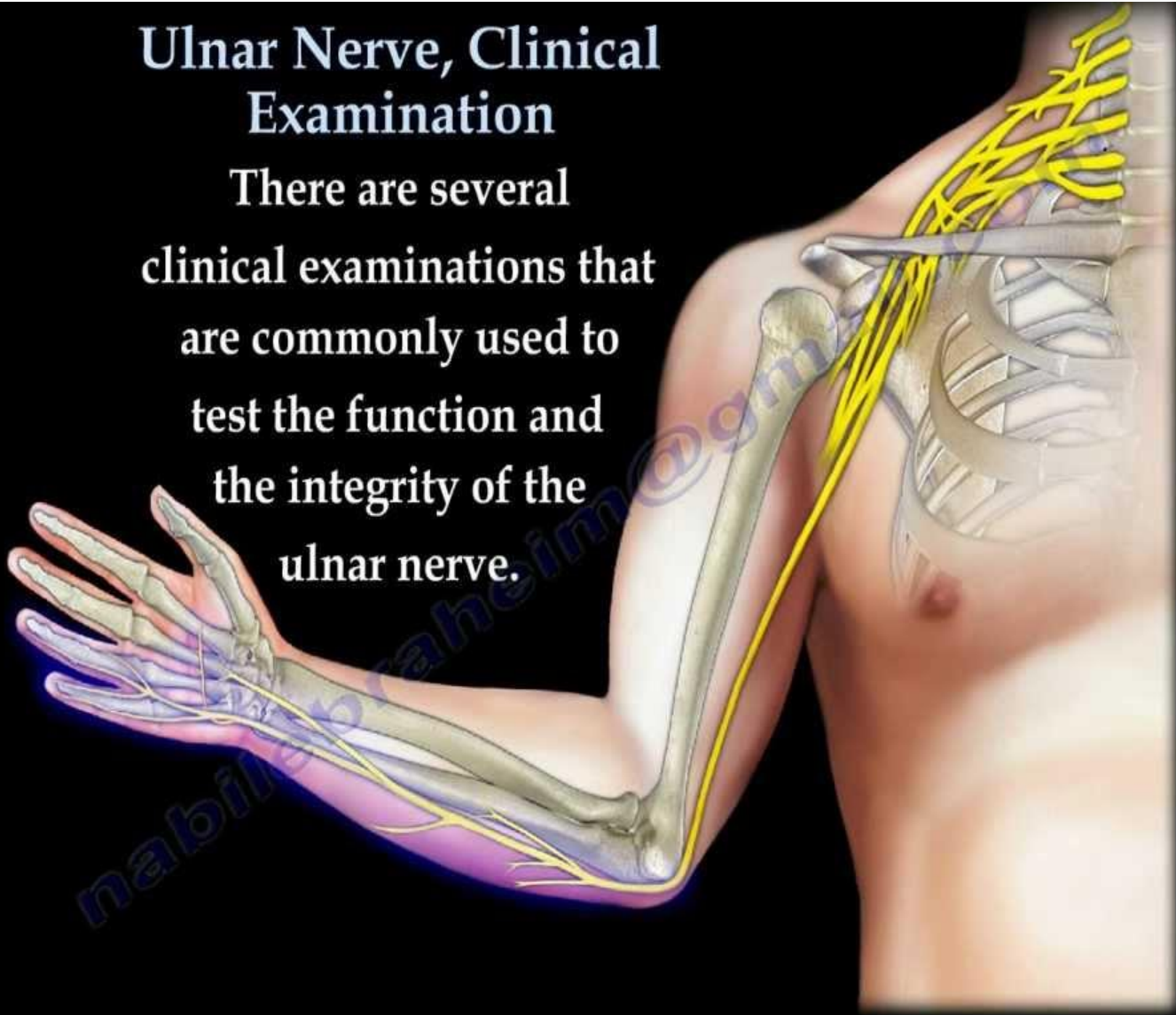
Ulnar Nerve

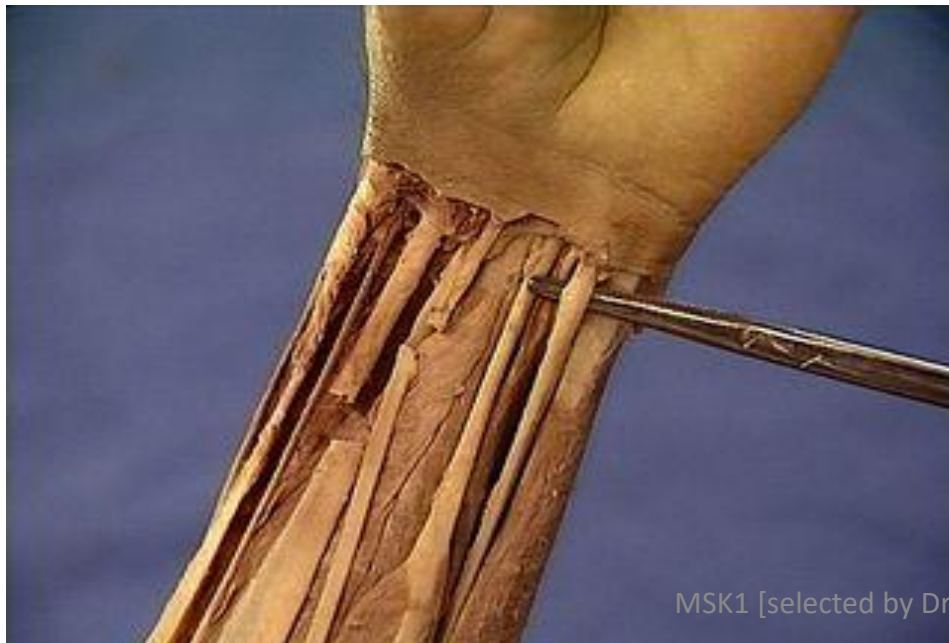
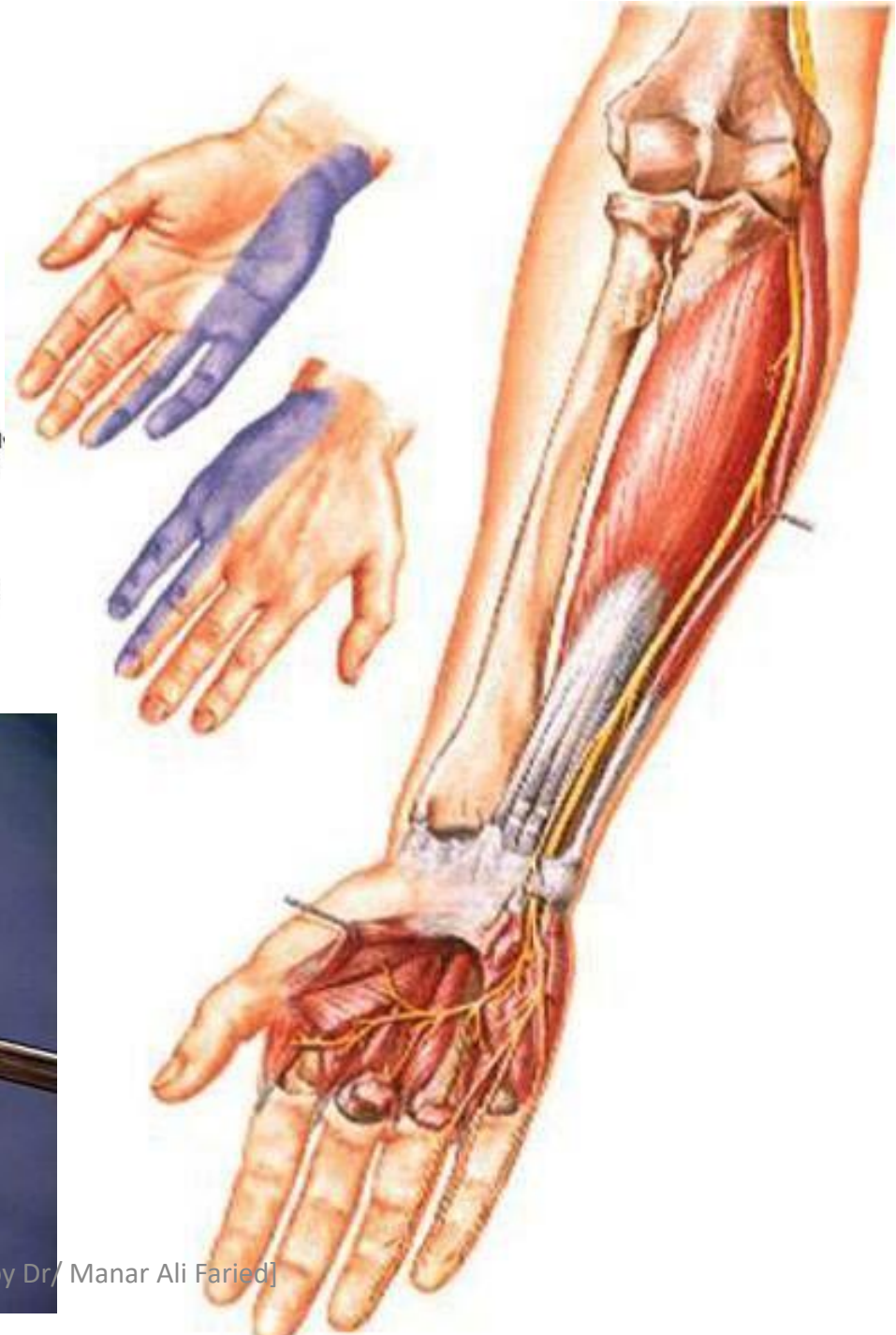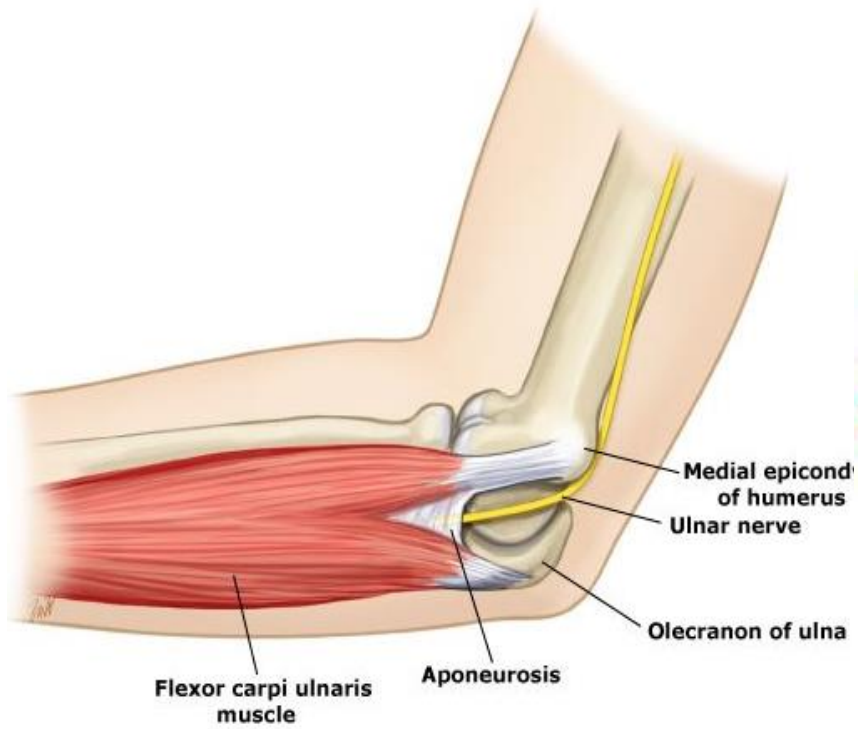


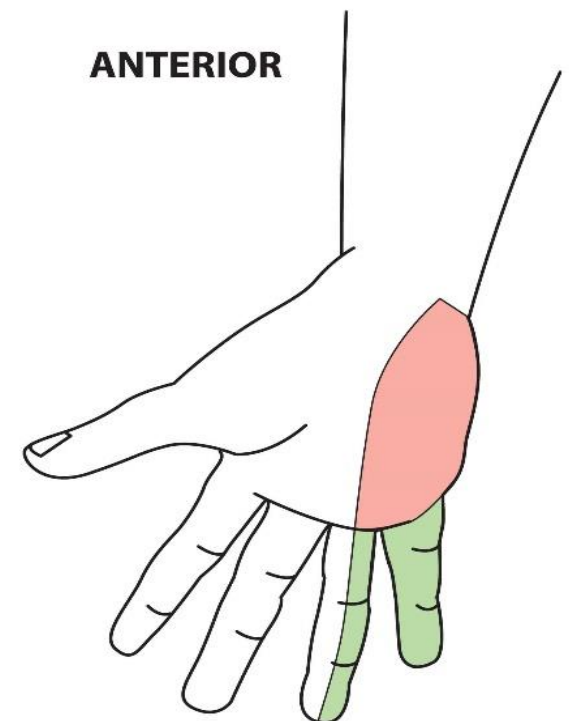
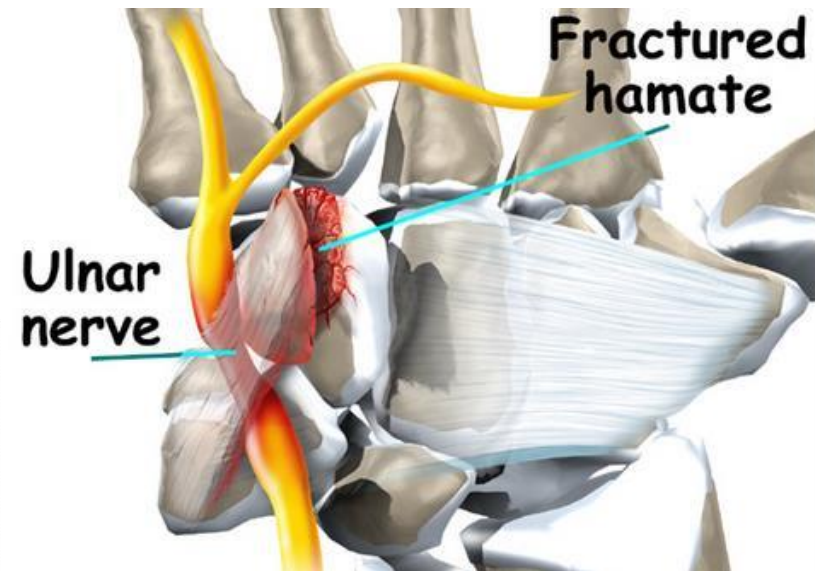
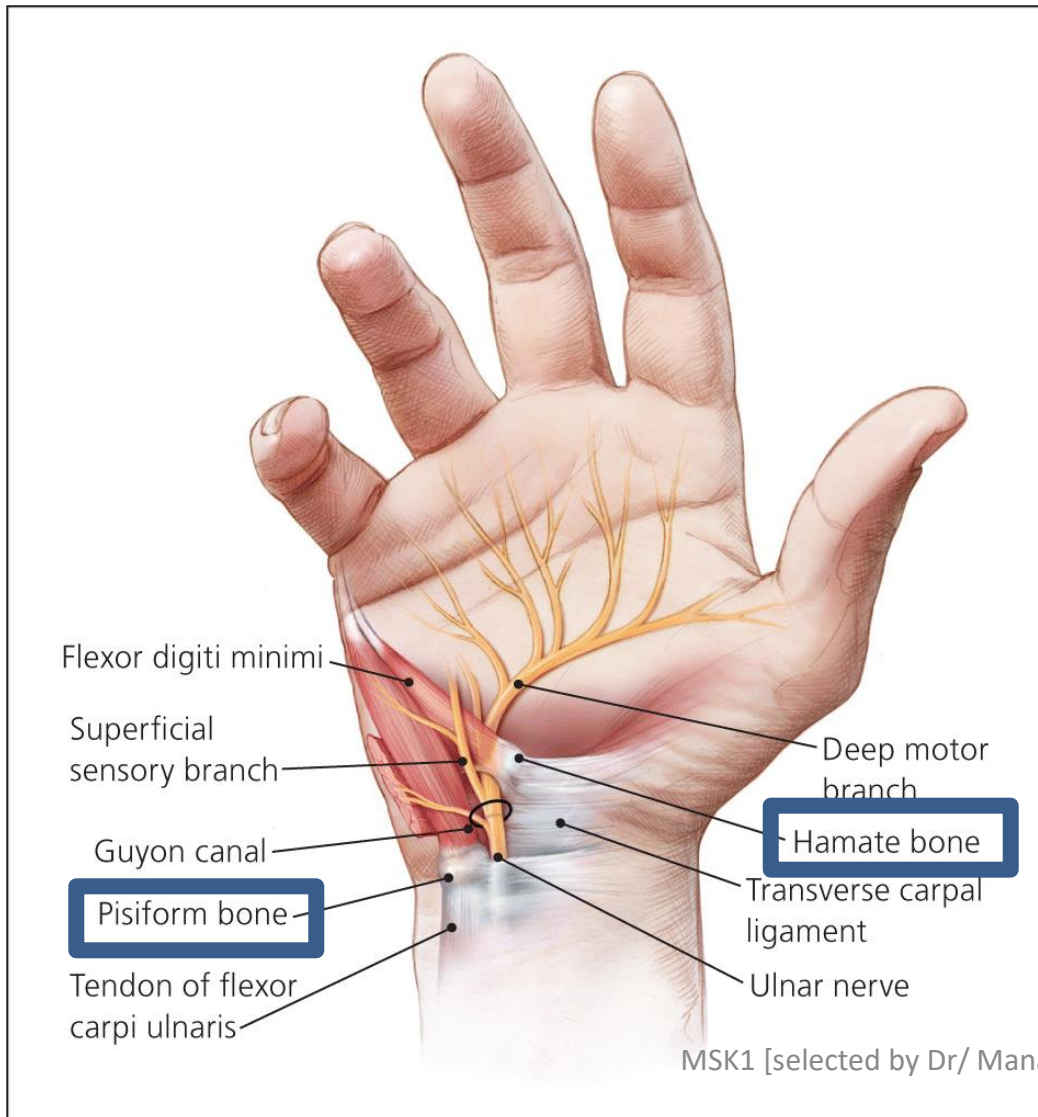


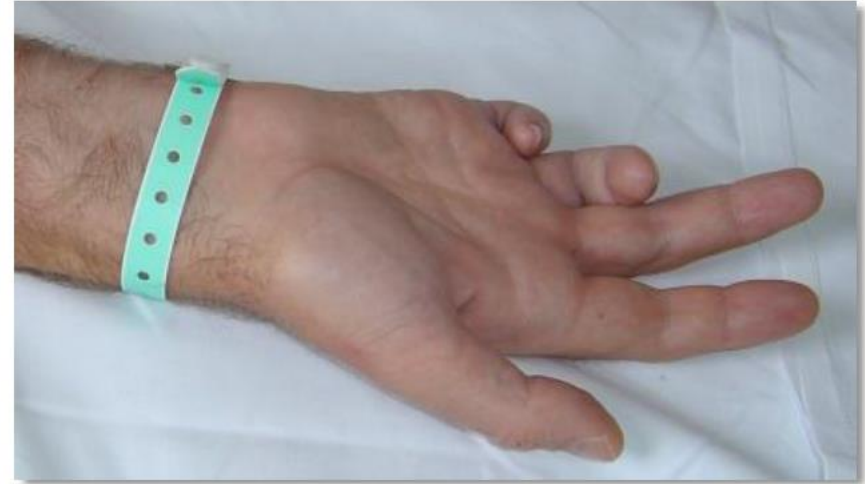Ulnar Nerve, Clinical Examination

There are several clinical examinations that are commonly used to test the function and the integrity of the ulnar nerve.

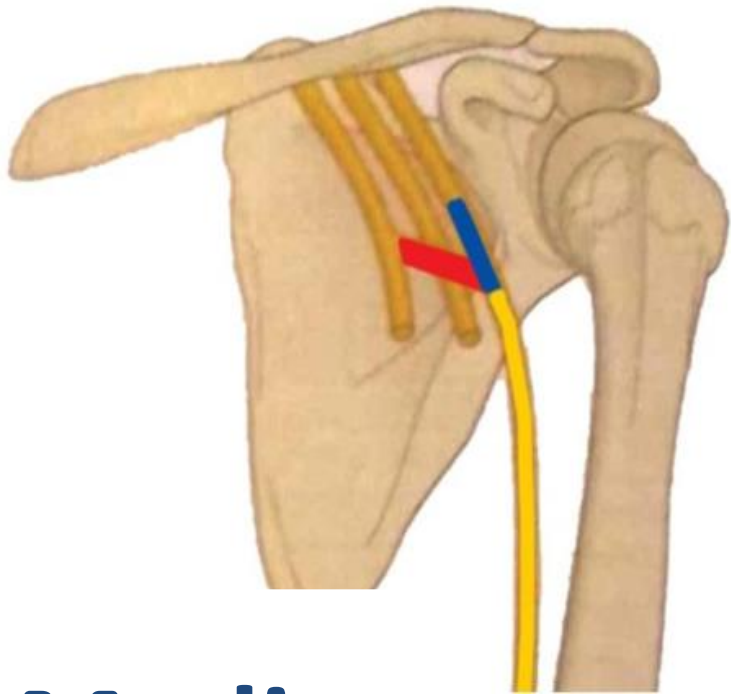




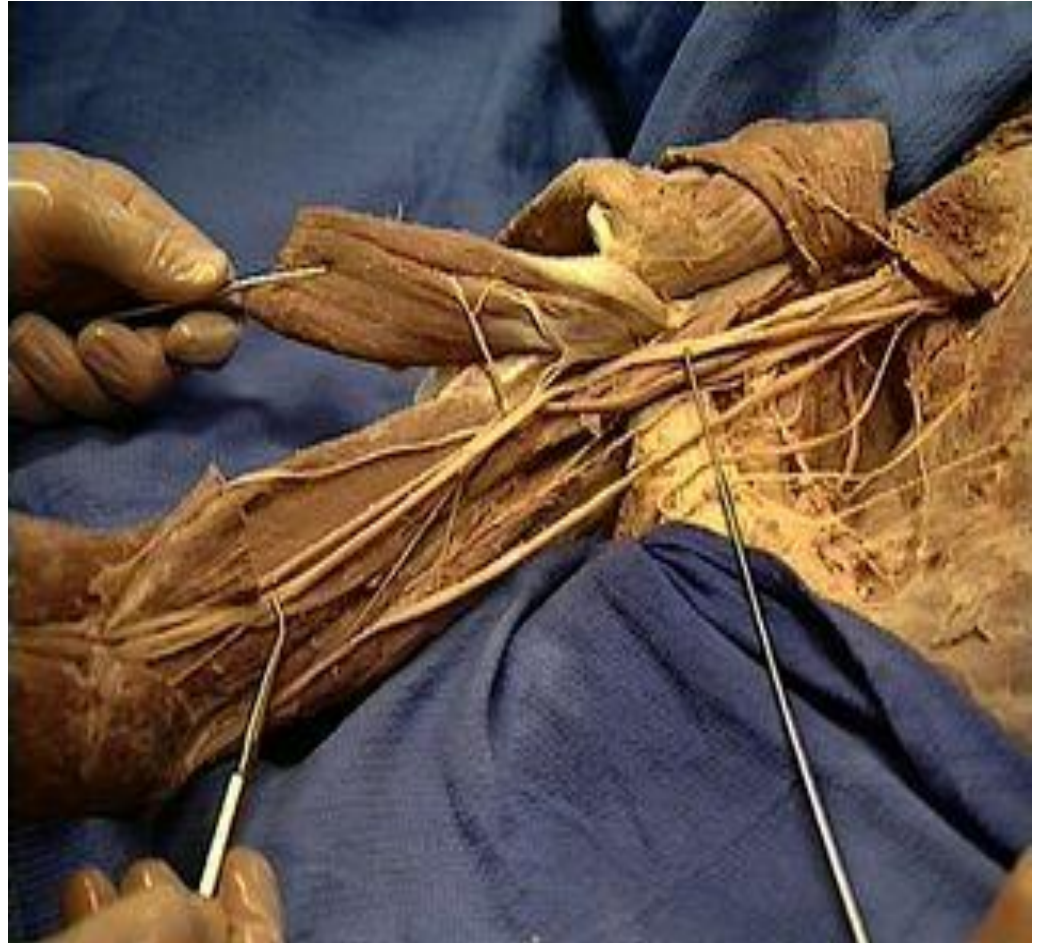

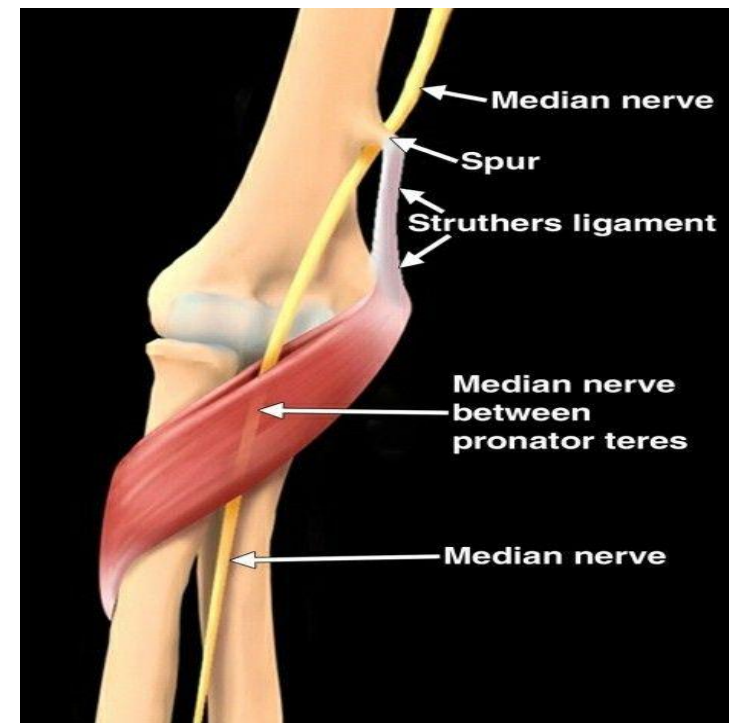
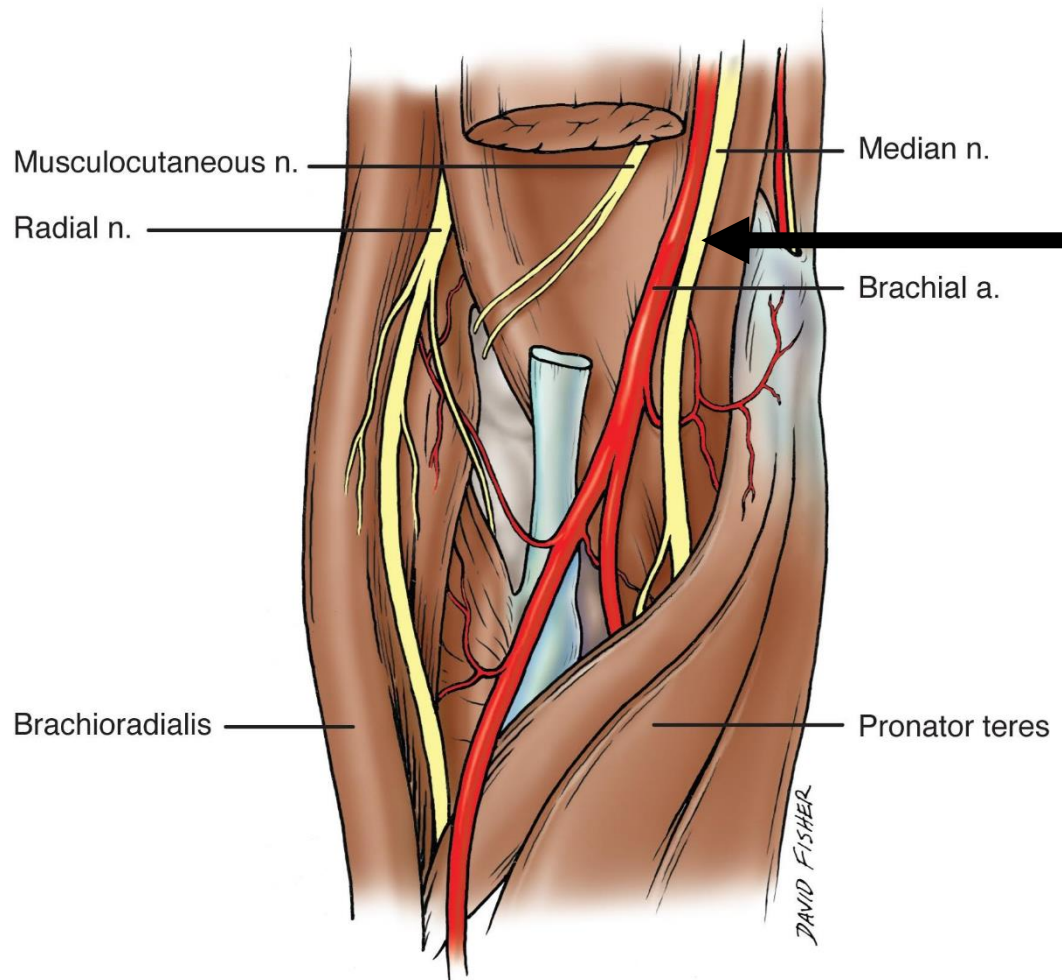


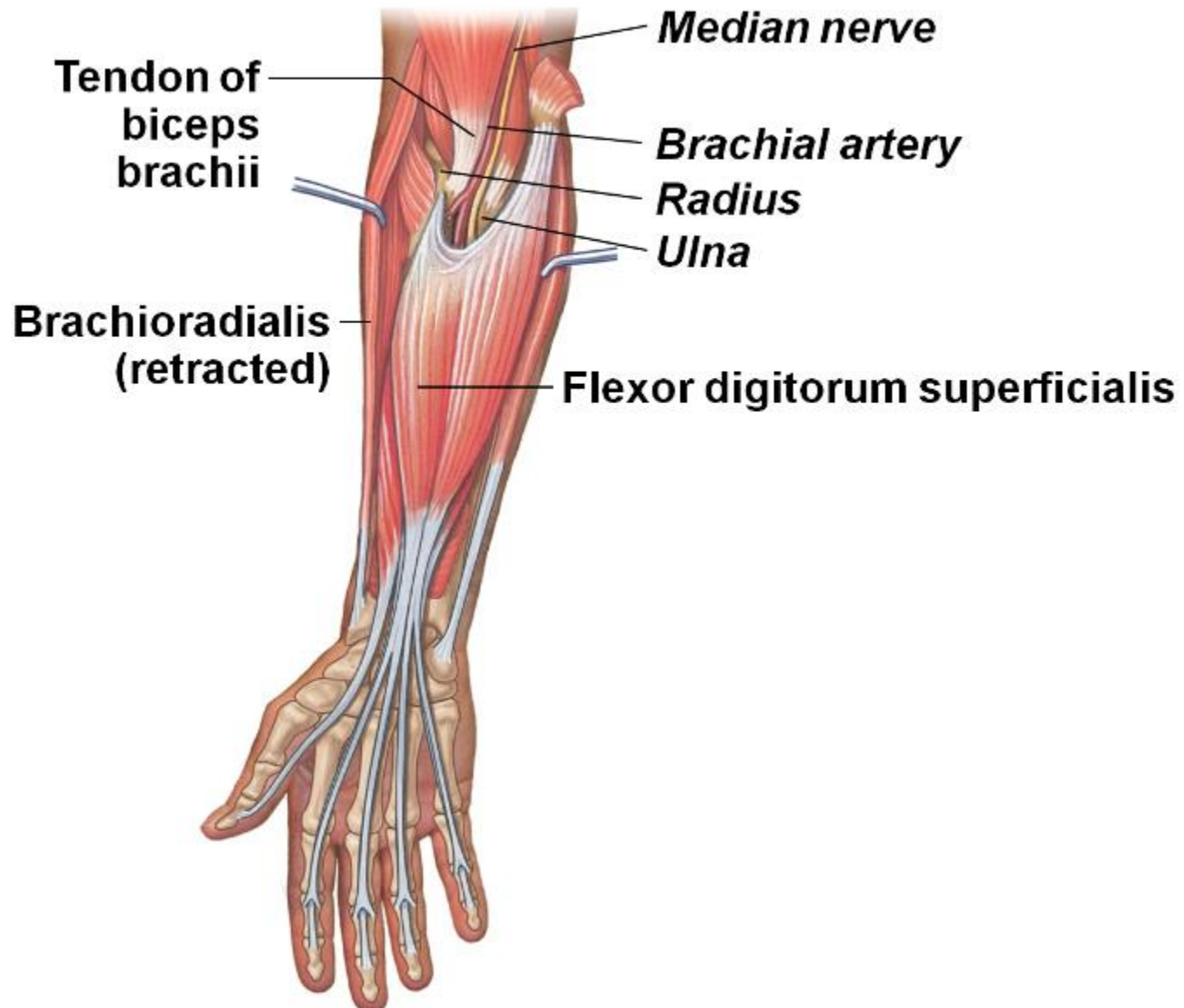
Claw hand deformity (chronic lesion)
- “ulnar paradox” – clawing is more pronounced than with proximal lesion b/c flexor digitorum profundus is intact

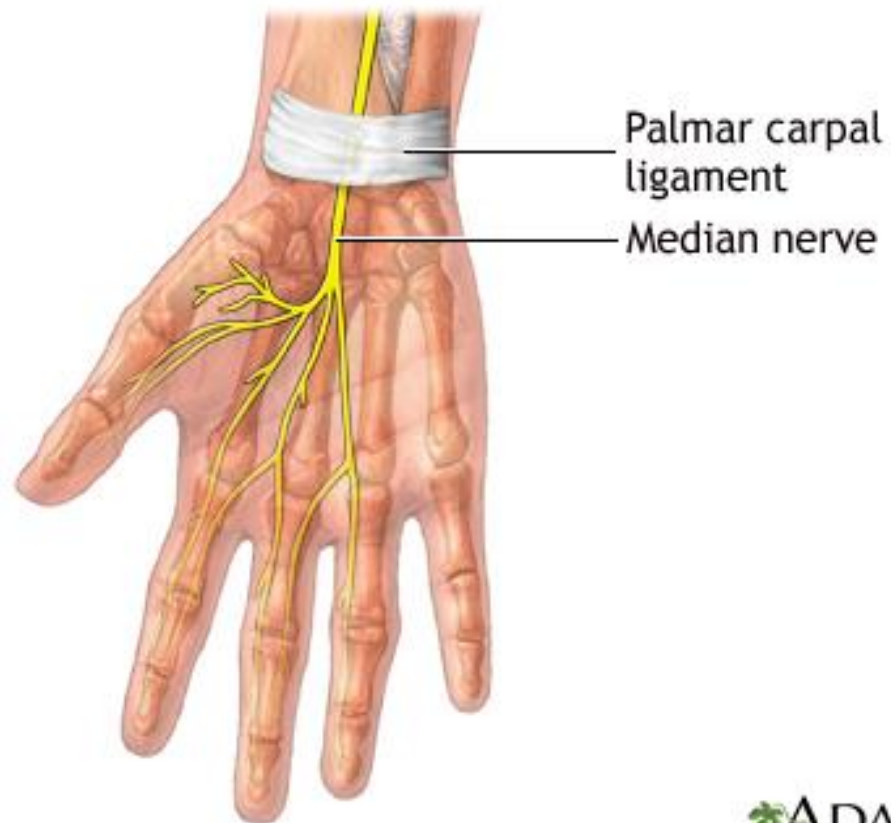


Median Nerve



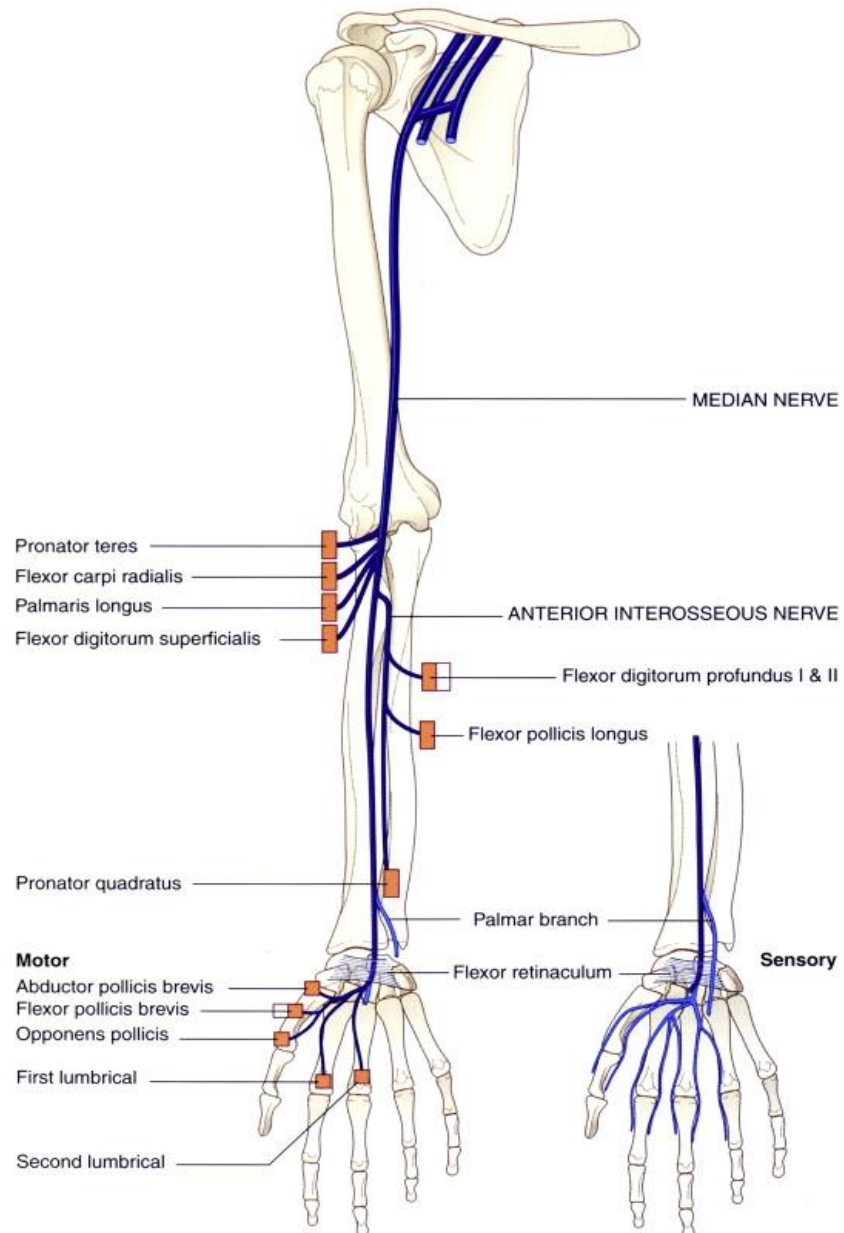






 ADAM.

MEDIAN NERVE



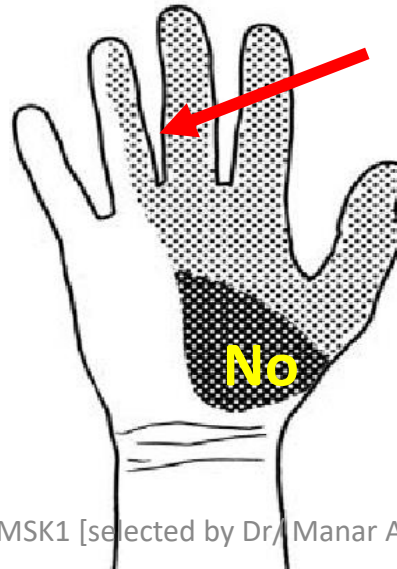
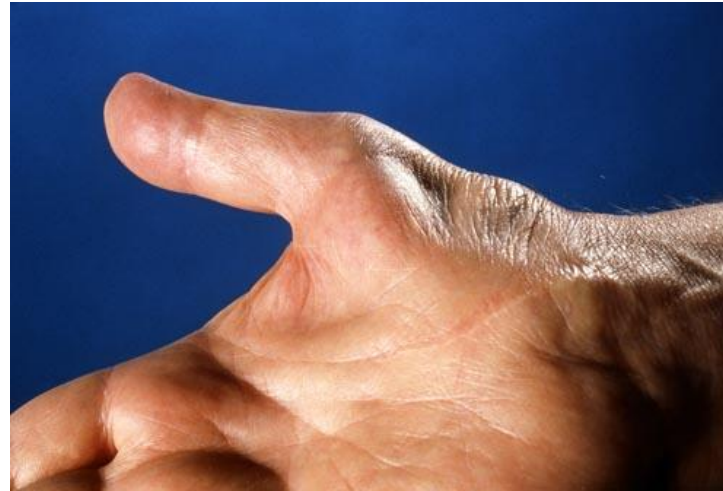Effect of injury

Ape hand deformity

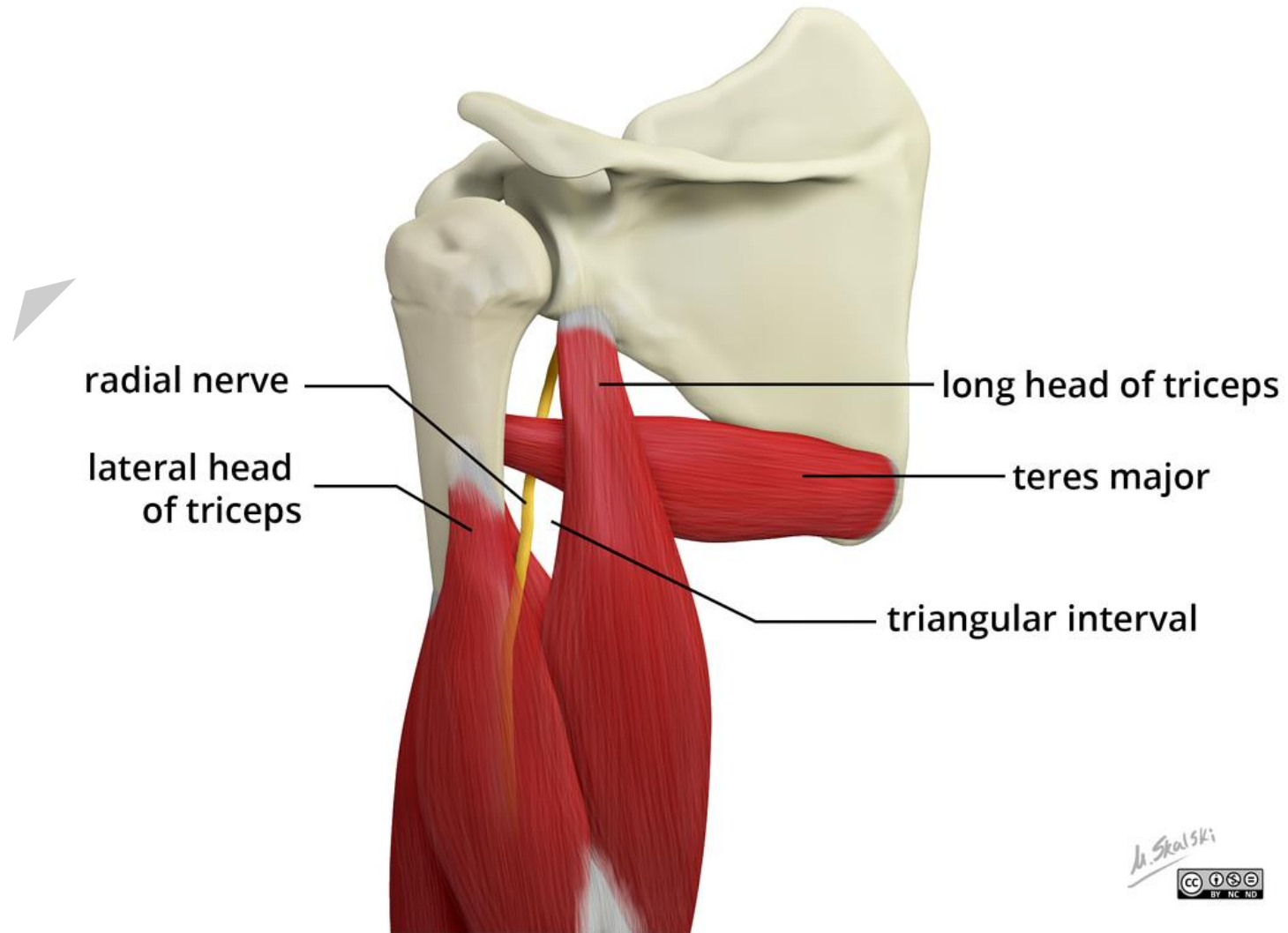


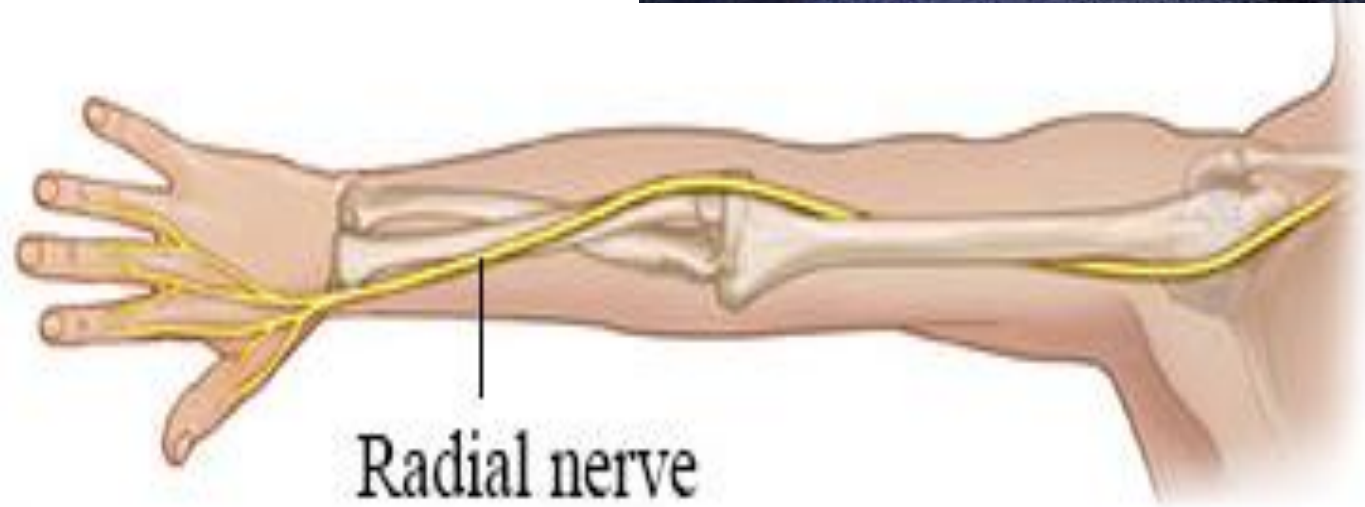
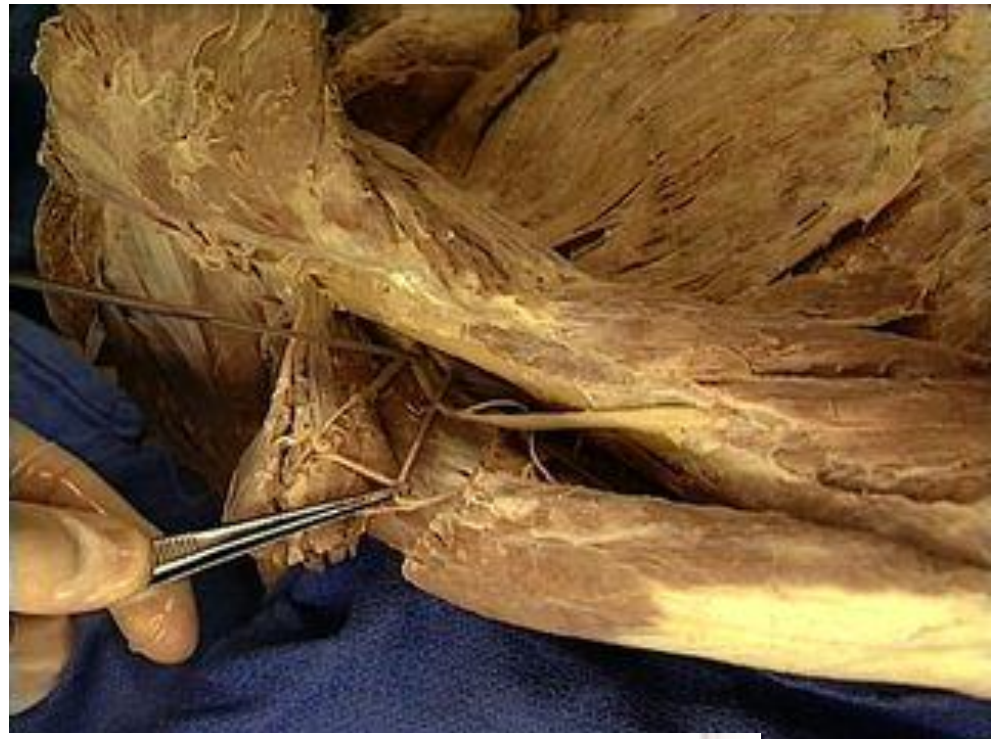Cannot abduct thumb

Thenar wasting and loss of innervation

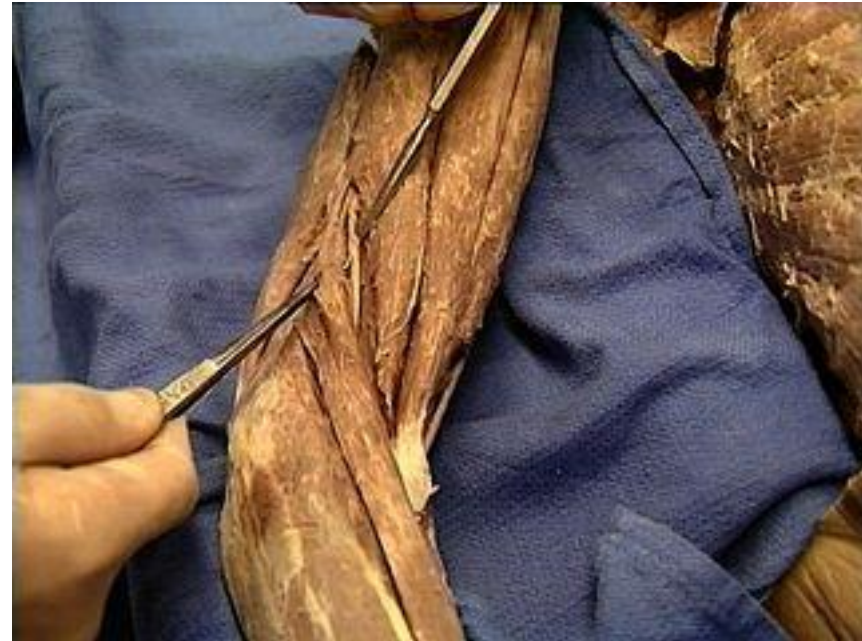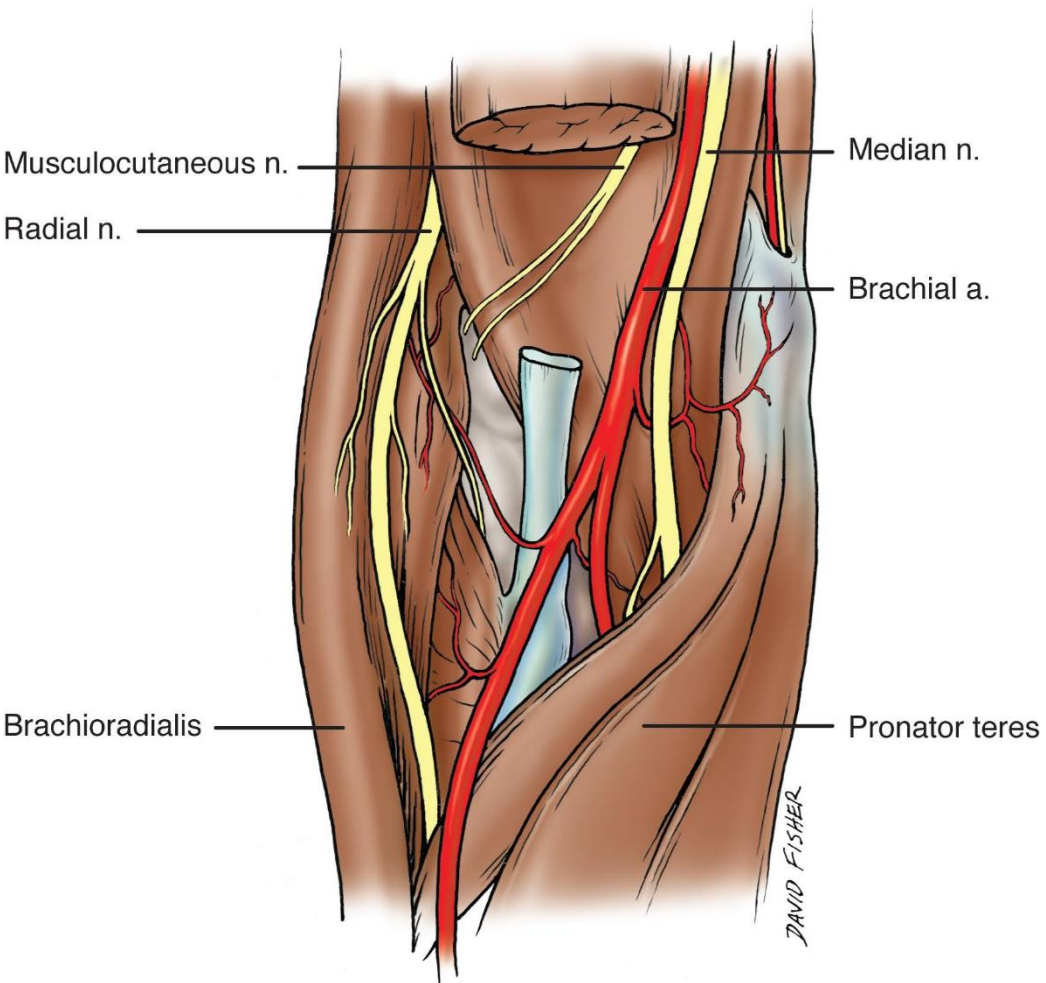


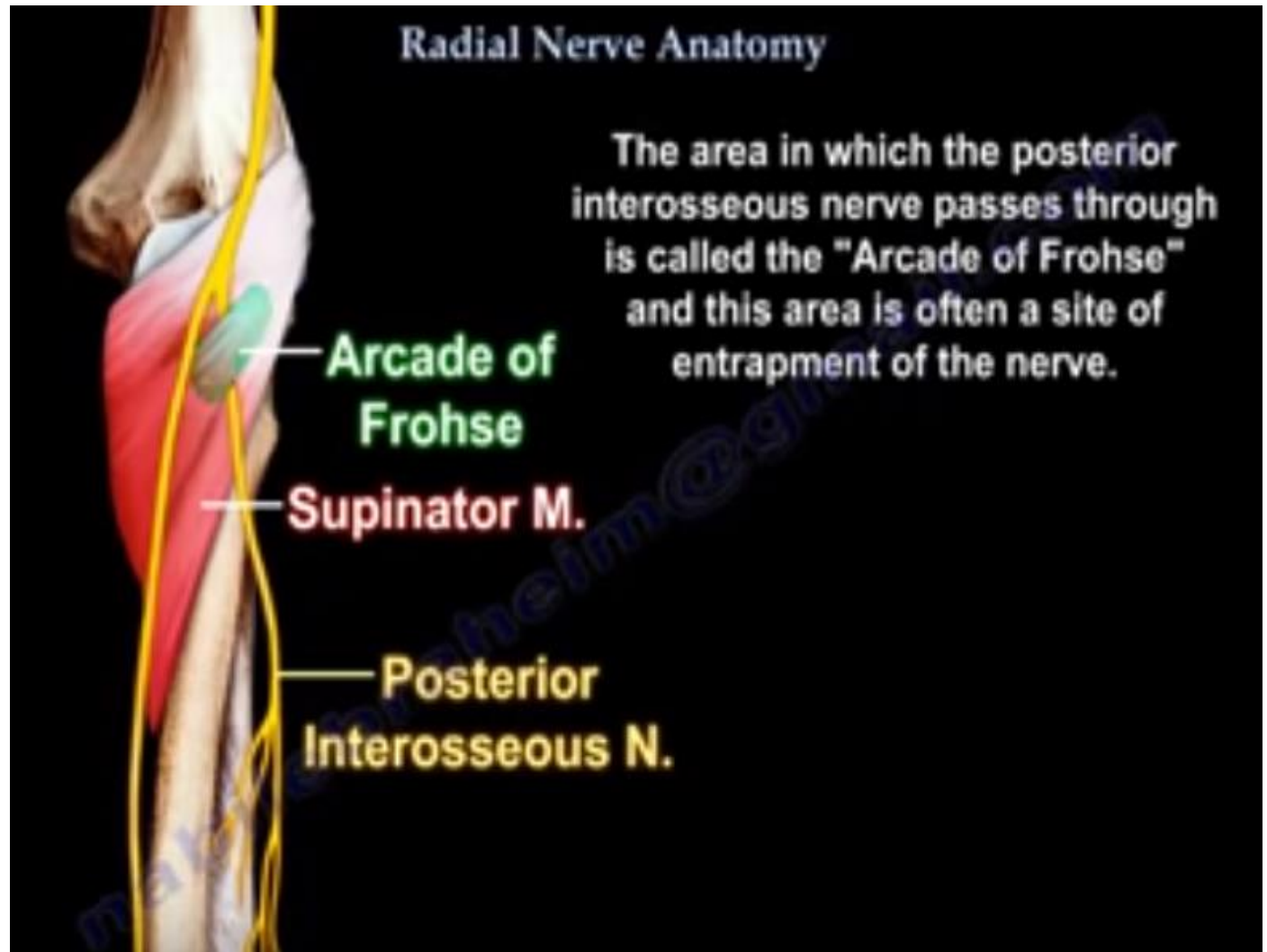Radial Nerve

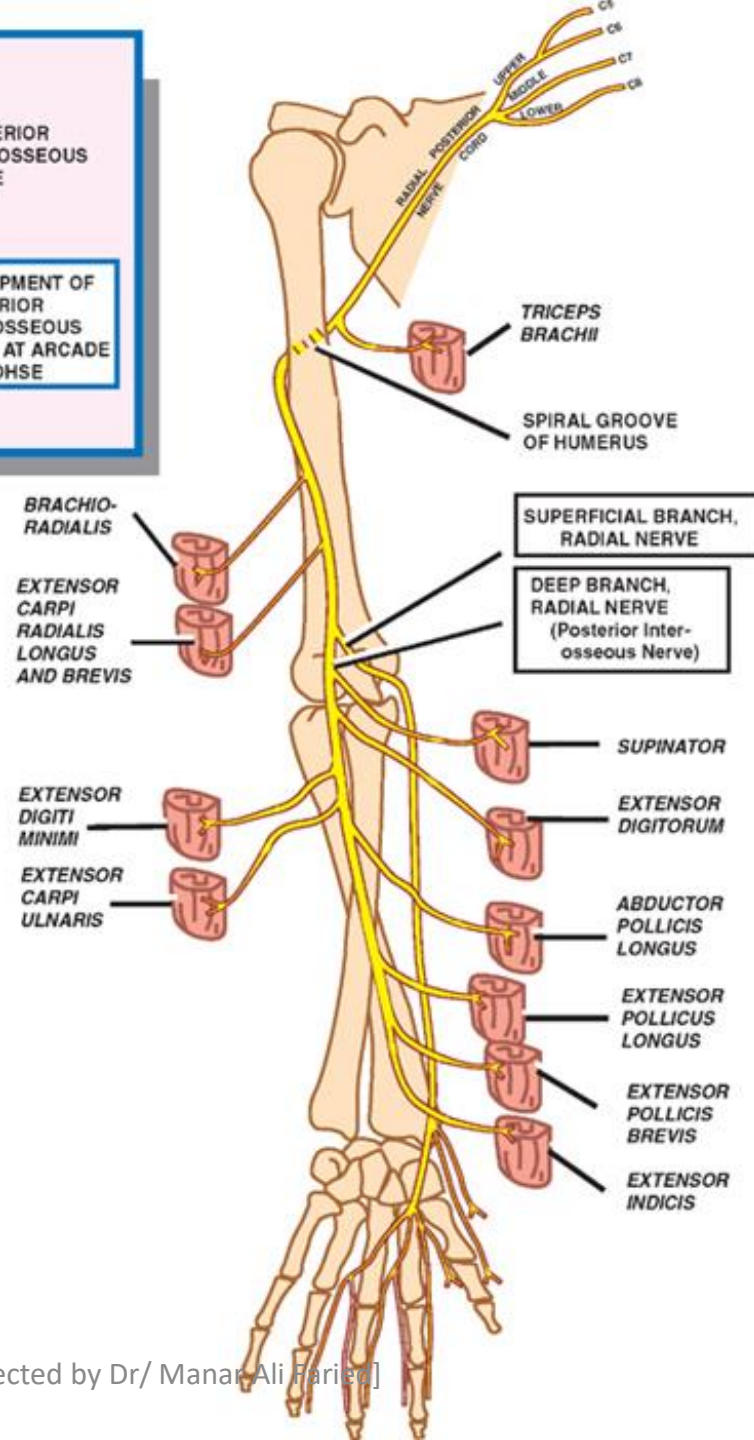
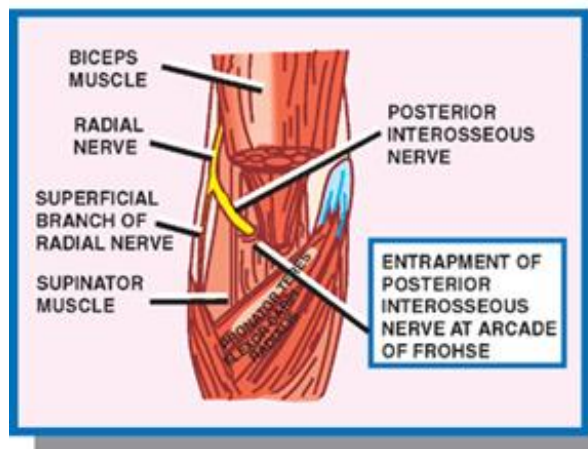




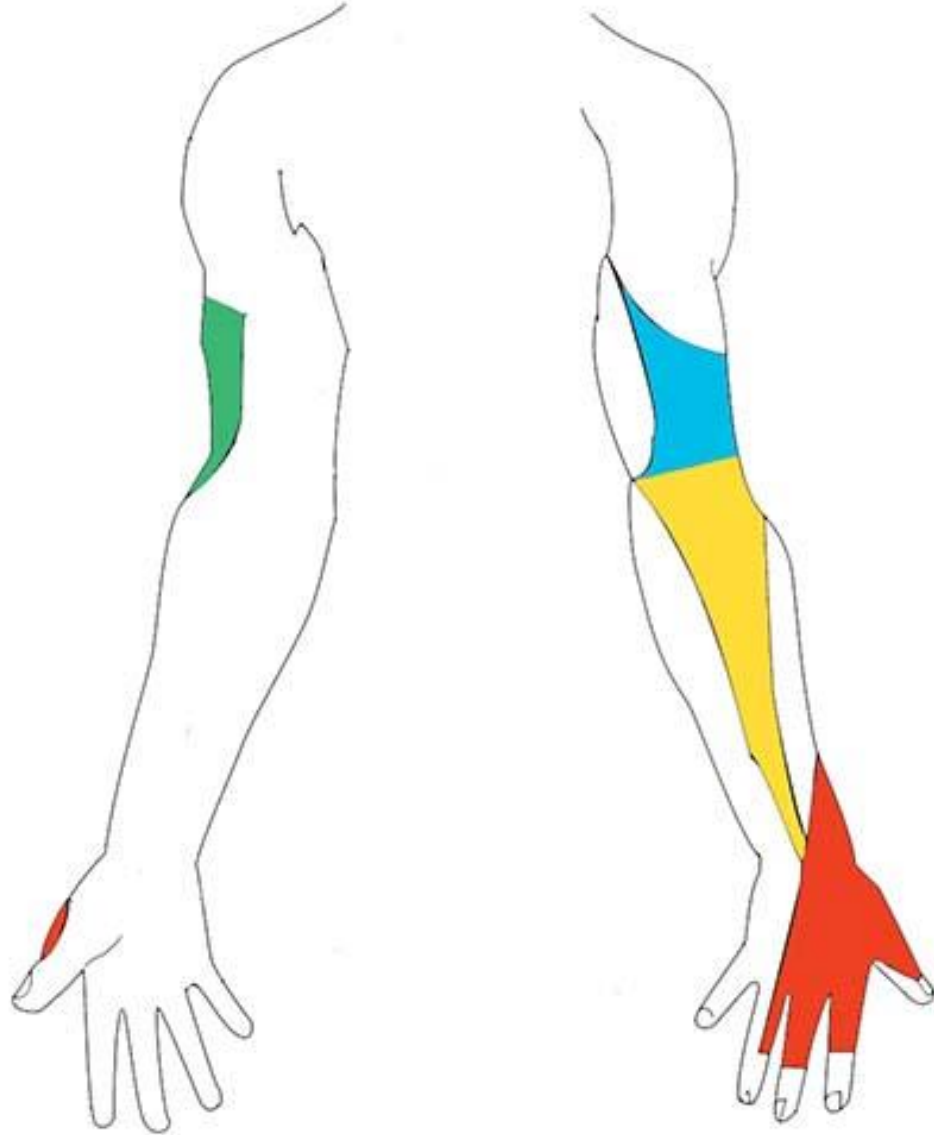
Radial nerve



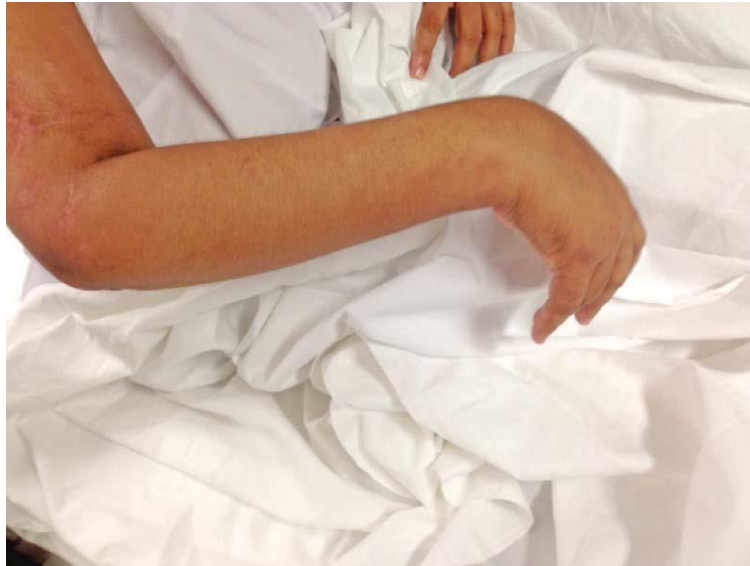



Sensory

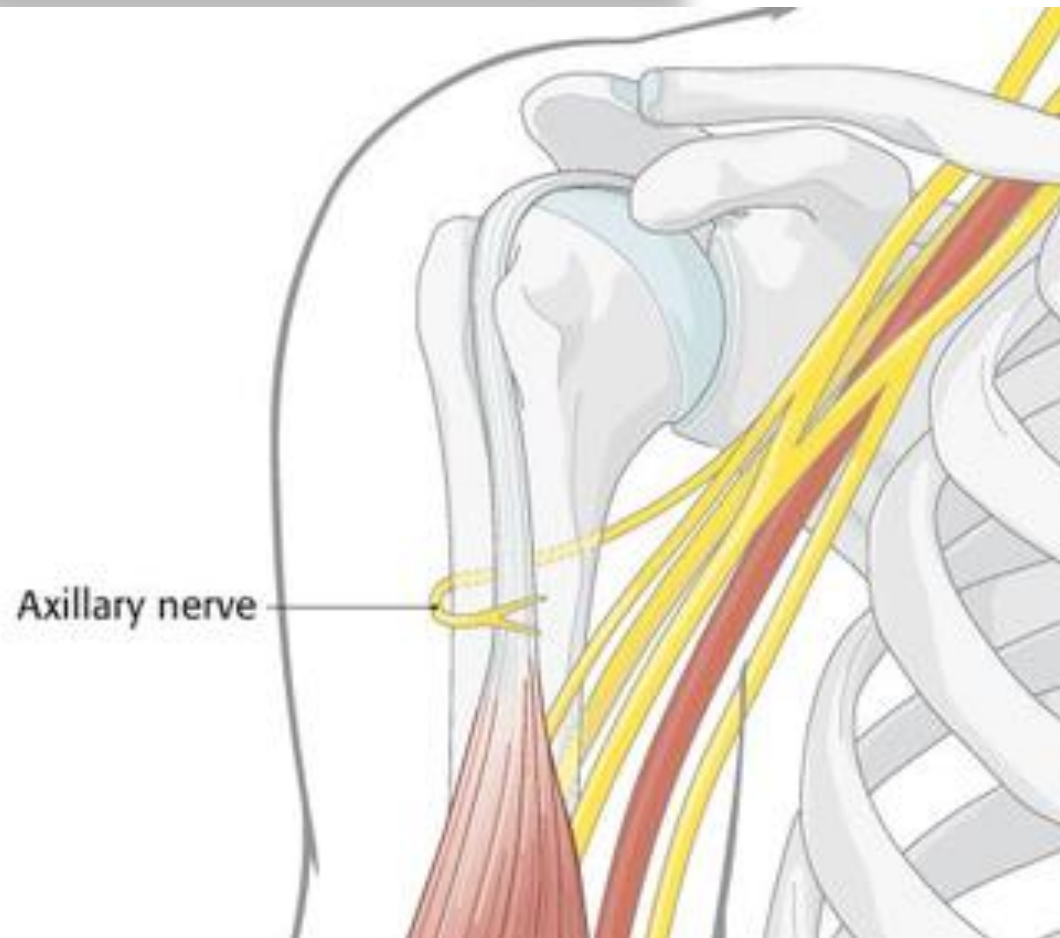


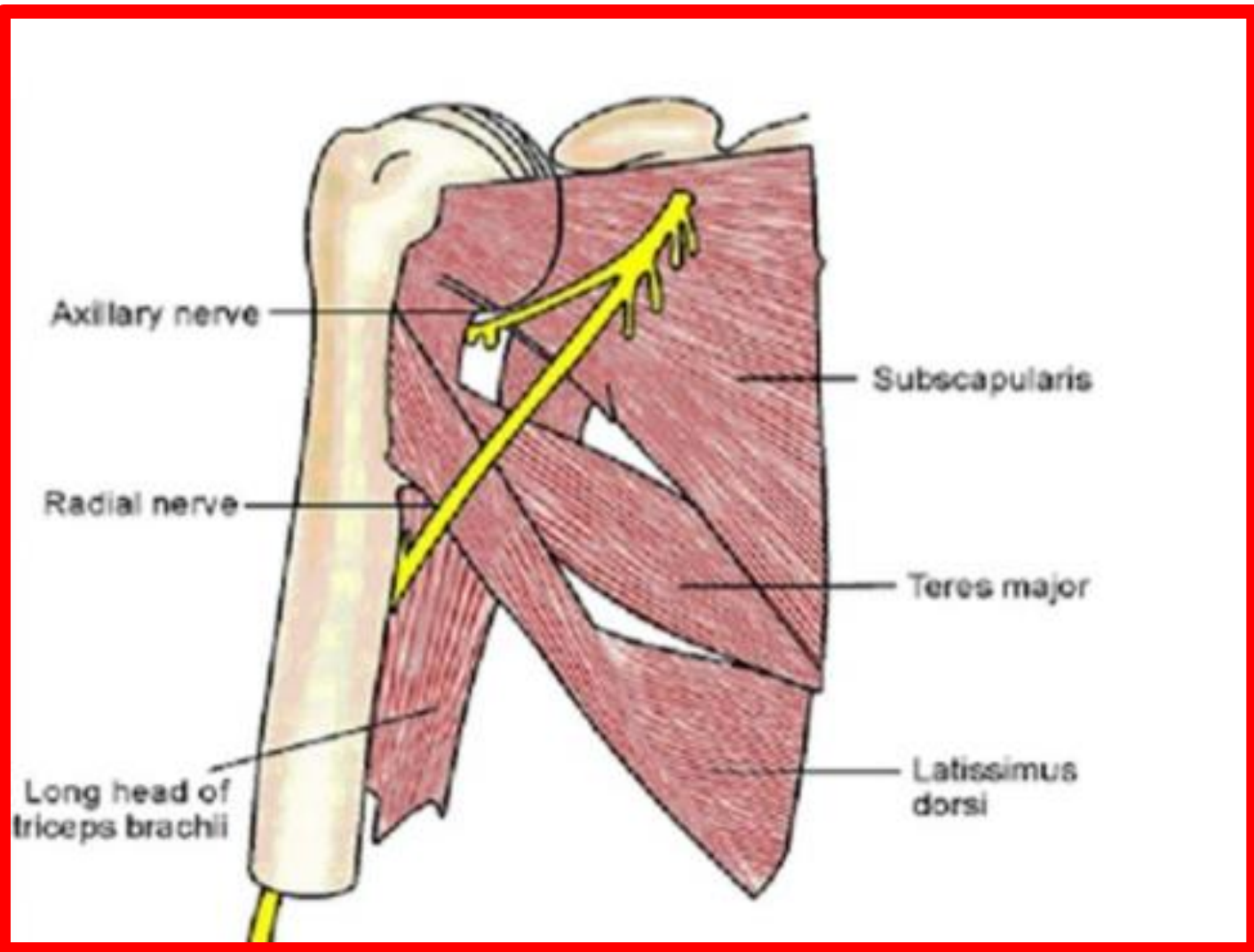
Effect of injury

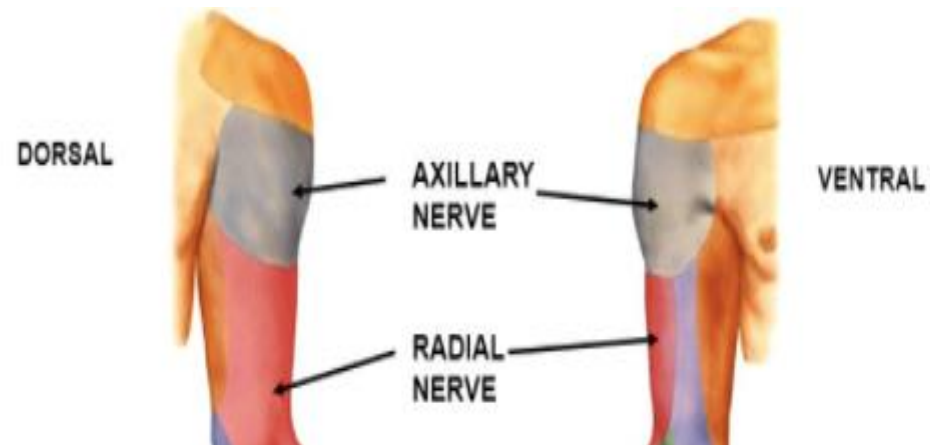
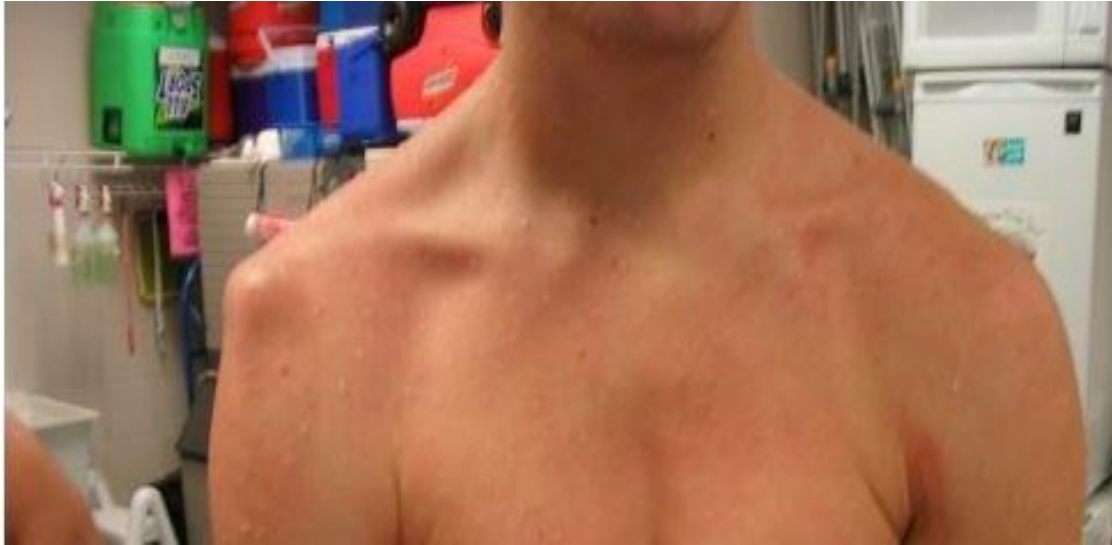

LECTURE [10]

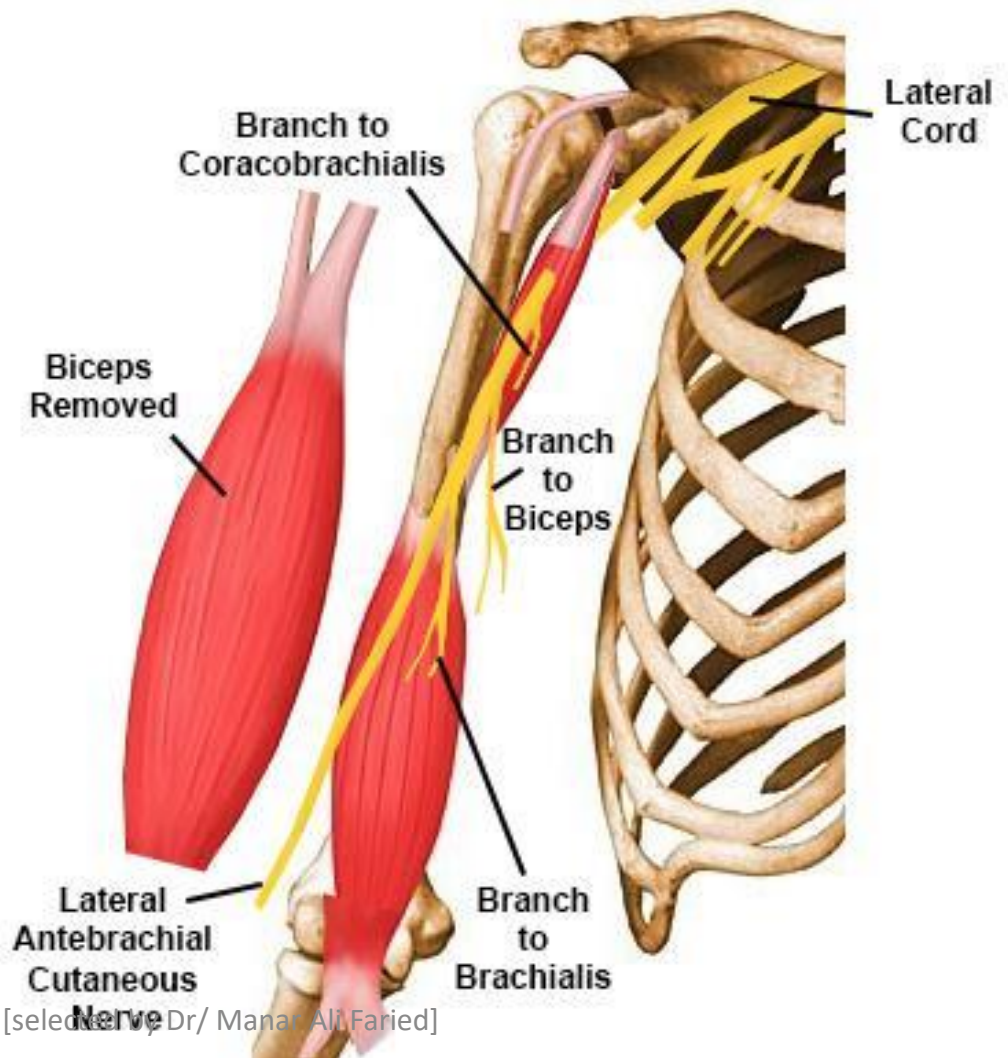
Axillary nerve

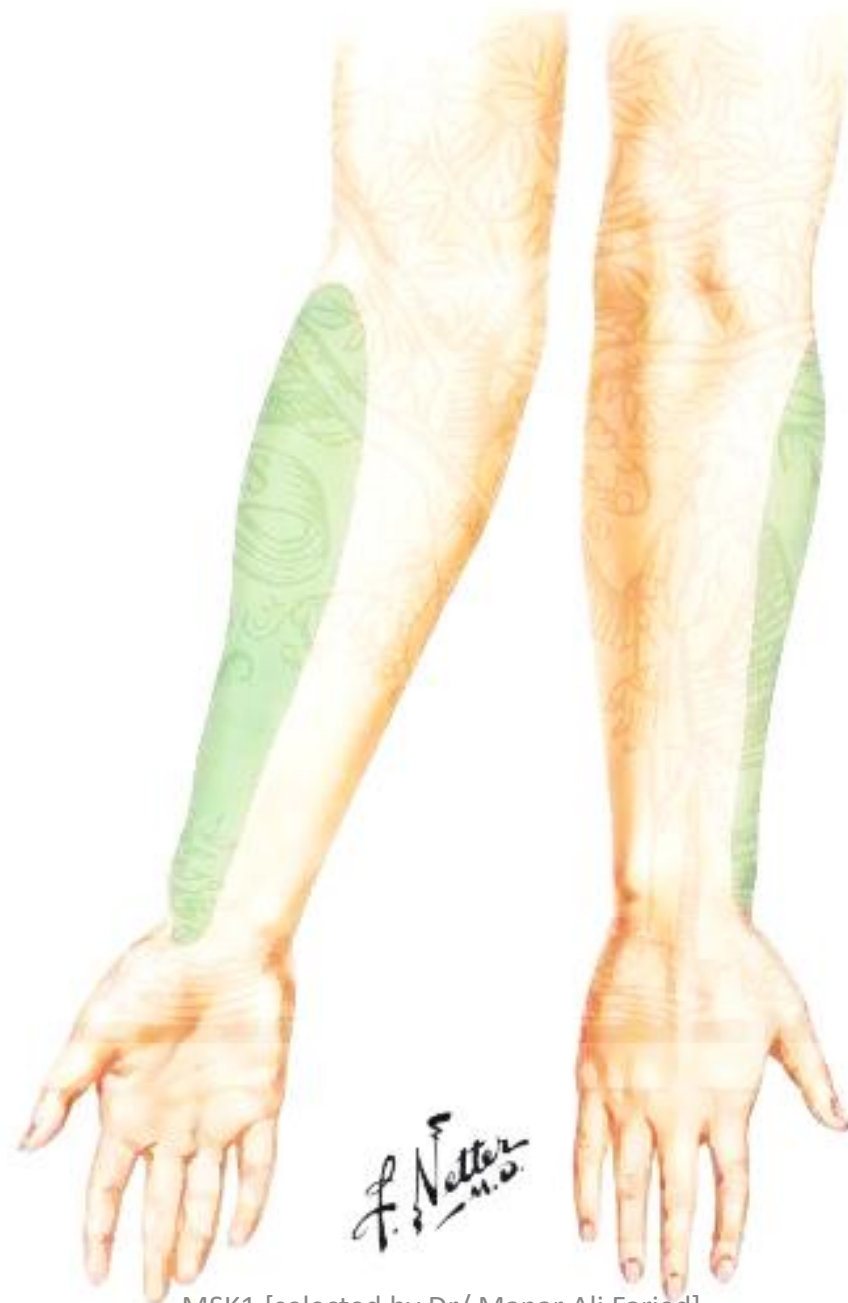





Musculocutaneous N





MSK1 [selected by Dr/ Manar Ali Faried]

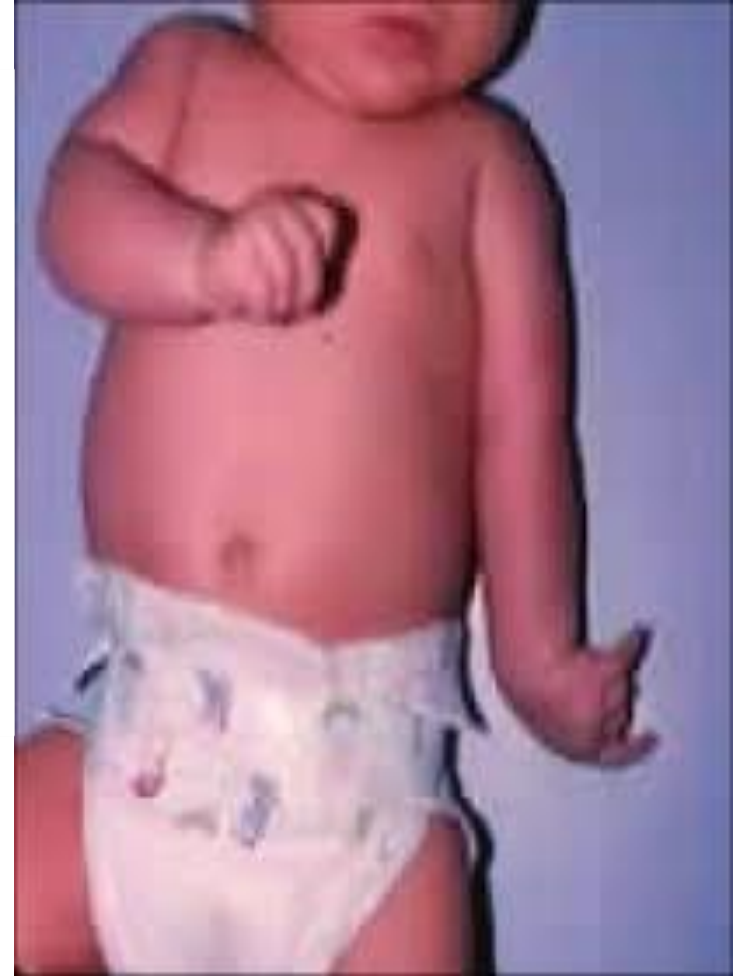© ELSEVIER, INC. - NETTERIMAGES.COM

Upper Trunk Injury

Arm: adducted
Medially rotated

Forearm:
extended
Pronated

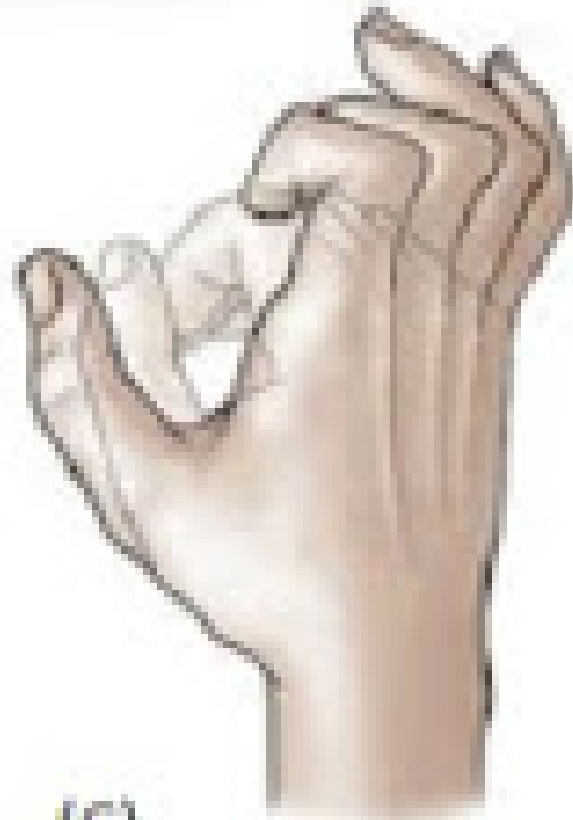**Wrist and
fingers:**
flexed



Lower Trunk Injury

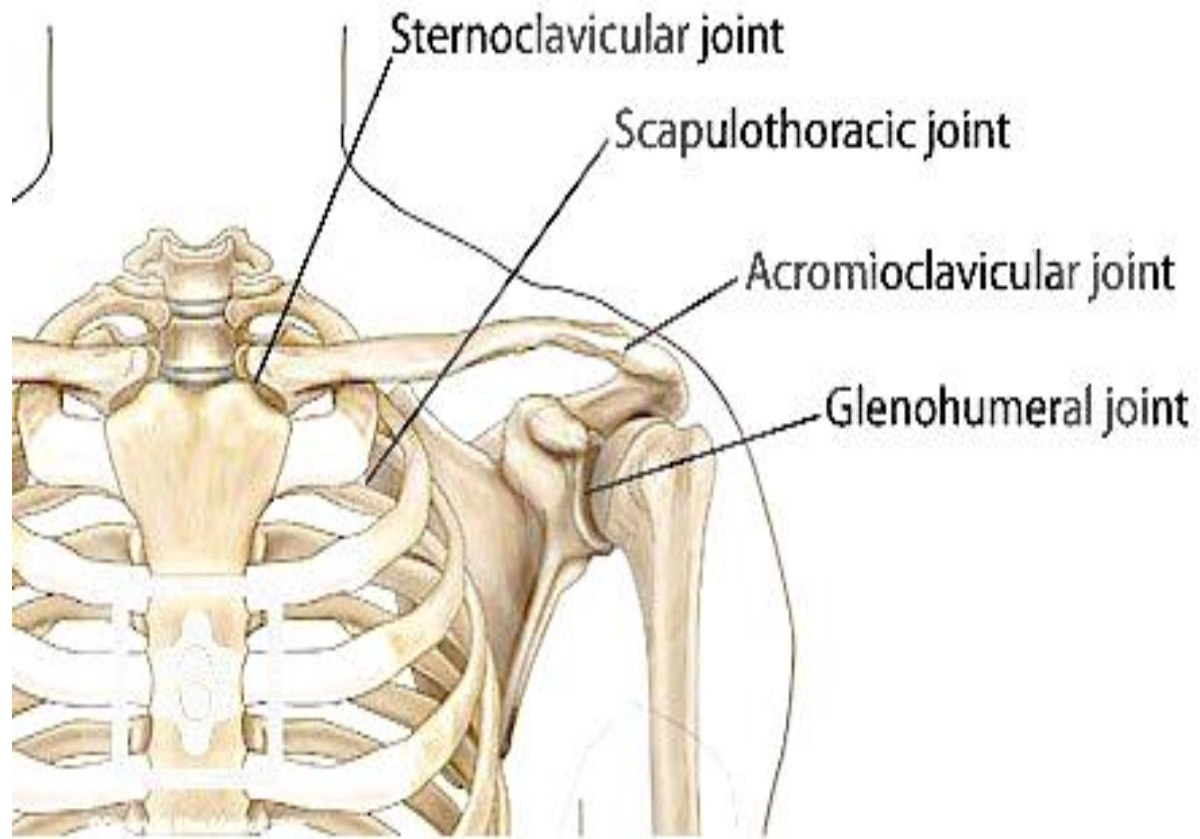
C8,T1

Klumpke's palsy

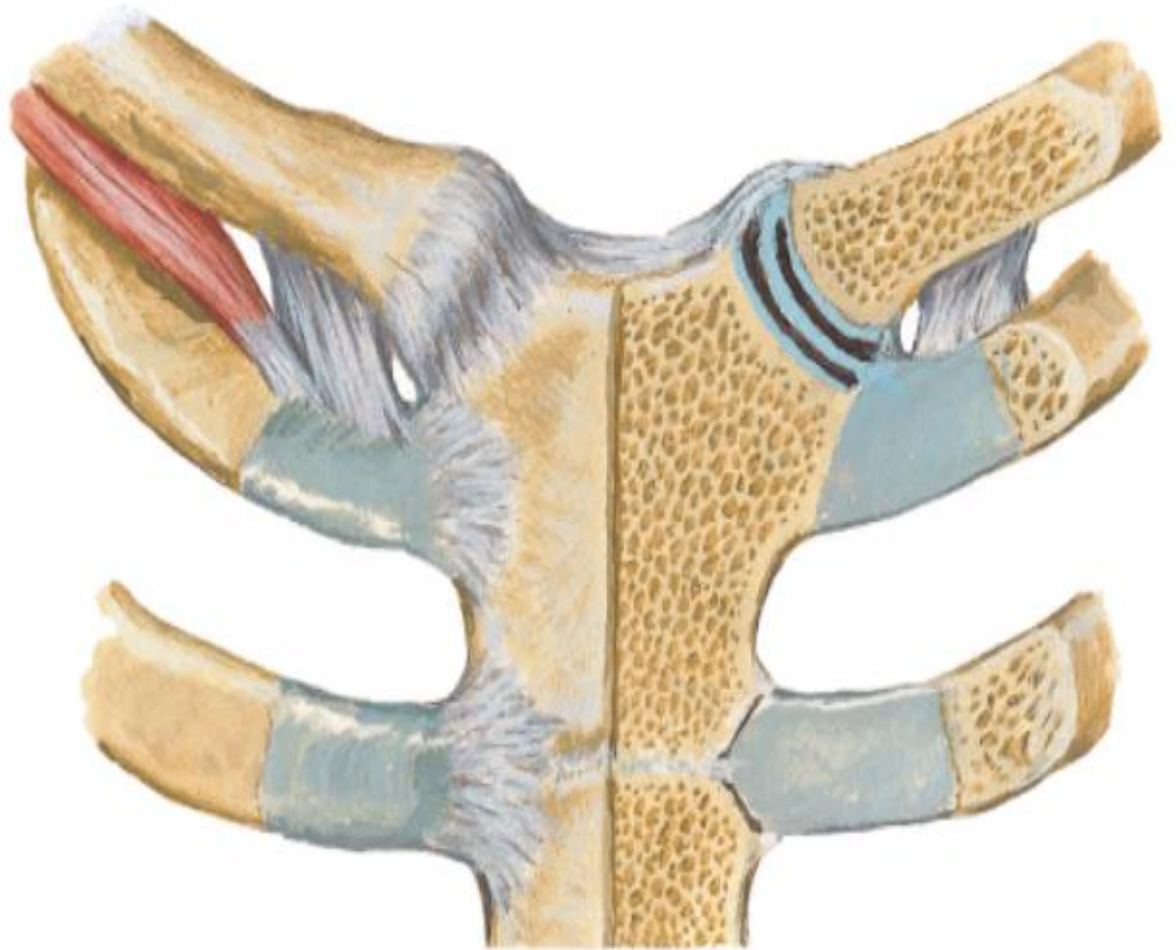


(C)

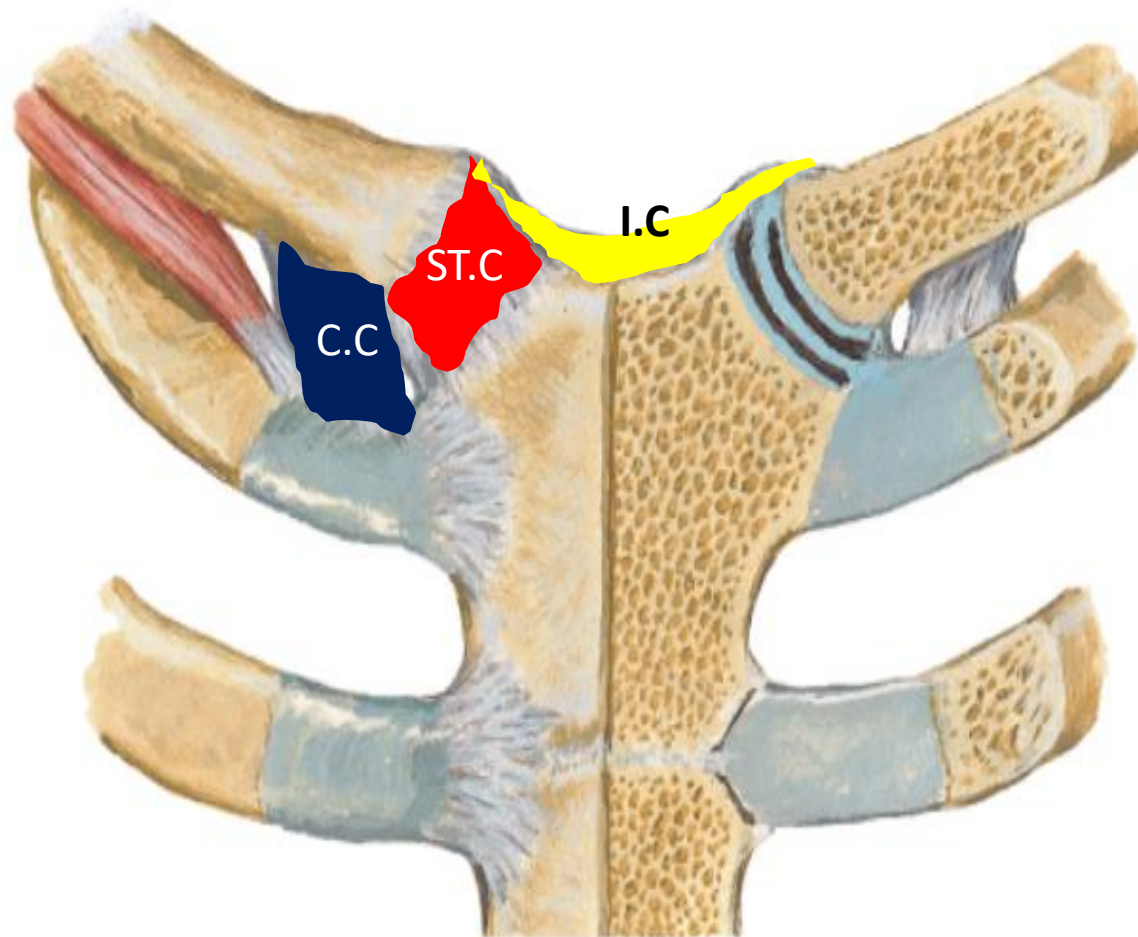
JOINTS



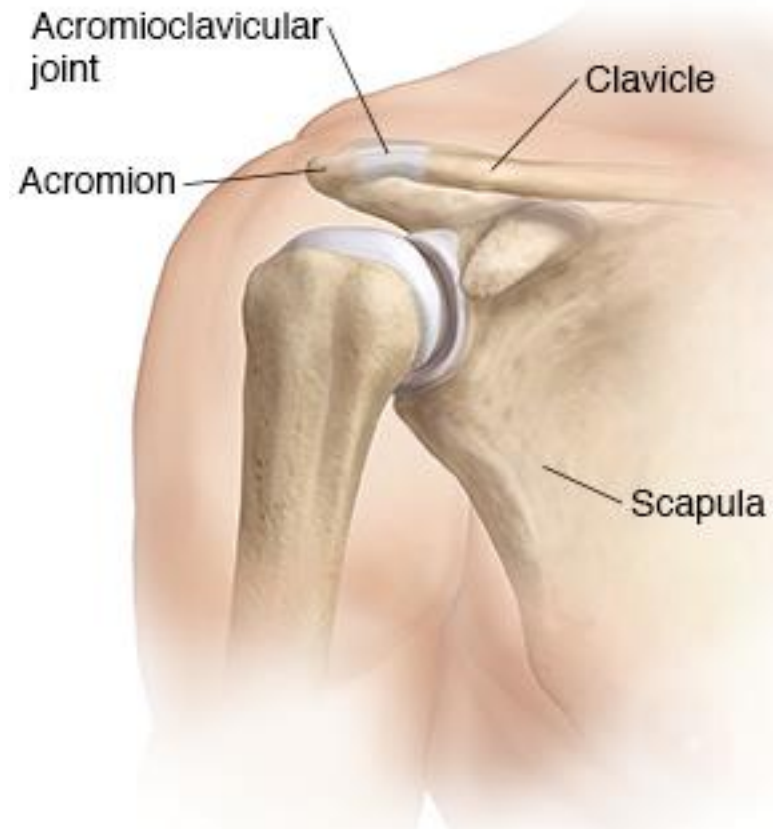
Sternoclavicular



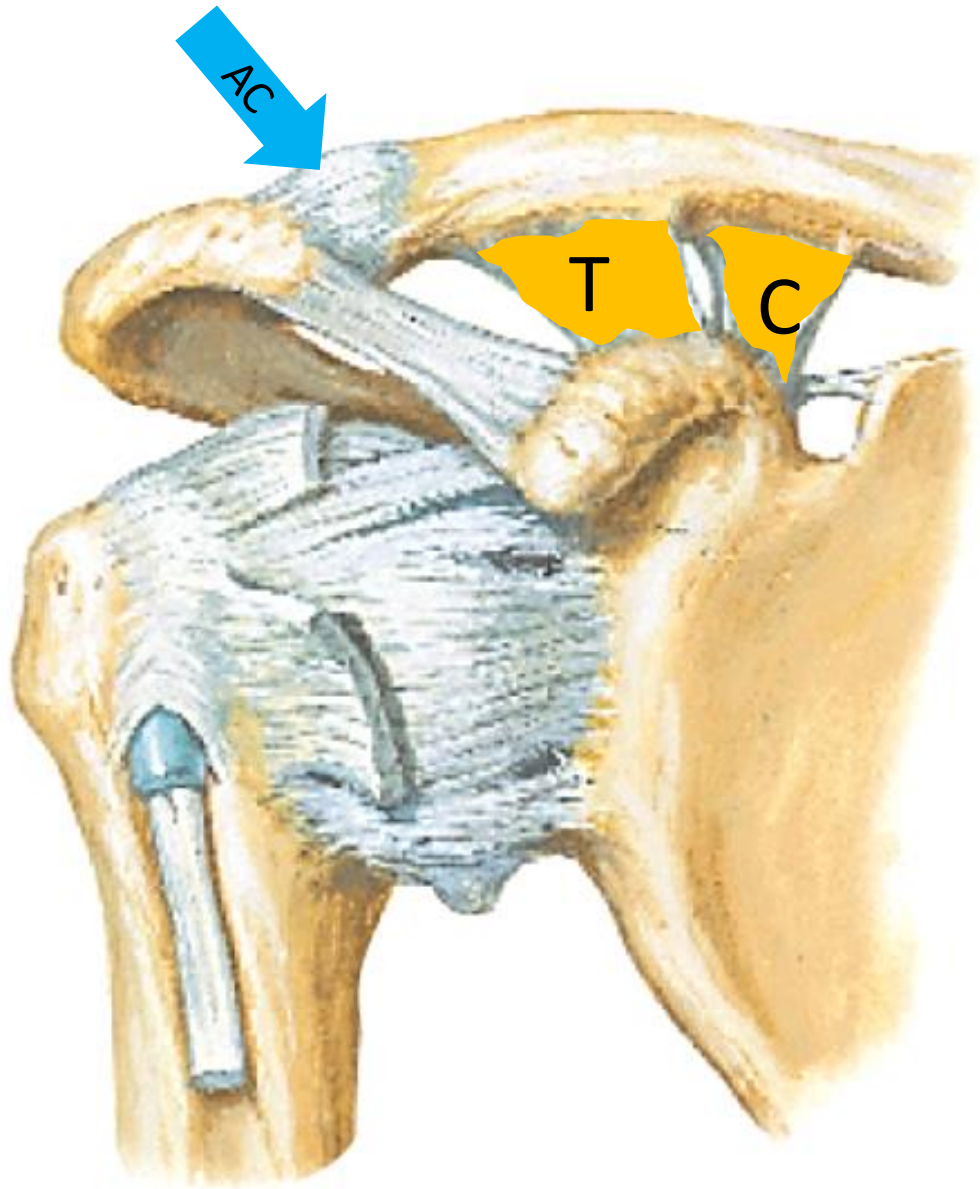
MSK1 [selected by Dr/ Manar Ali Faried]



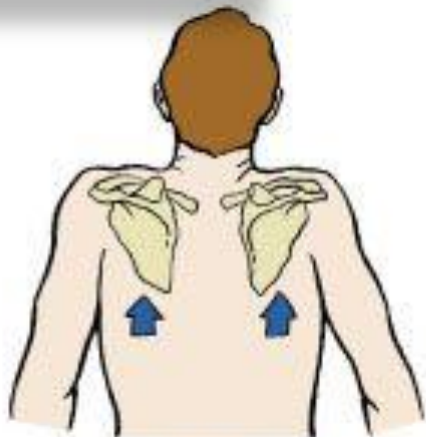Acromioclavicular



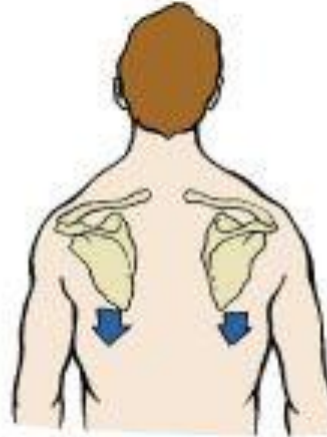
Supporting Ligaments



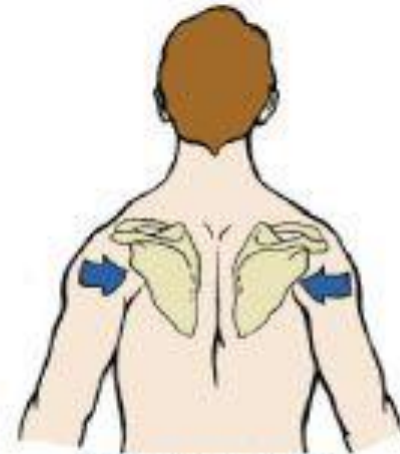Movements



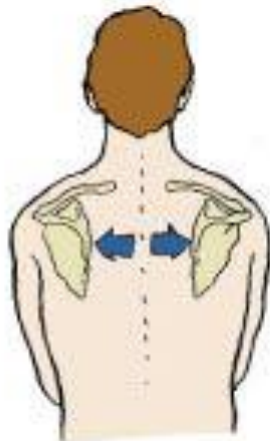Elevation



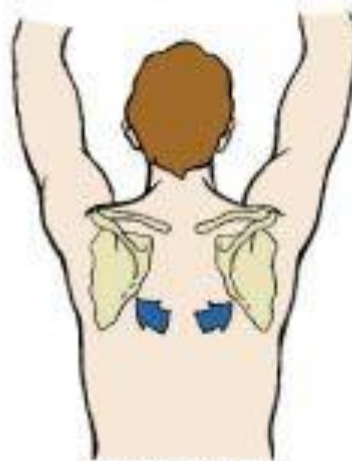Depression



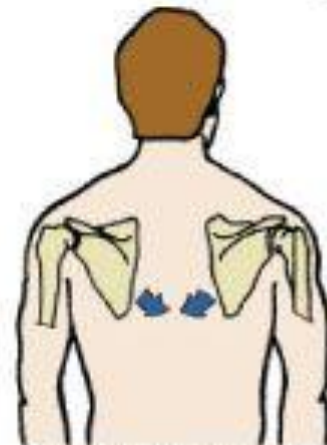
Adduction (retraction)



Abduction (protraction)

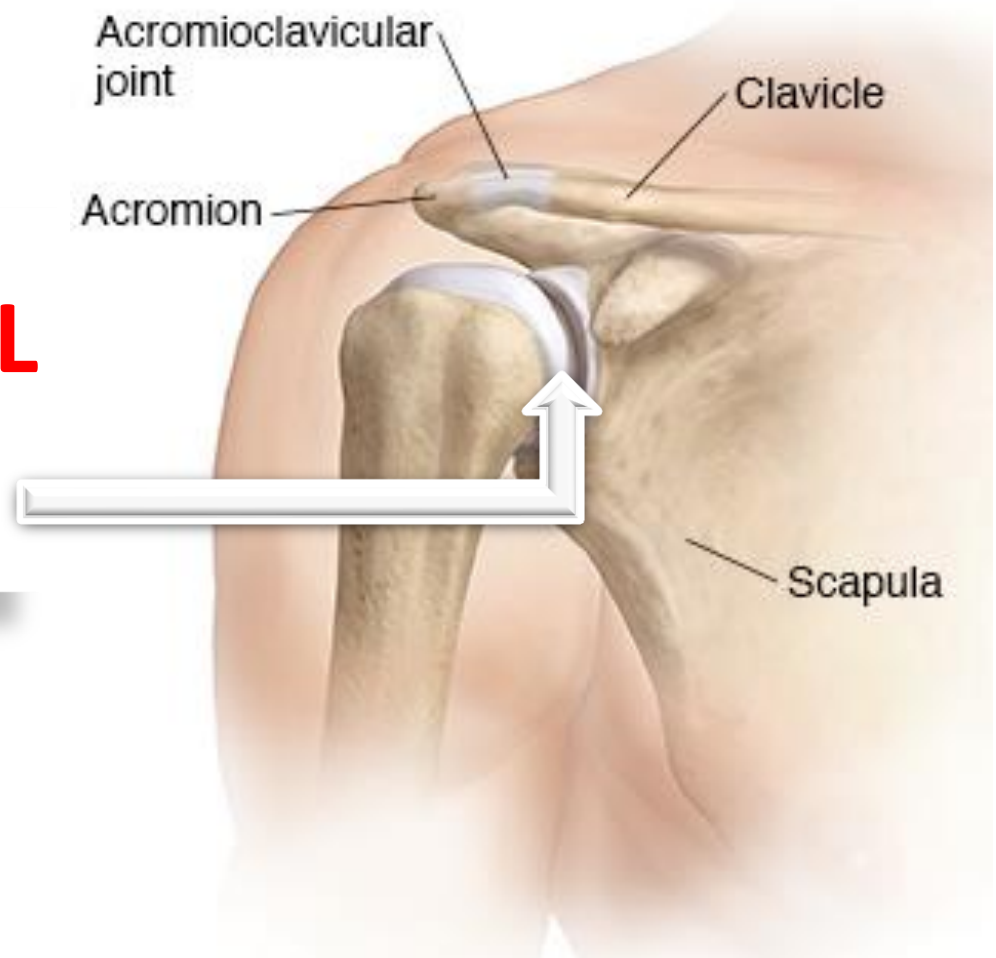


Upward rotation

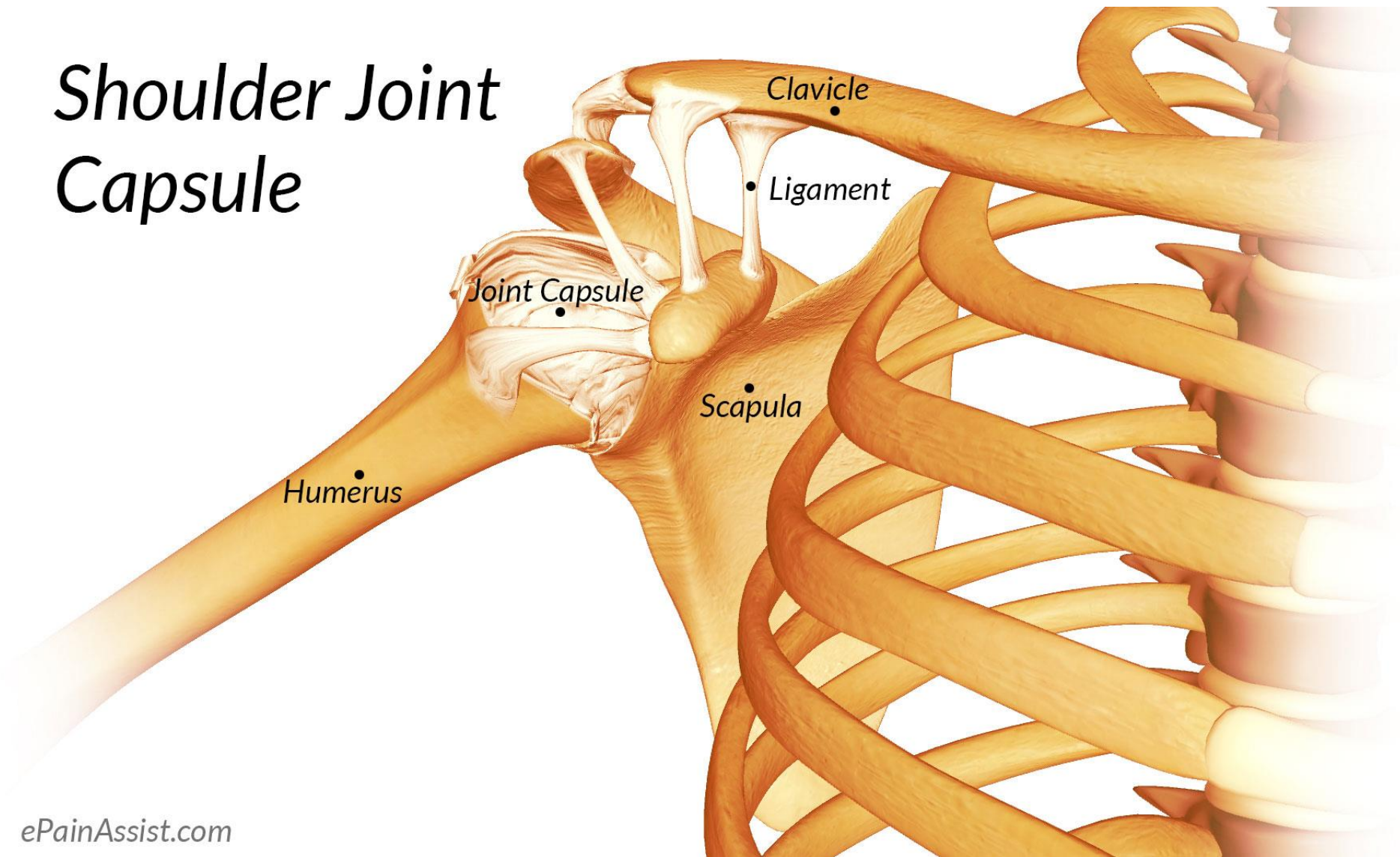


Downward rotation (return to anatomical position)

GLENOHUMERAL JOINT

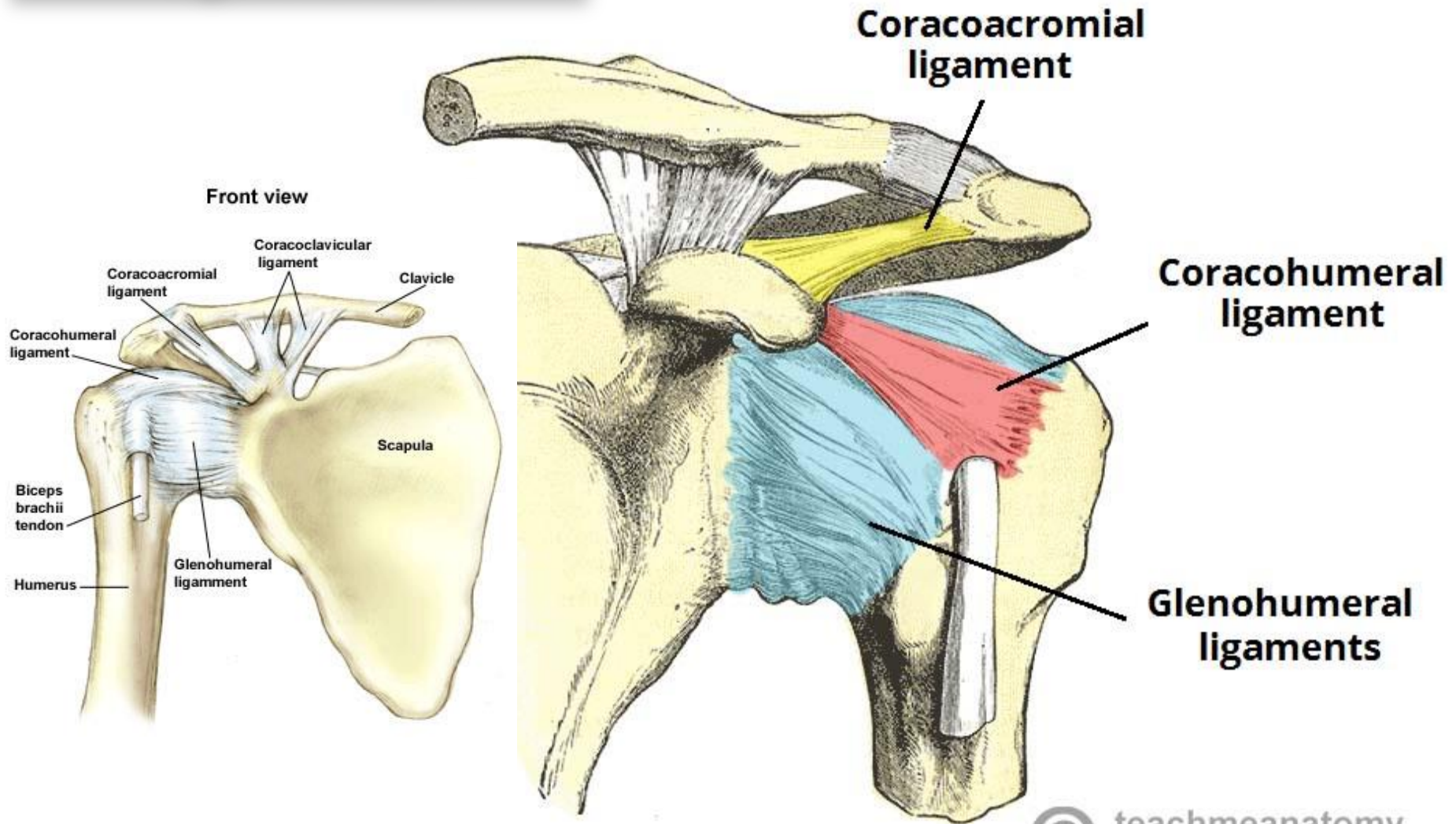


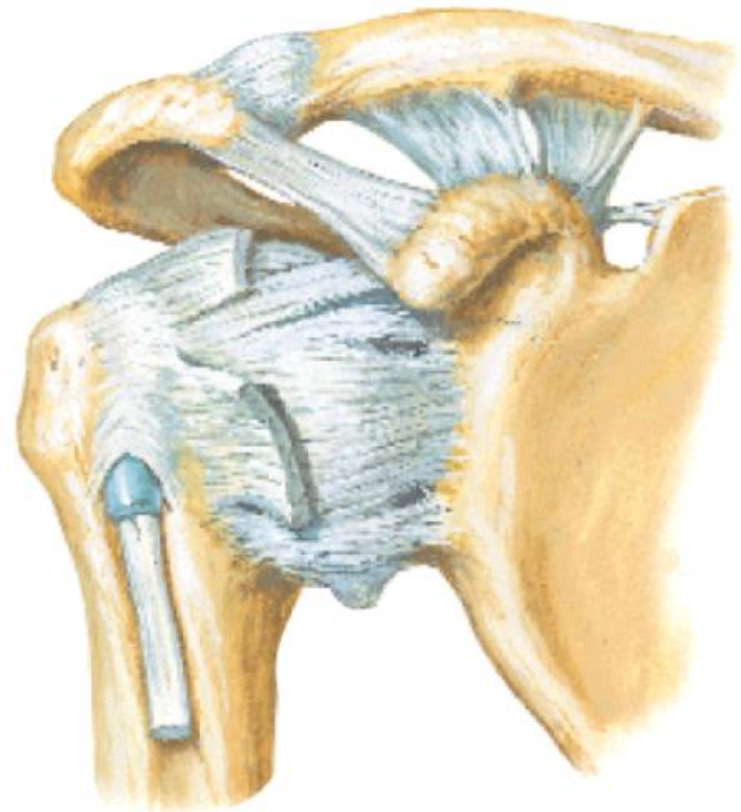
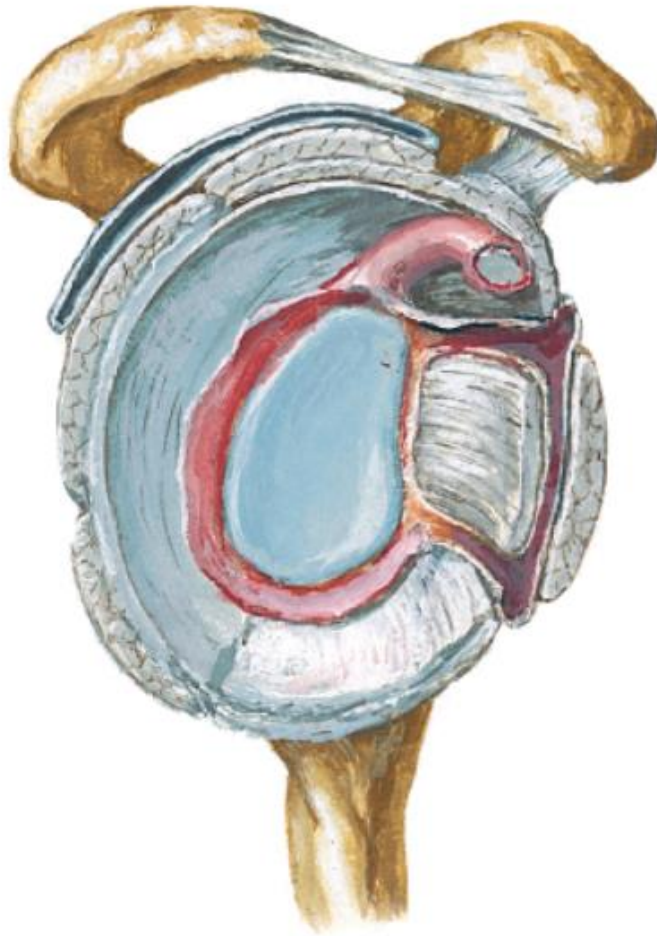
Shoulder Joint Capsule



ePainAssist.com

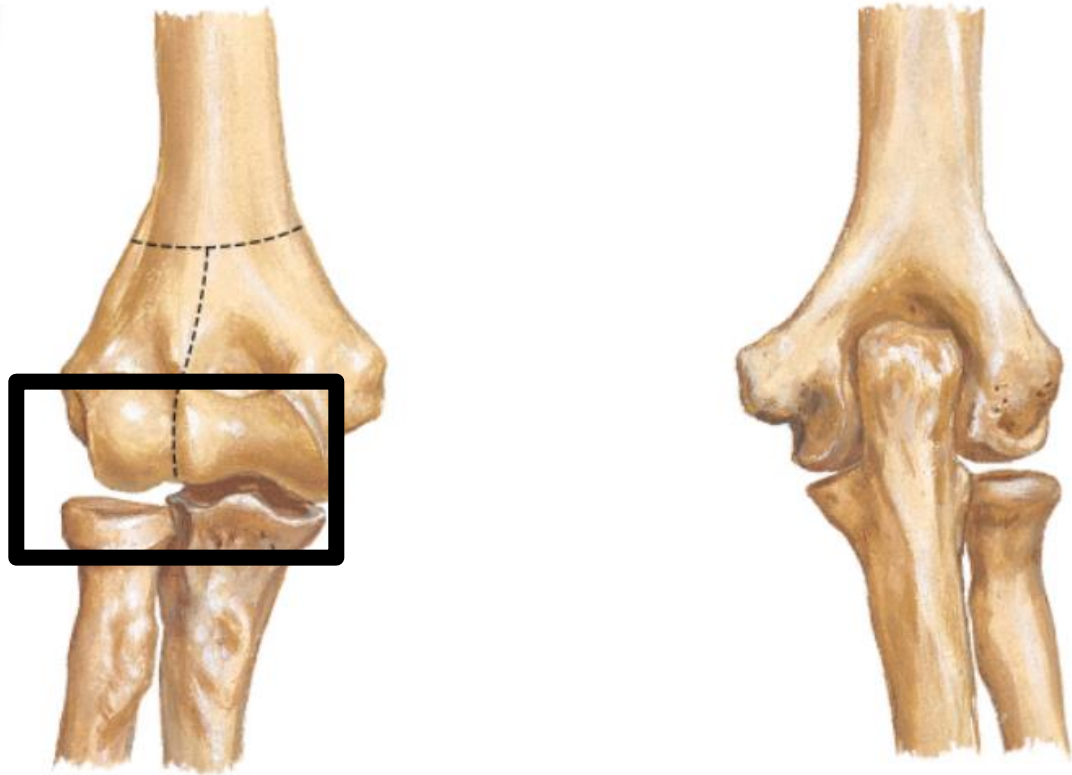
Supporting ligaments

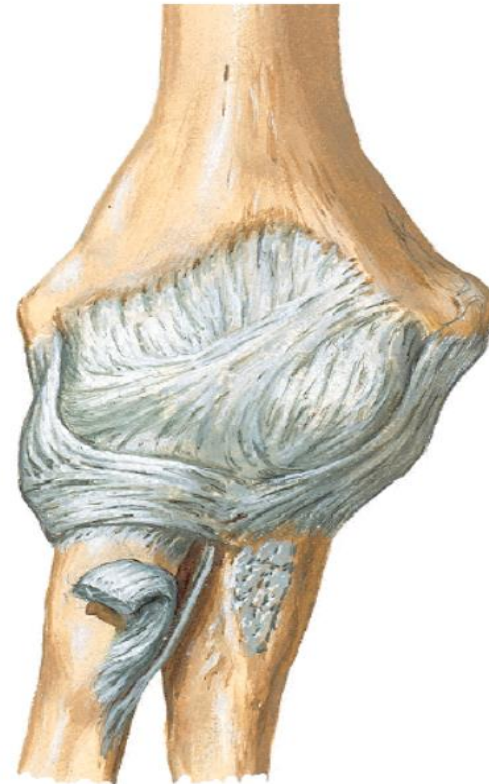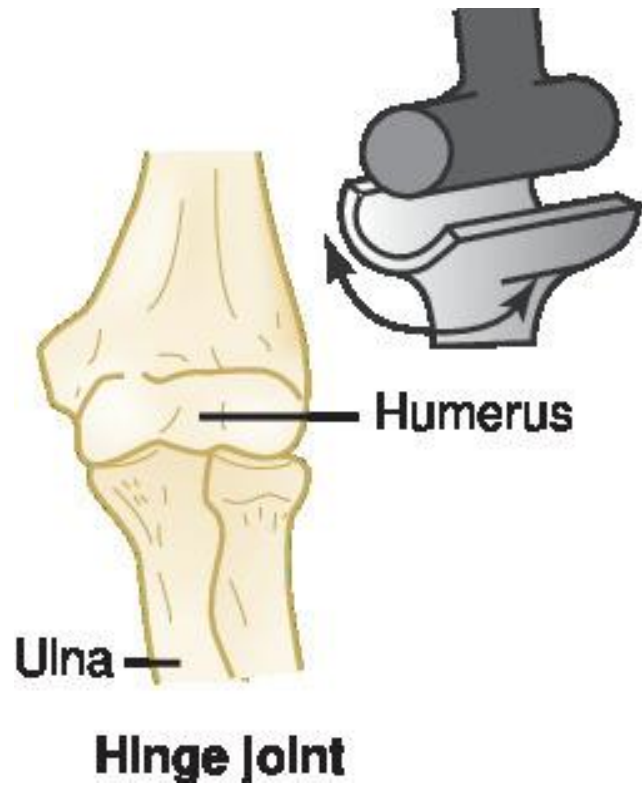



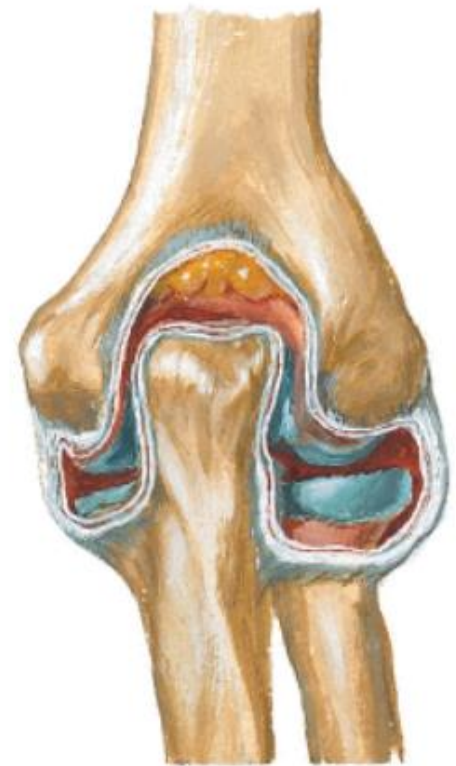
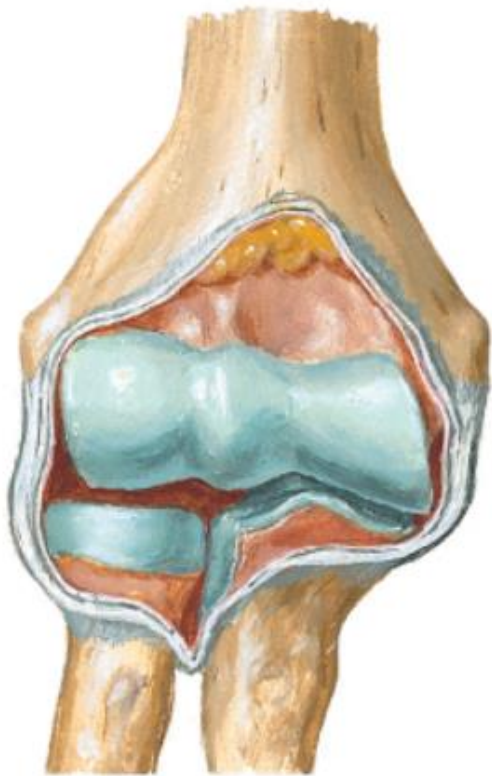LECTURE [11]

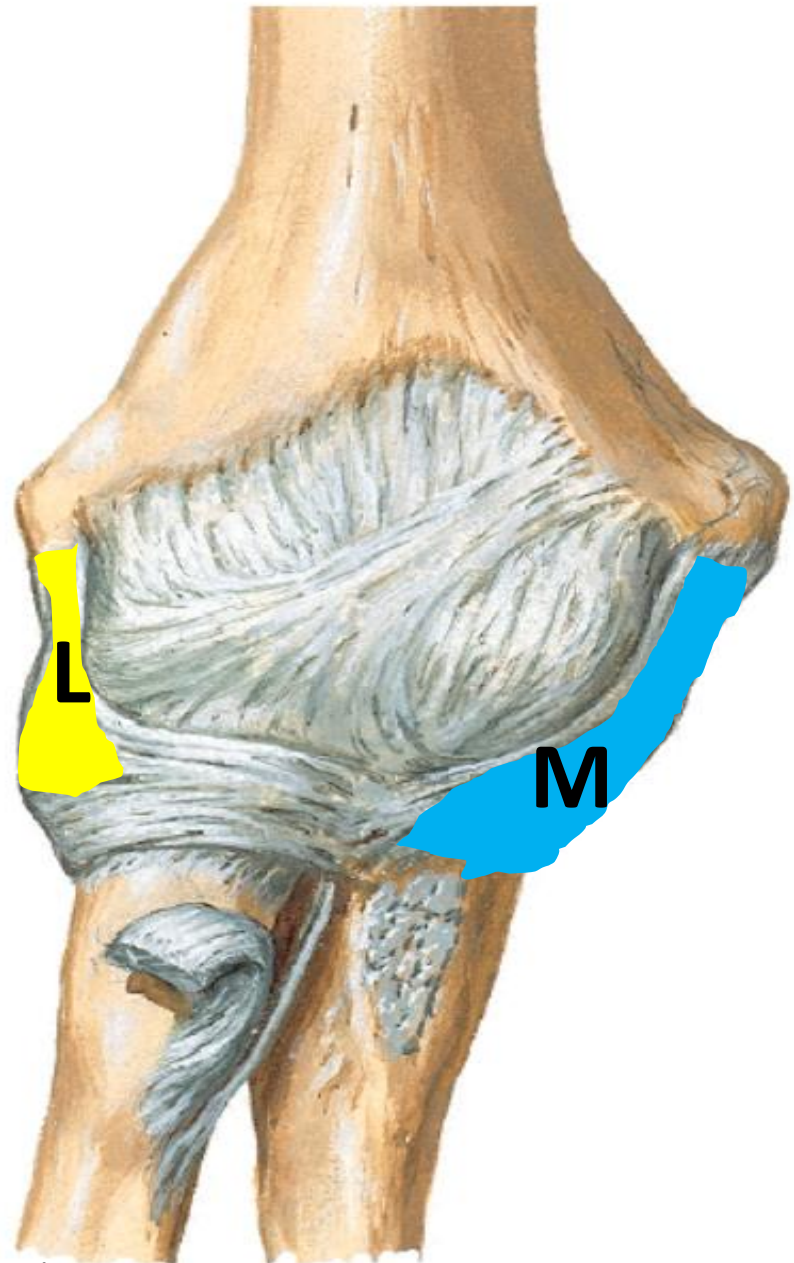
ELBOW JOINT

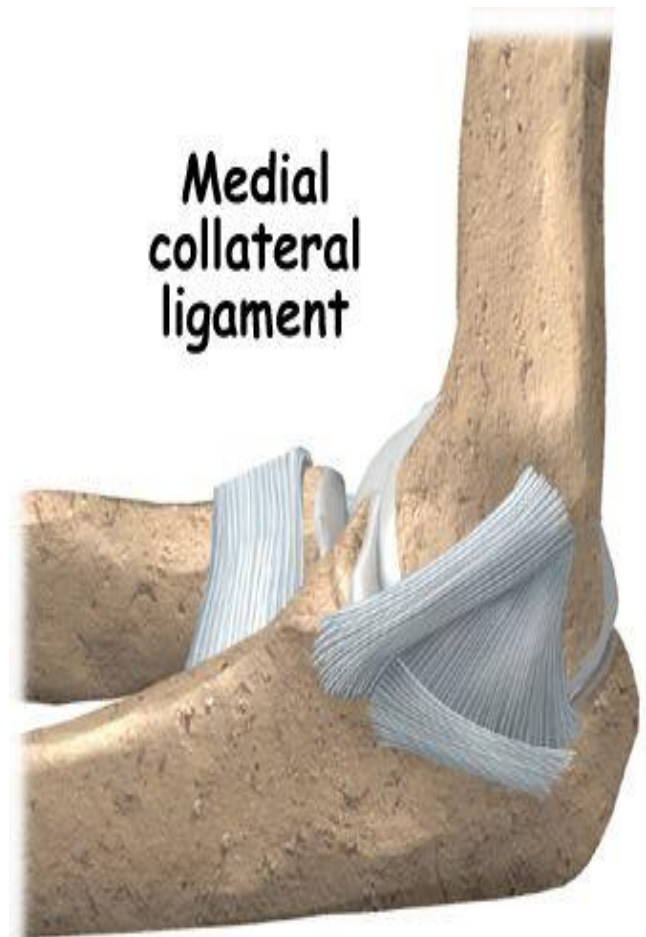
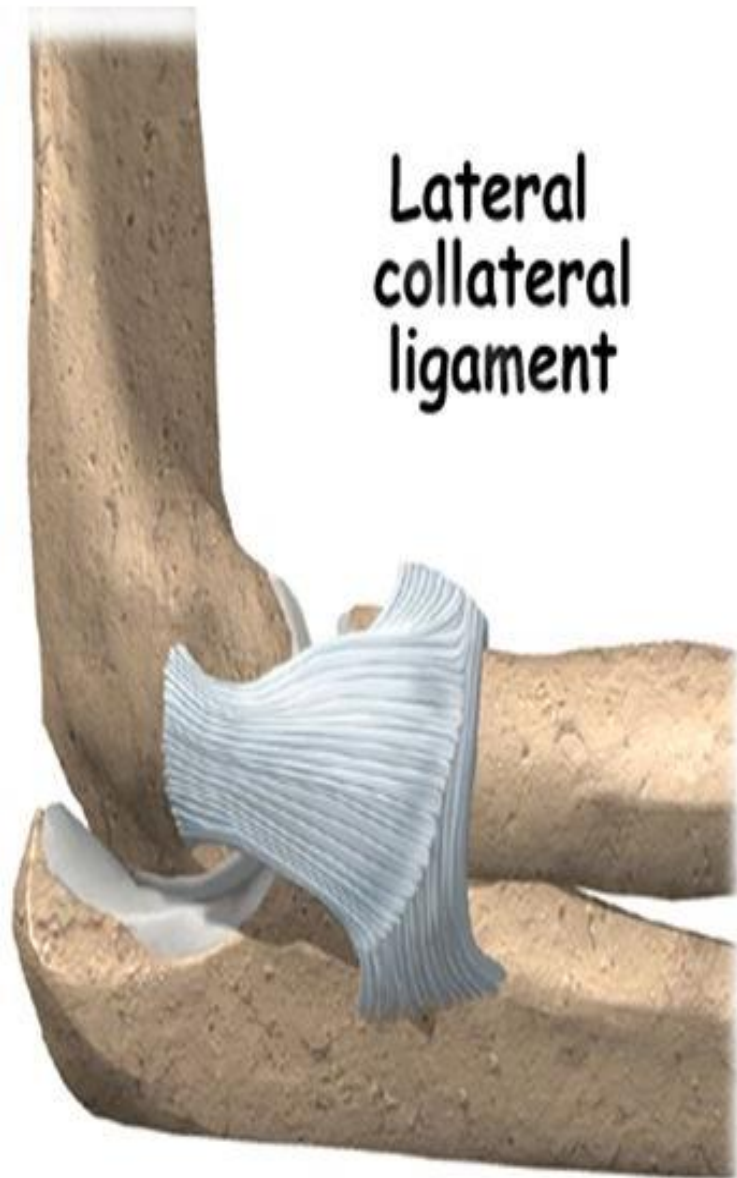






SUPPORTING LIGAMENTS



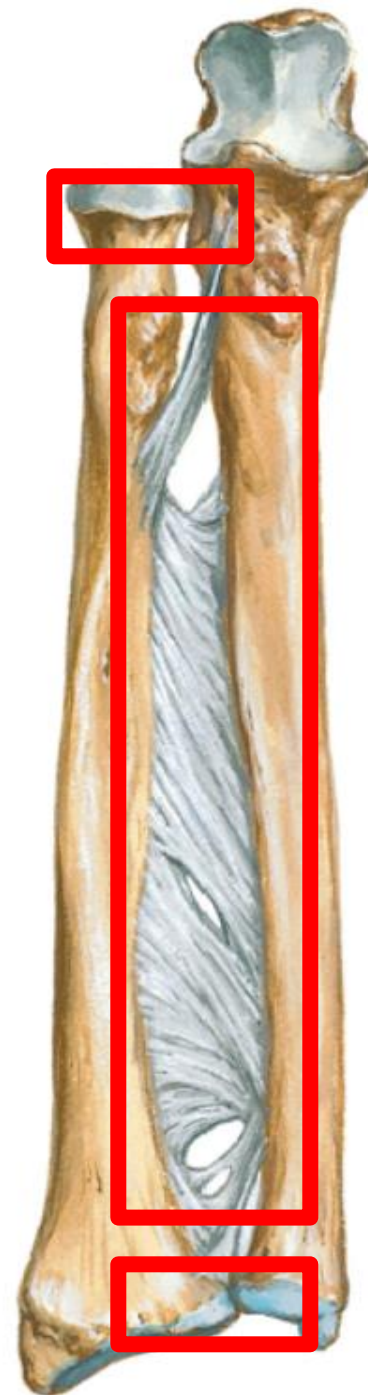

RADIO ULNAR JOINTS

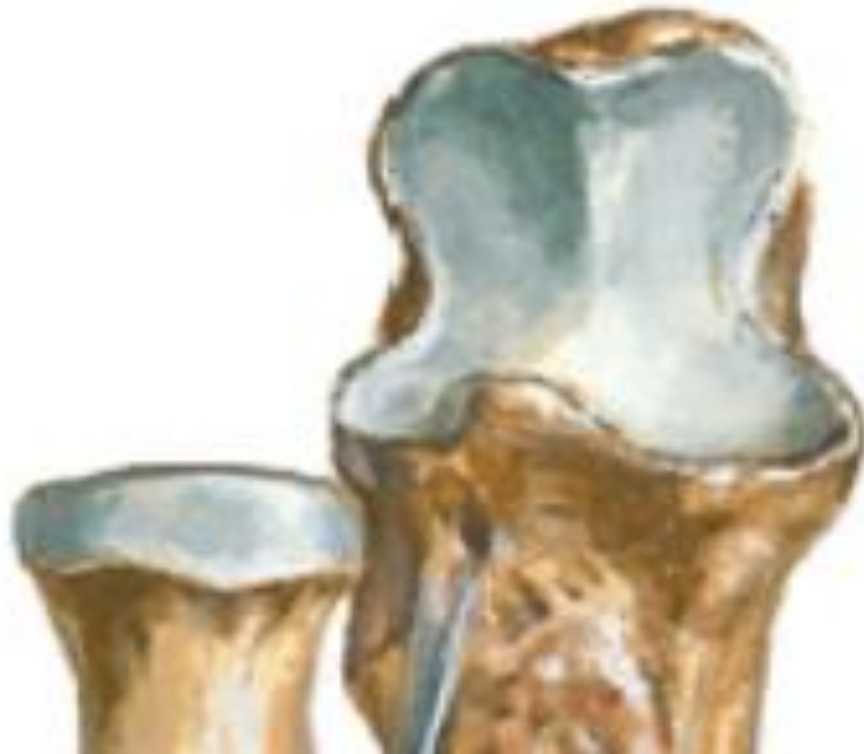Superior

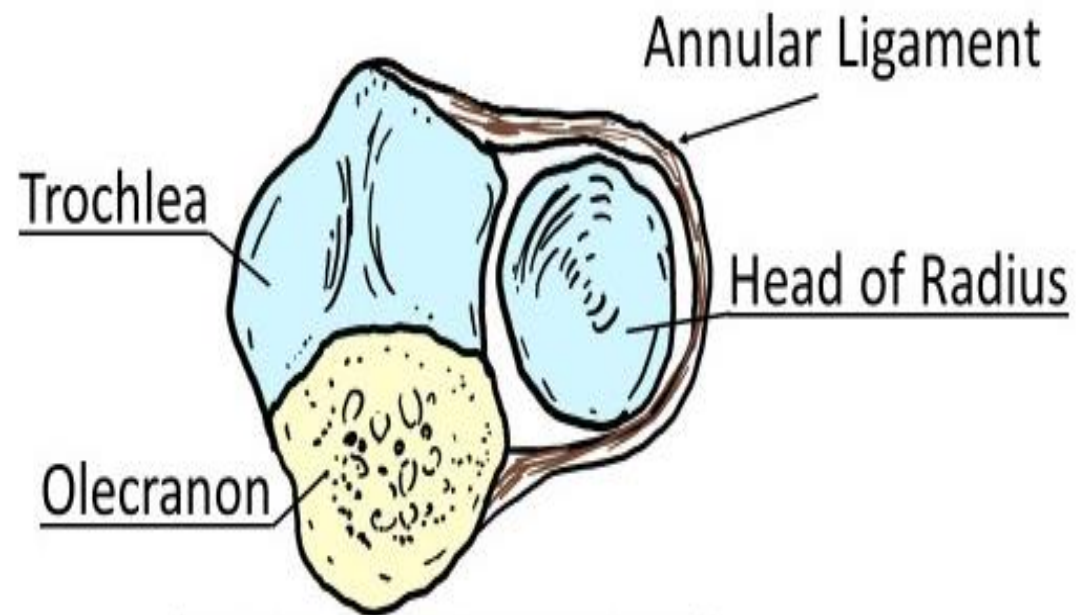
Middle

Inferior

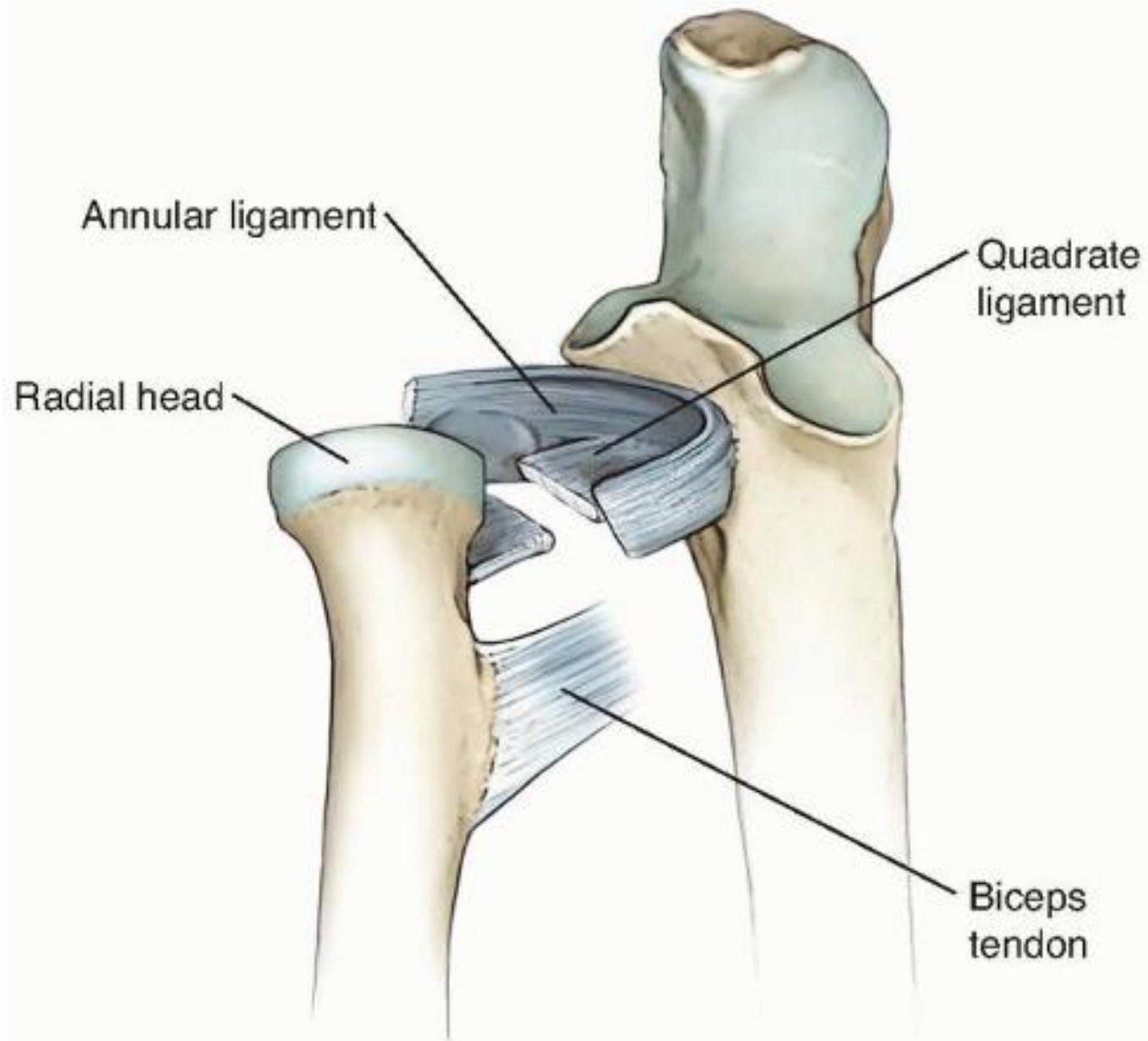


Superior RUJ

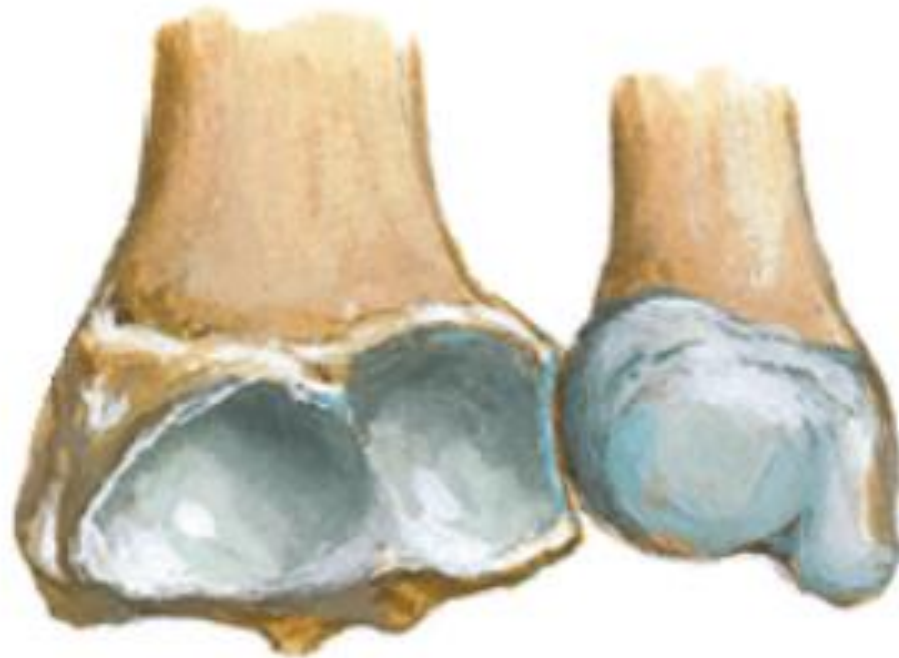



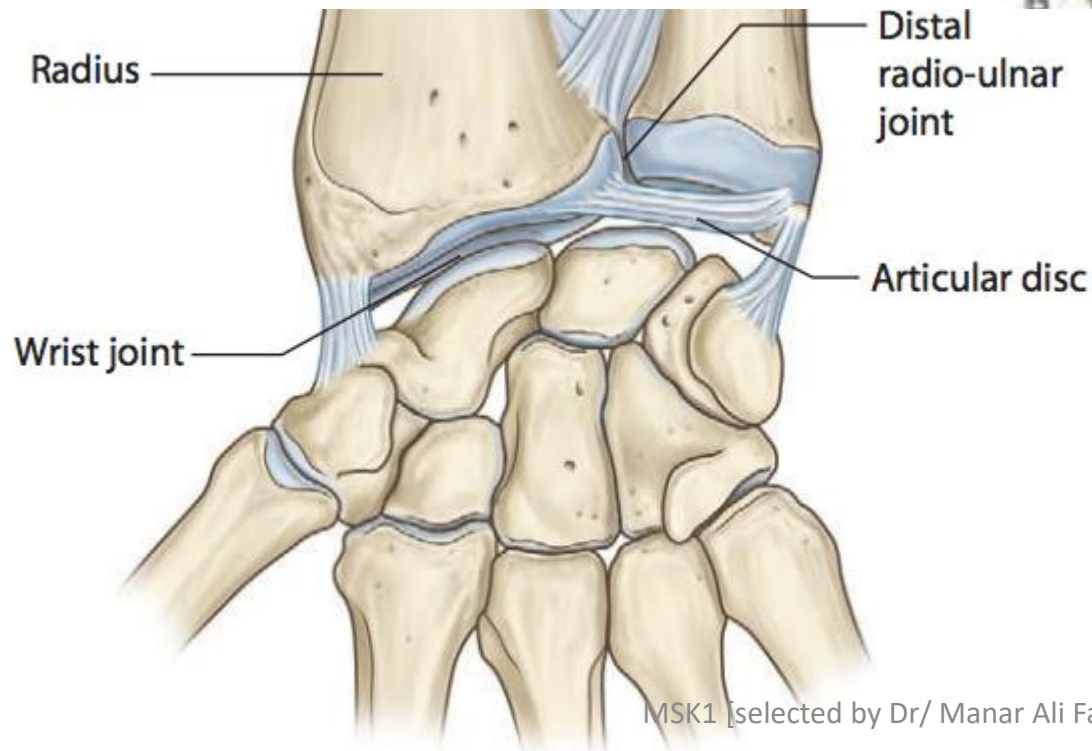
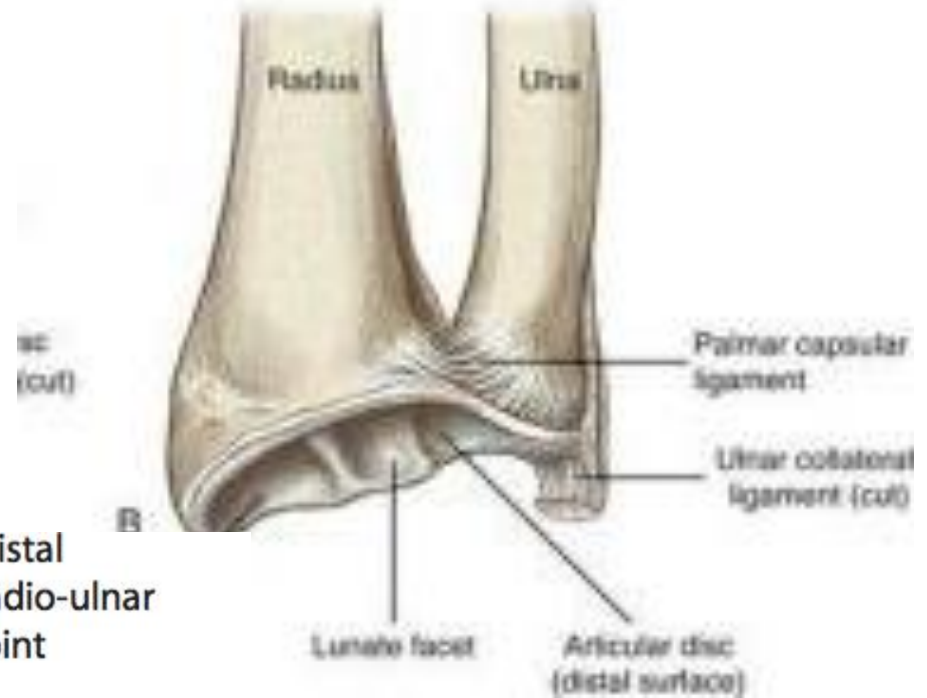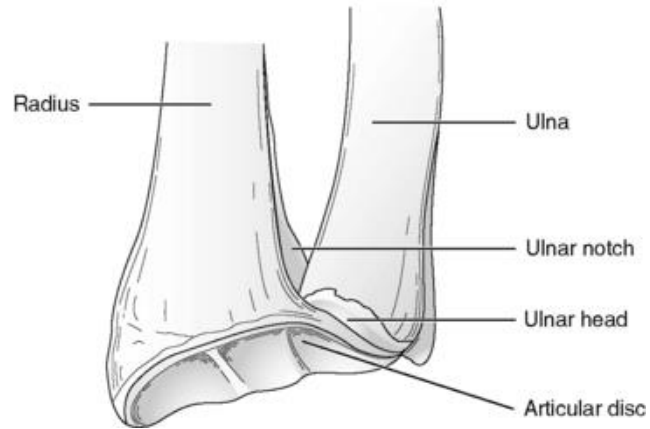
(Superior view of the proximal radioulnar joint)



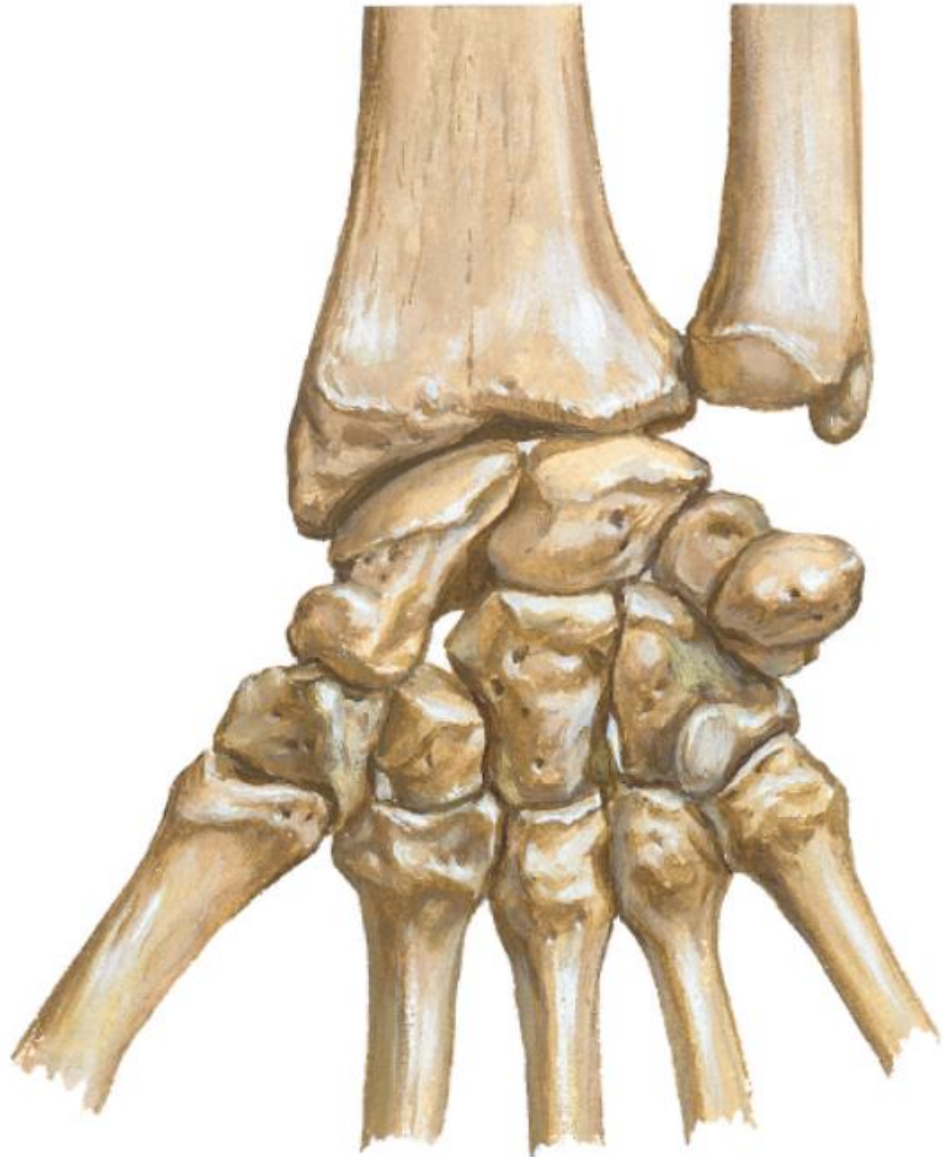
Inferior RUJ

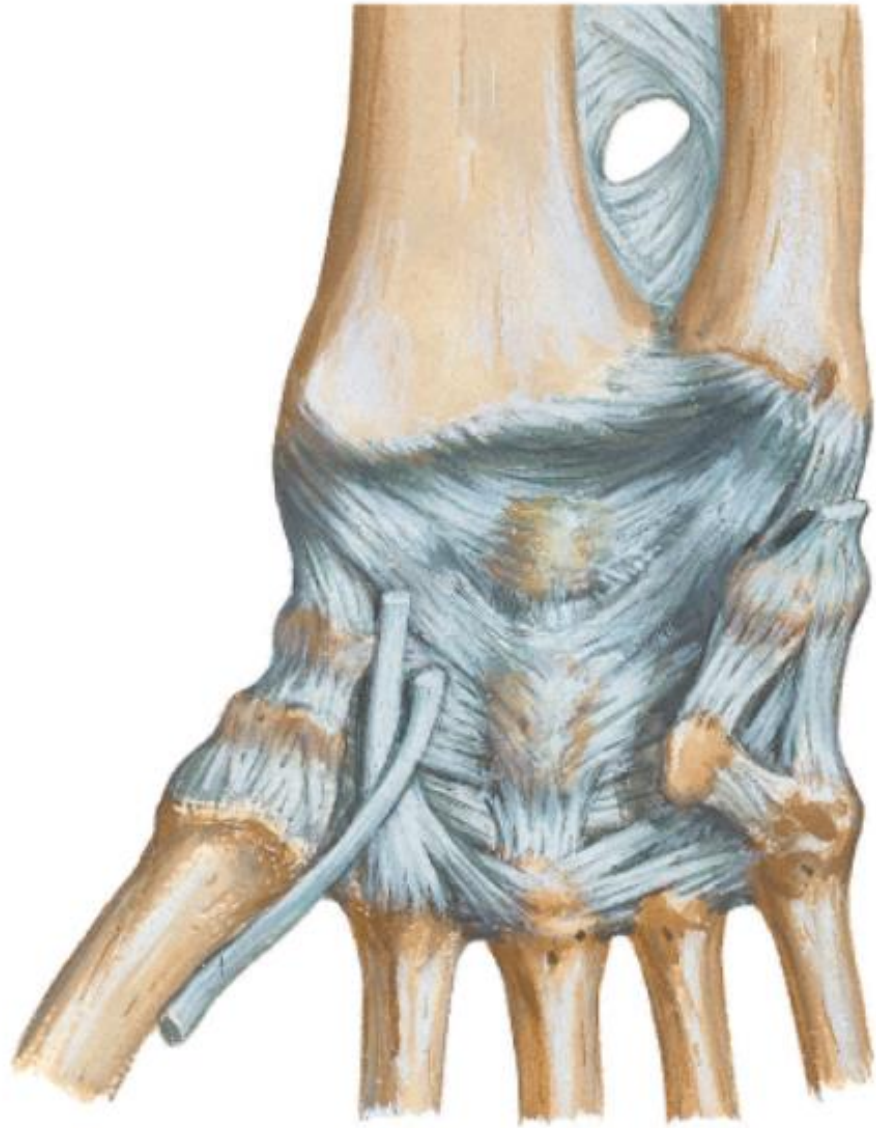


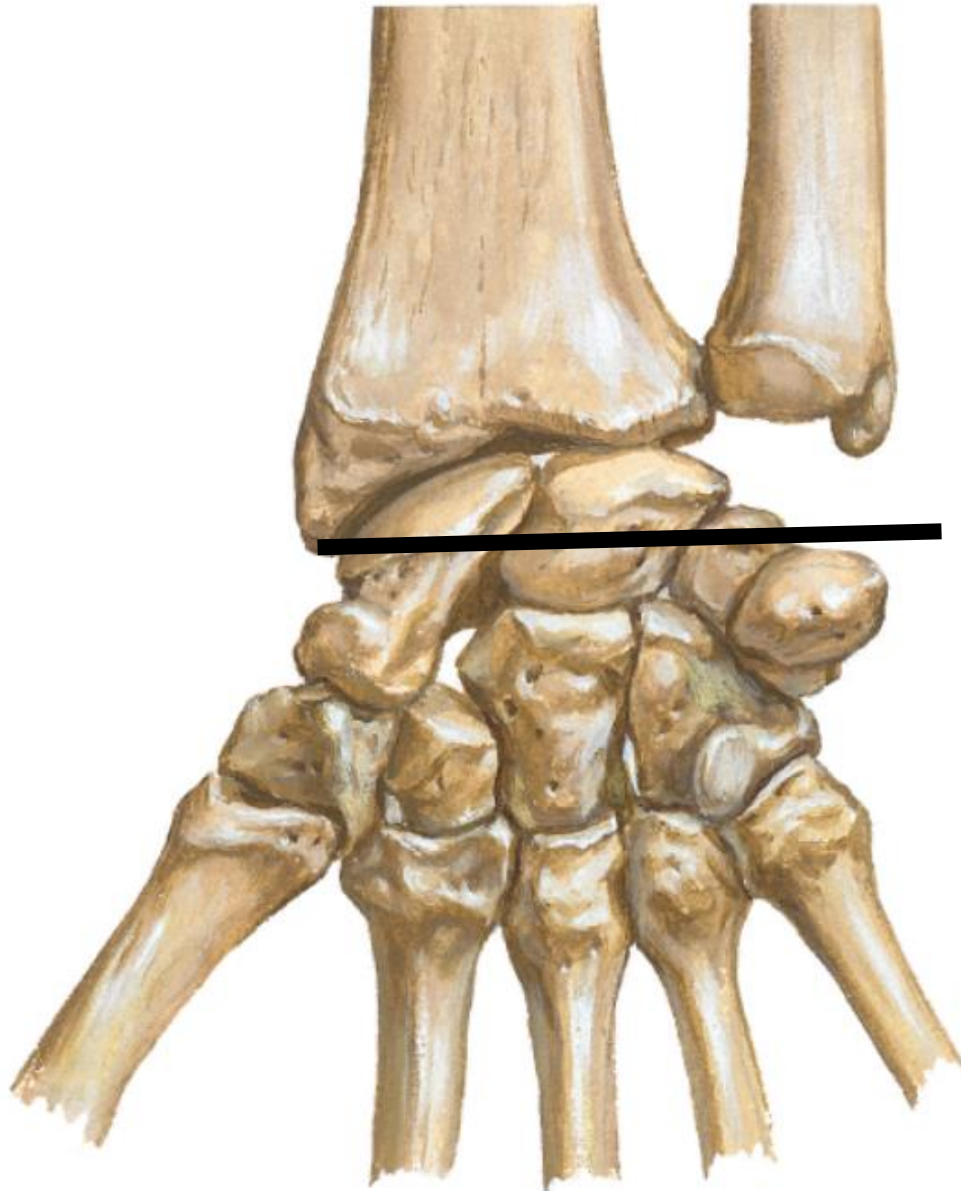
DISTAL RADIOULNAR JOINT



WRIST JOINT

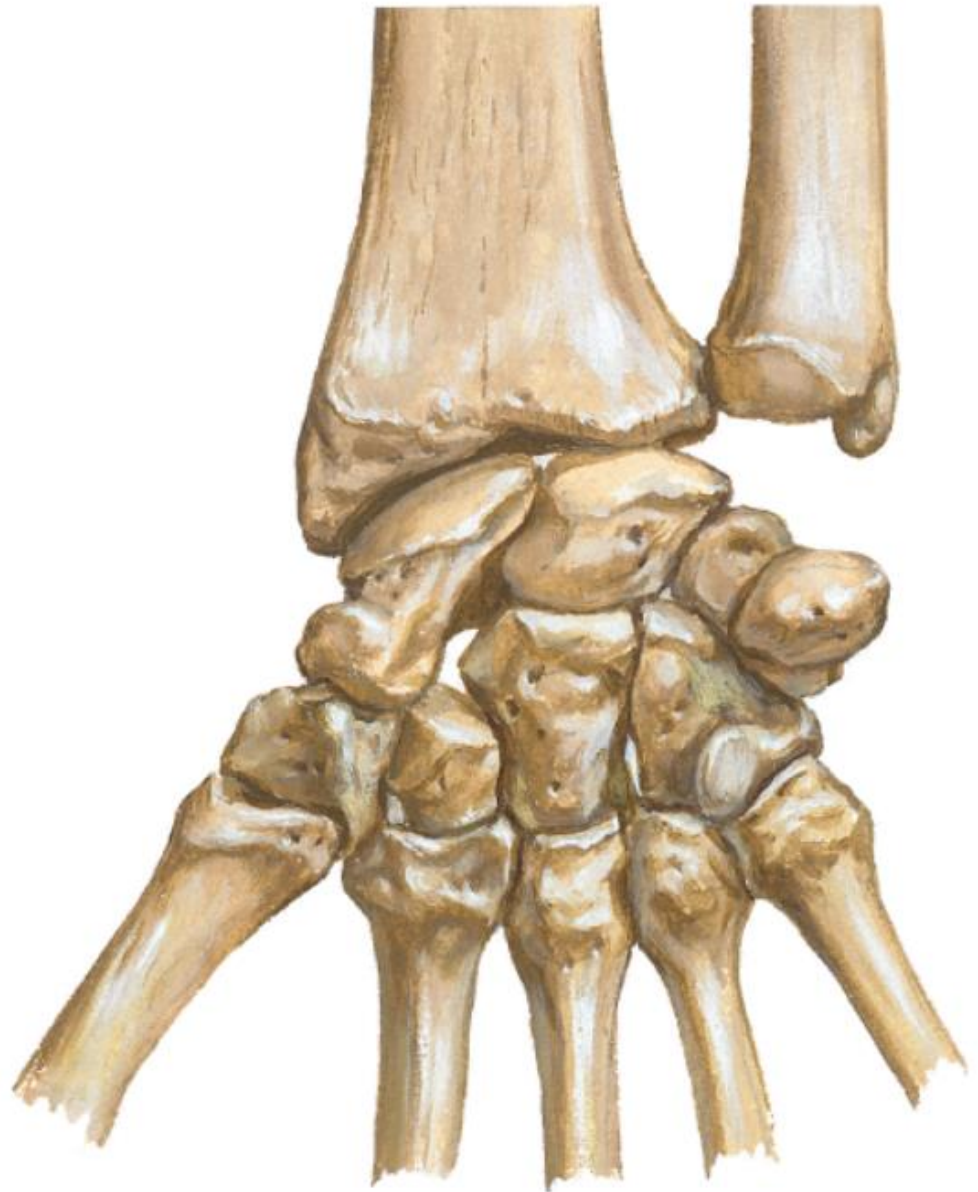




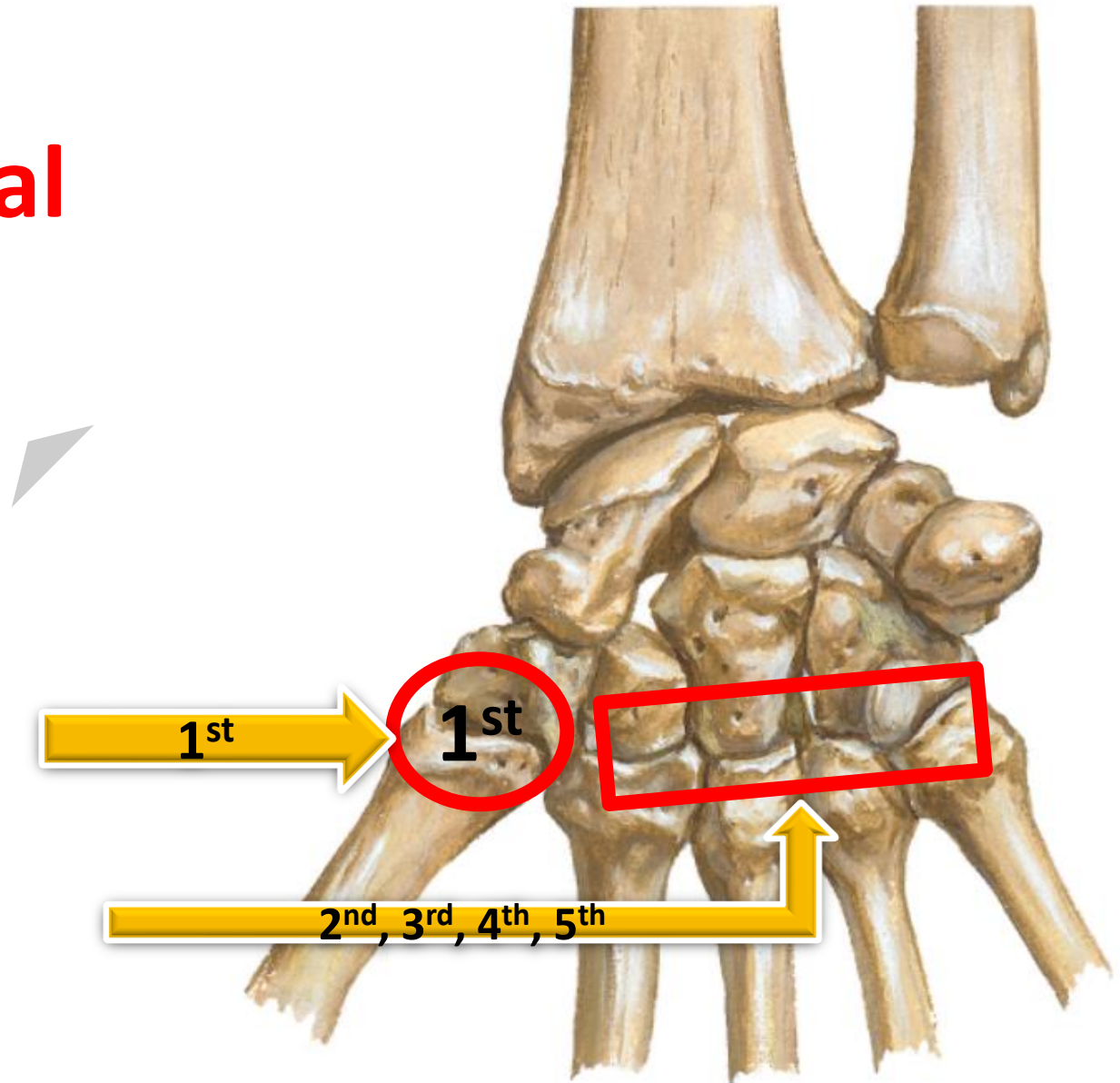


MSK1 [selected by Dr/ Manar Ali Faried]

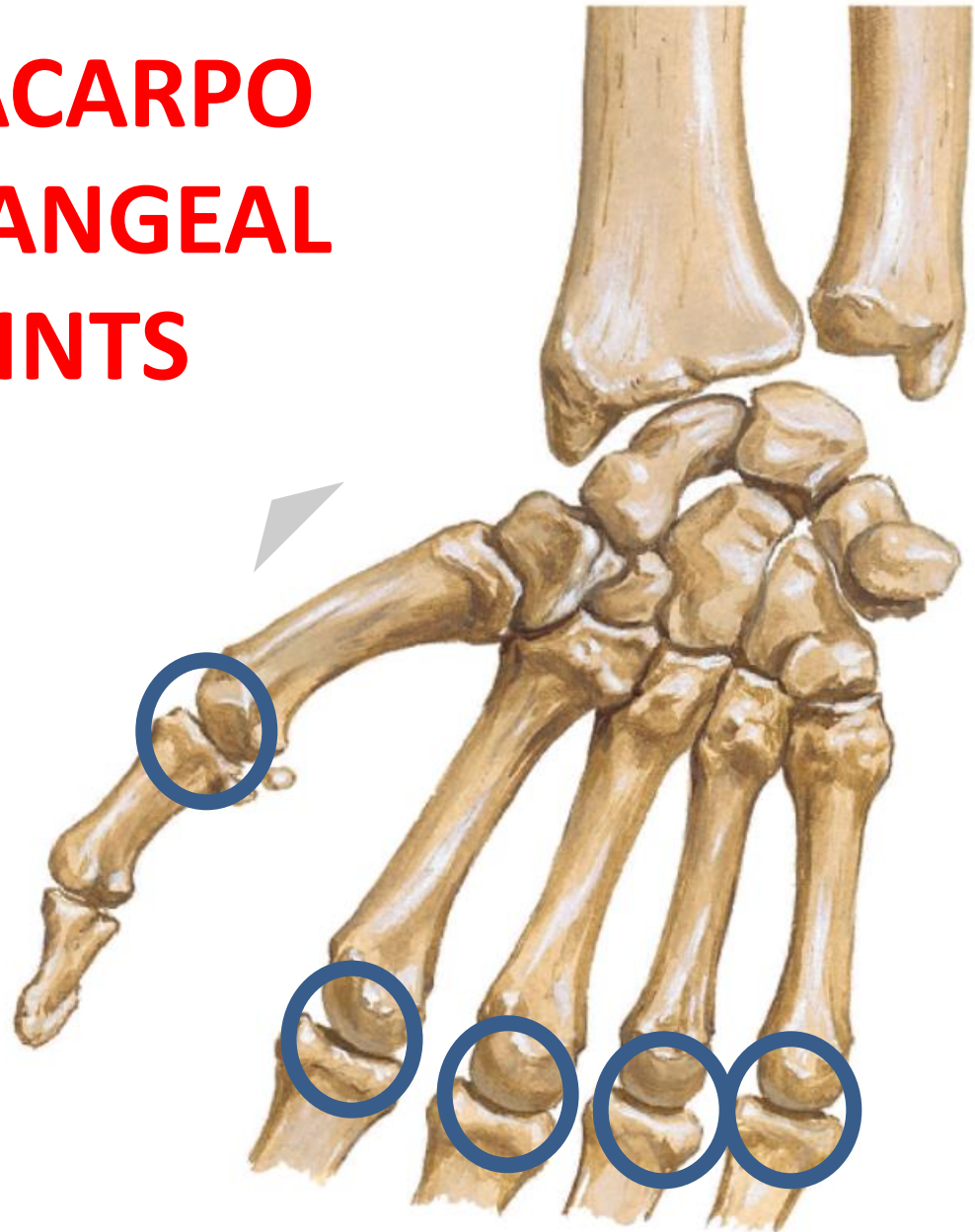
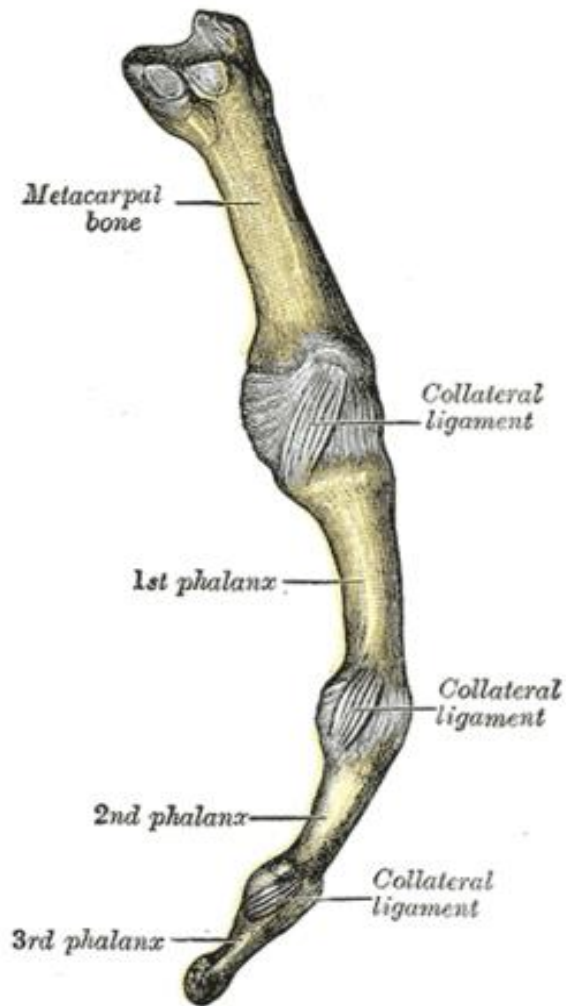
INTERCARPAL JOINTS



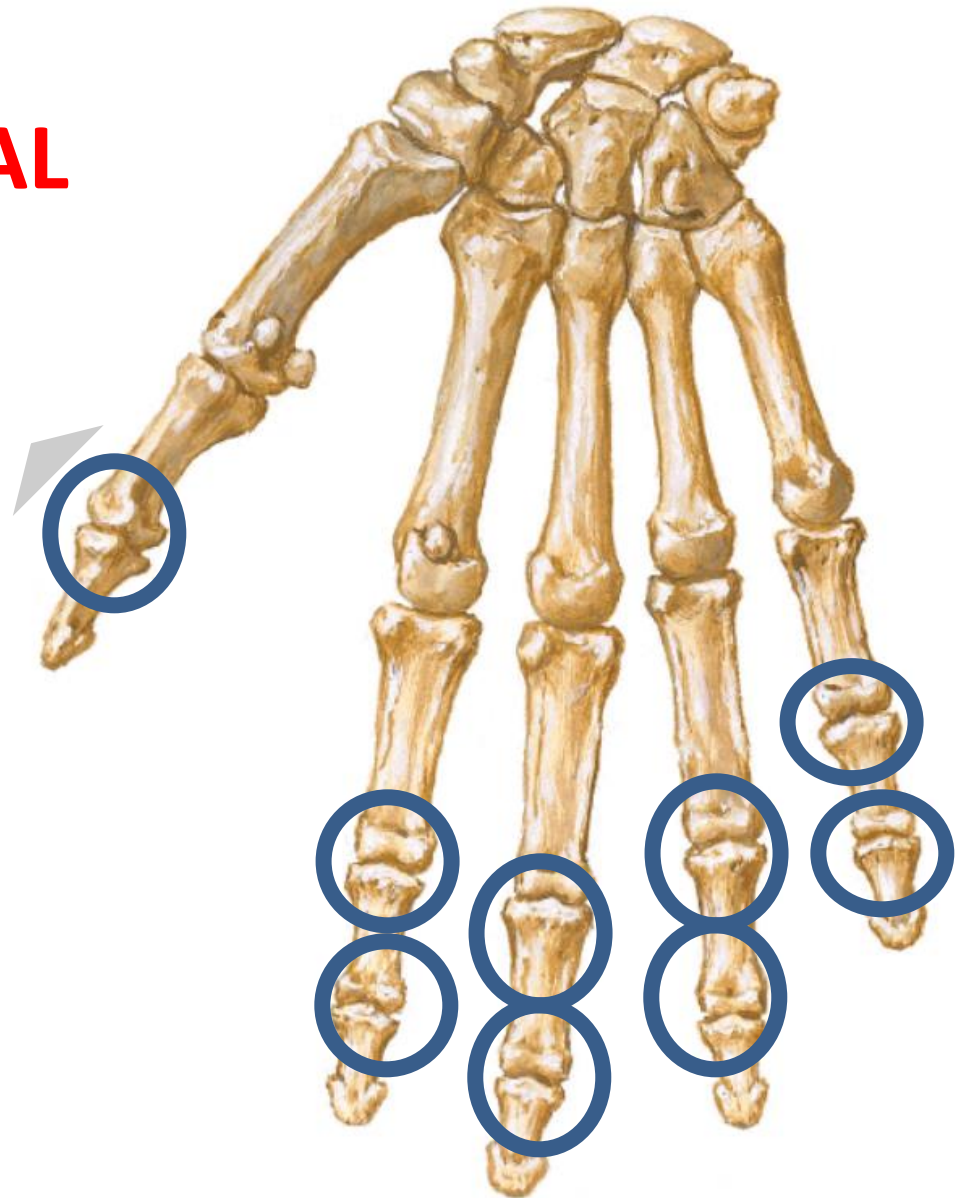
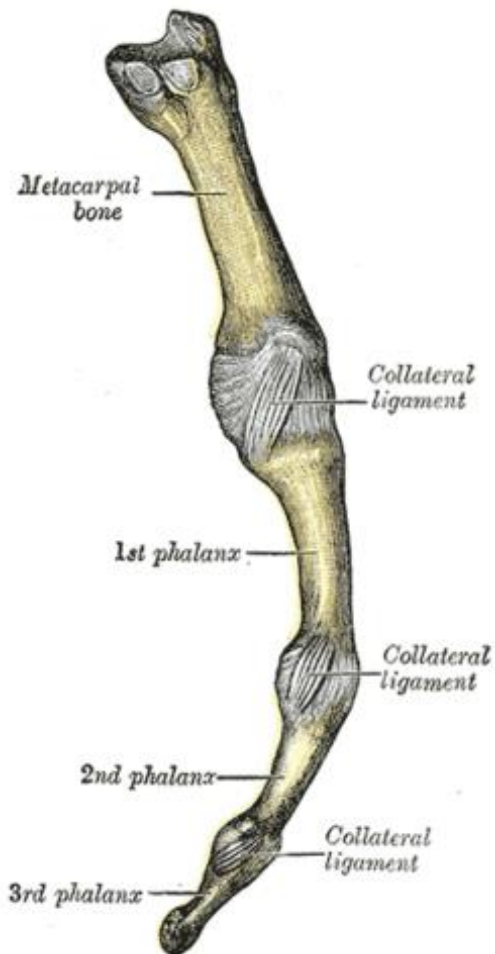
Carpometacarpal JOINTS



METACARPO PHALANGEAL JOINTS



INTER- PHALANGEAL JOINTS



Arteries Of The Upper Limb

